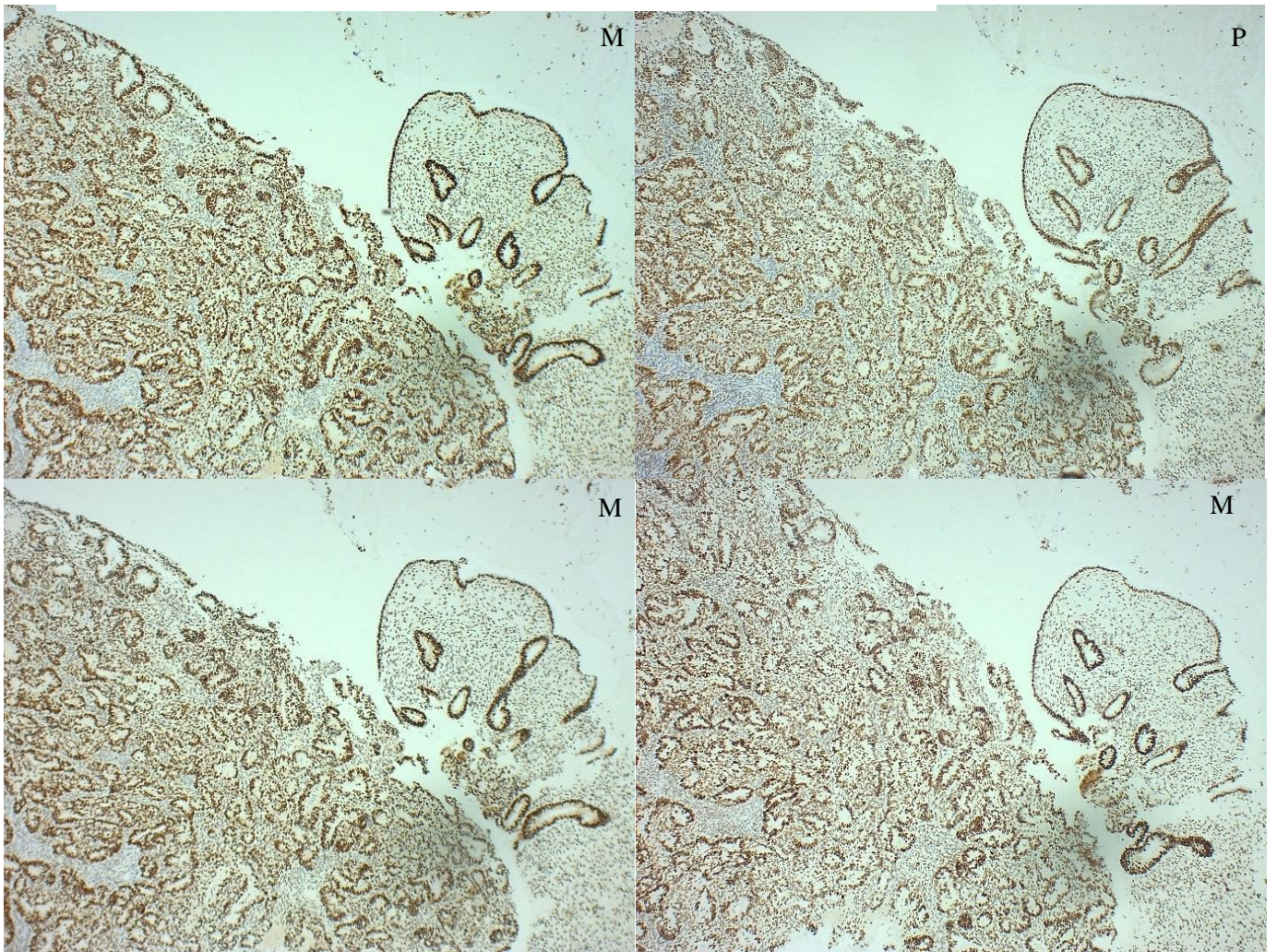
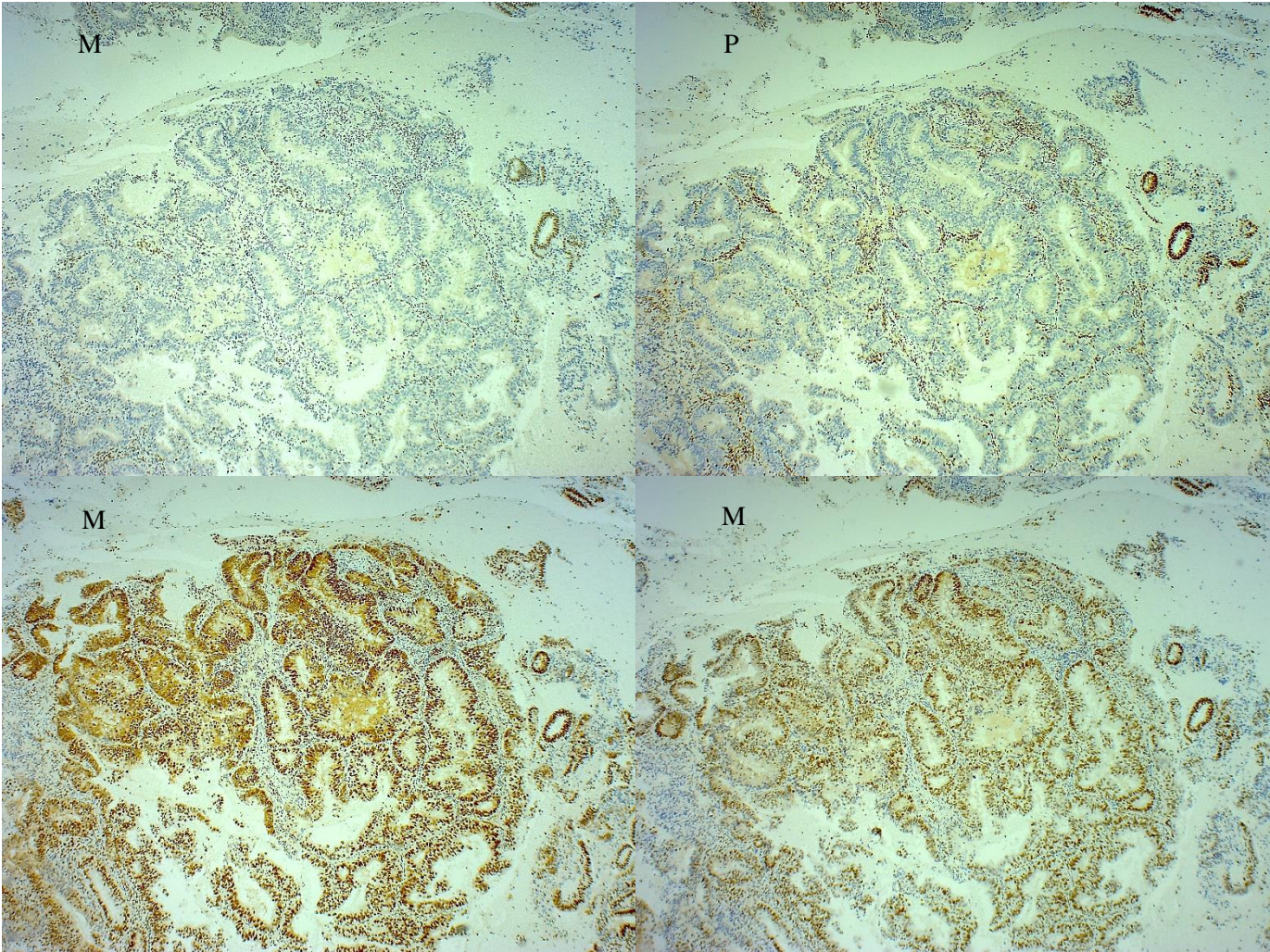


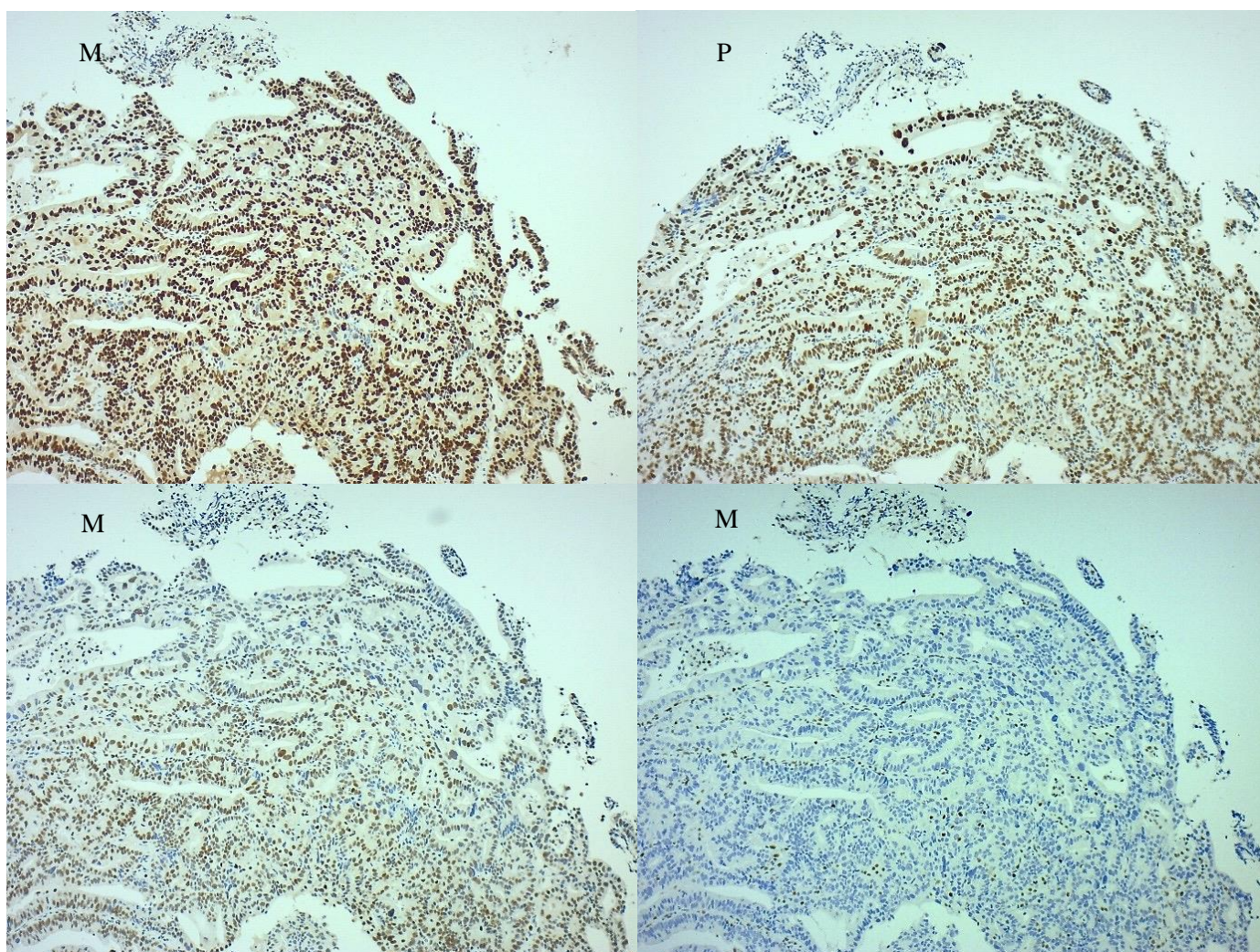
**Appendix 1.** EEC slides representing an MMR proficient tumour.



**Appendix 2.** EEC slides representing a tumour with MLH1-PMS2 IHC loss.



**Appendix 3.** EEC slides representing a tumour with isolated MSH6 IHC loss.



**Appendix 4.** EEC slides representing a tumour with MSH2 loss and weak MSH6.

