

Review

## Role of sentinel lymph node in endometrial cancer: rationale and surgical aspects, a review of the literature

Giuseppe Marino<sup>1,\*</sup>, Tommaso Grassi<sup>1</sup>, Giampaolo Di Martino<sup>1</sup>, Gaetano Trezzi<sup>1</sup>, Marco Adorni<sup>1</sup>, Luca Bazzurini<sup>1</sup>, Fabio Landoni<sup>1</sup>

<sup>1</sup>Clinic of Obstetrics and Gynecology, San Gerardo Hospital, University of Milan-Bicocca, 20126 Monza, Italy

\*Correspondence: [g.marino38@campus.unimib.it](mailto:g.marino38@campus.unimib.it) (Giuseppe Marino)

Academic Editor: Enrique Hernandez

Submitted: 1 November 2021 Revised: 22 November 2021 Accepted: 24 November 2021 Published: 15 February 2022

### Abstract

Endometrial carcinoma is the most common gynecological cancer in Europe, with 130,000 new cases per year, and the incidence has been rising with aging and increased obesity of the population. Most women with endometrial cancer will present with early-stage disease, with a tumor confined to the uterus and without metastasis, and the first approach is surgery. Approximately 10% to 15% of these patients have a metastatic nodal disease, which is why guidelines have always emphasized the importance of lymphadenectomy to stratify the risk and tailor adjuvant treatment. However, comprehensive lymphadenectomy is related to significant morbidity and seems not to improve either progression-free or overall survival in these patients. Lymphatic mapping with sentinel lymph node biopsy has emerged as an alternative and an optimal compromise instead of systematic lymphadenectomy. This review presents the current evidence supporting sentinel lymph node biopsy in patients with endometrial cancer.

**Keywords:** Endometrial cancer; Lymph nodes; Sentinel lymph node; SLN mapping

### 1. Introduction

Endometrial carcinoma is the most common gynecological cancer in Europe [1], accounting for approximately 130,000 newly diagnosed cases in 2020. The incidence has been rising with aging and increased obesity of the population. For this tumor, surgery is the mainstay of treatment [2]. Hysterectomy  $\pm$  bilateral salpingo-oophorectomy (BSO) removes the primary tumor, other than defining histology, grade, depth of myometrial invasion, lymphovascular space invasion (LVSI), and the molecular profile of the disease. Although most women present with early-stage disease with a relatively good prognosis [3], approximately 10% to 15% of these patients will have metastatic nodal disease. Nodal status is one of the main prognostic factors [4]. Therefore pelvic  $\pm$  para-aortic lymphadenectomy has been traditionally considered the gold standard for the lymph node status assessment to tailor adjuvant treatment. However, two randomized trials comparing hysterectomy plus lymph node dissection vs. hysterectomy alone failed to show a survival advantage of nodal dissection [5,6]. The ASTEC (A Study in the Treatment of Endometrial Cancer) trial is a randomized multicentre study of more than 1400 patients, which showed no therapeutic benefit for lymphadenectomy in early-stage endometrial cancer [6]. However, almost half of the patients randomized to the lymph node dissection arm had few nodes removed ( $<10$ ). Additionally, patients were secondary randomized to adjuvant radiotherapy independent of their lymph node status, not taking into account the role of

positive lymph nodes to tailor the post-operative treatment. In another randomized trial by Benedetti-Panici *et al.* [5], no difference was seen in 5-years progression free and overall survival between the group of patients who added lymphadenectomy to standard surgery and the group who did not. In this study, a minimum of 20 lymph nodes removed per patient was required. However, also this trial was hardly criticized because the choice to complete the treatment with adjuvant radiotherapy was at the discretion of the single institution.

Lymphadenectomy is related to relevant morbidities [7], such as lower extremity lymphedema and lymphocysts, which can negatively impact the quality of life of women [8]. It is also associated with longer operating time, prolonged anesthesia, increased blood loss, vascular and nerve injury, and an increased conversion rate from laparoscopy to laparotomy to successfully complete the operation [7]. Consequently, there has been significant controversy concerning the role of lymphadenectomy in endometrial cancer, with recommendations ranging from systematic pelvic and para-aortic lymphadenectomy to no lymph node biopsy at all [9–11].

Recently, lymphatic mapping with sentinel lymph node (SLN) biopsy has emerged as an alternative and an optimal compromise instead of systematic lymphadenectomy [12]. Growing evidence suggests that SLN mapping has high accuracy in detecting nodal disease [13] and may decrease the morbidity associated with lymphadenectomy in patients with endometrial cancer. Both the National Comprehensive Cancer Network (NCCN) [14] and the European



Society of Gynaecological Oncology (ESGO) [15] guidelines have approved the SLN biopsy as a possible alternative to full lymphadenectomy for endometrial cancer staging procedures.

This review aims to present the current evidence that supports SLN biopsy in patients with endometrial cancer.

## 2. Sentinel lymph node (SLN) in endometrial cancer

Traditionally, the SLN is considered the first lymph node receiving lymphatic drainage from the tumor. Therefore, the first node: (i) that would be interested in lymphatic dissemination of the disease, and (ii) that if it is negative for disease, then the following nodes will also be negative. Two main parameters should be considered to measure these concepts: sensitivity and negative predictive value (NPV). Sensitivity expresses the proportion of patients with a node-positive disease who had a metastatic disease successfully identified in the SLN. While the negative predictive value describes the proportion of patients with negative SLN associated with a truly node-negative disease (negative non-sentinel lymph nodes). An ideal SLN technique requires high sensitivity, high NPV, and, for endometrial cancer, high bilateral mapping.

SLN technique was firstly established in the treatment of solid cancers, such as melanoma [16] and breast cancer [17], while, in endometrial cancer, it was first described in 1996 [18]. A consensus among international endometrial cancer experts recently defined the SLN as “the most proximal node irrespective of the nodal station in which the node is found” [19].

The Memorial Sloan-Kettering Cancer Center (MSKCC) group was one of the leading promoters of this technique. They designed a specific algorithm (Fig. 1) that includes: (i) peritoneal and serosal evaluation and washings; (ii) retroperitoneal evaluation, including the removal of all SLNs and any suspicious nodes, regardless of mapping; (iii) side-specific pelvic lymphadenectomy if there is no mapping on a hemipelvis; (iv) para-aortic lymphadenectomy is left to the attending discretion. The MSKCC SLN algorithm should be followed in every case to avoid false-negative cases [20]. The NCCN describes the adherence to this algorithm as the “key point for a successful SLN mapping” [14].

### 2.1 SLN in endometrial cancer: the rationale

#### 2.1.1 SLN detection rate, sensitivity, and negative predictive value in endometrial cancer

The FIRES trial, a large prospective, multicentre study, investigated the NPV and sensitivity of SLN in patients with clinical stage I endometrial cancer undergoing robotic staging with SLN biopsy followed by completion bilateral lymphadenectomy [21]. At least one SLN was detected in 86% of patients, while bilateral detection was achieved in only 52% of patients. However, the SLN al-

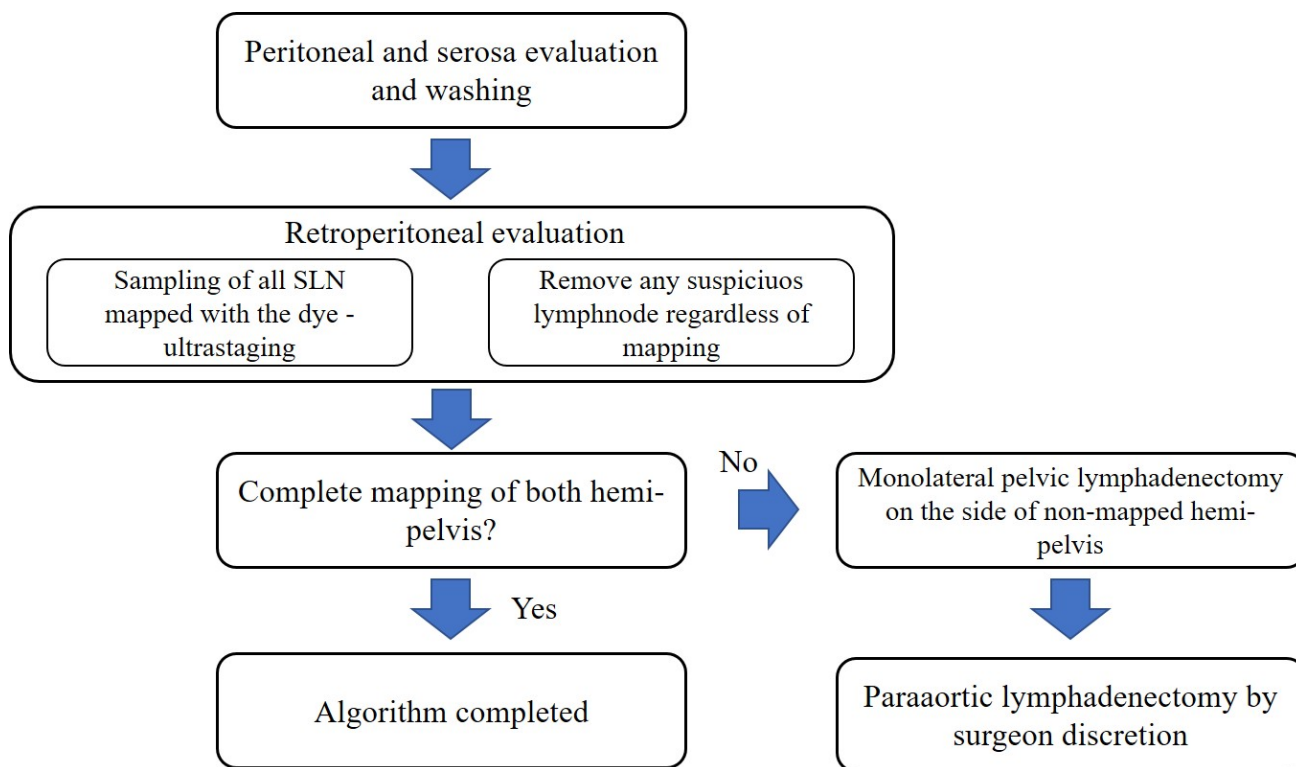
gorithm showed a NPV of 99.6% (95% Confidential Interval (CI), 97.9–100%) and a sensitivity of 97% (95% CI, 85–100%). Similar data were shown in another prospective cohort study and a recent meta-analysis [22,23]. A more satisfying detection rate was shown in a more recent international, multicenter, randomized, phase 3 study (the FILM trial) [24]. When an expert surgeon was using a cervical injection of indocyanine green (ICG), at least one SLN was detected in 95% of women with endometrial and cervical cancers, while bilateral detection was achieved in 78% of women. However, the majority of cases included in these studies were low-risk endometrial cancers. Recently, some studies investigated the diagnostic accuracy of SLN (followed by completion pelvic + para-aortic lymphadenectomy) in high-risk endometrial cancers [25–28]. The SHREC trial [25], a prospective non randomized study, showed a sensitivity of 98% (95% CI 89–100%), NPV of 99.5% (95% CI 97–100%), with a bilateral mapping of 95%, using the MSKCC SLN algorithm [20]. Similar results were shown by 97.4% detection rate per patient (proportion of patients in whom a sentinel lymph node mapped) and by 99% NPV of the SLN algorithm in the SENTOR trial [26]. These results suggest that SLN algorithm may replace lymphadenectomy also in high-risk endometrial cancer avoiding para-aortic dissection.

#### 2.1.2 Oncologic outcomes of SLN

The impact of the SLN technique on oncologic outcome has been mainly described in retrospective series [29–35]. This series suggests that, using the SLN algorithm [20], oncologic outcomes will not be affected [29–36]. However, prospective data are still lacking.

In low-risk endometrial cancers, several studies show that lymph node evaluation may be avoided in selected patients, due to their excellent prognosis and low risk of lymphatic spread [27,37]. In fact, SLN does not seem to impact the prognosis in this group of women [32,36,38]. In a retrospective series of 1135 patients with endometrioid endometrial cancer and myometrial invasion <50%, disease-free survival (DFS) and overall survival (OS) were compared patients who underwent a complete pelvic and para-aortic LND at the Mayo Clinic vs. the SLN biopsy at the MSKCC [32]. In both the approaches, a low rate of lymph node positive disease was detected (2.6% (95% CI, 1.2–4.1%)) vs. 5.1% (95% CI, 3.4–6.9%) in the lymphadenectomy group vs. the SLN group, respectively. Between the two groups, both DFS and OS did not differ, with a 3-year DFS rate of approximately 95%; a 3-year OS of approximately 96% and a 3-year disease-specific survival of approximately 100%.

A few retrospective studies described the impact of SLN on oncologic outcomes in intermediate- and high-risk endometrial cancers [30–35]. Another retrospective series by MSKCC and Mayo Clinic compared progression-free survival (PFS) and OS in 176 patients with endometrioid endometrial cancers and myometrial invasion ≥50% [33].



**Fig. 1. Memorial Sloan Kettering Cancer Center (MSKCC) sentinel lymph node mapping algorithm widely used to reduce the false-negative rate of the procedure.**

The 3-year PFS was not significantly different between the two approaches (78.7% (95% CI, 69.6–89.1%) in the SLN group vs. 77.7% (95% CI, 68.6–87.9%) in the LND cohort). In the lymphadenectomy cohort, a node-positive disease was diagnosed in 28% of cases, while in 35.4% of cases in the SLN cohort. Same survival results were found in a retrospective series of patients with high-risk and non-endometrioid endometrial cancers [30,34,35,39,40]. Actually, some prospective studies are ongoing to evaluate the oncologic outcomes in patients undergoing SLN biopsy [41].

The American and European guidelines accepted SLN as a standard thanks to the retrospective and prospective papers presented in paragraphs 2.1.1 and 2.1.2 [14,15]. Additionally, the SLN level of evidence in intermediate-high risk tumors was upgraded from level IV to level III, B in the last edition of ESGO guidelines [15] compared to the previous one [42].

### 2.1.3 New challenges: the role of Low-volume Metastases (LVM) in endometrial cancer

The SLN biopsy is changing the endometrial cancer approach from an intensive surgical staging (lymphadenectomy) to an intensive pathological staging (ultra-staging, see the paragraph below). The use of an ultra-staging protocol to analyse the SLNs has led to increased detection of low-volume lymph node metastasis, that would not be detectable via conventional examinations [43,44]. According

to the classification of the American Joint Committee on Cancer (AJCC) for breast cancer and also valid for others solid tumors (i.e., endometrial cancer), lymph node metastases are classified as: (i) macrometastasis, if the size of the metastasis is larger than 2 mm; (ii) micrometastases, when the size of the metastasis is measuring more than 0.2 to less or equal to 2 mm; isolated tumor cells (ITCs), if the microscopic clusters and single neoplastic cells are measuring less or equal to 0.2 mm [45]. However, while patients with macrometastases have a worse prognosis, the prognostic value and therapeutic implications related to the detection of low-volume disease in the SLN is still controversial. A few papers studied this issue. The presence of low volume lymphatic disease ranges from 25% to 62% across different studies [32,33,46–48]. Todo *et al.* [49] found that the presence of LVM is an independent risk factor for extra-pelvic recurrence in a population of 62 patients with intermediate risk endometrial cancer patients (only 9 with LVM: 3 micrometastasis and 6 ITC). The intermediate risk was defined as the presence of at least one of the following factors: (i) deep myometrial invasion; (ii) grade 3 endometrioid or non-endometrioid histology; (iii) cervical involvement; (iv) LVSI; and (v) positive peritoneal cytology. The presence of LVM was associated only with a higher rate of deep myometrial invasion compared to the node-negative group (88.9% vs. 46.2%). In 4 cases on 9 they had a relapse of the disease (all of them extra-pelvic), although 8 of the 9 patients received

adjuvant chemotherapy or radiotherapy. In a multivariate analysis of risk factors for recurrence, they found that LVM was not a risk factor for recurrence, but it was an independent risk factor for extra-pelvic recurrence. The conclusions of this study are limited due to the small sample size. The MSKCC group [50] described a series of 44 patients with LVM in a group of 844 patients with endometrial cancer treated between 2005 and 2013 at their institution. Only 4% of patients with ITC did not receive adjuvant treatment, 87% received chemotherapy  $\pm$  external beam radiotherapy or vaginal brachytherapy, and 9% received radiation treatment alone. In the micrometastasis group, 81% received chemotherapy  $\pm$  radiation therapy, 5% received radiation treatment alone and 14% of patients did not receive adjuvant treatment. The rate of relapse was 8.7% (2/23) in ITCs group, 9.5% (2/21) in the micrometastases group, while 6.2% (47/753) in the node negative group, and 34.8% (16/46) in the nodal macrometastases group. For ITCs, 1 recurrence was local and the other one distant. While for micrometastases, 1 recurrence was nodal and one distant. In another study by Plante *et al.* [51], 519 patients with endometrial cancer treated between 2010 and 2015 at L'Hotel-Dieu de Quebec Hospital were included in the study. Of the patients included 43 (51%) had macrometastasis, 11 (13%) micrometastasis and 31 (36%) ITC. In ITC group, 35% received adjuvant chemotherapy  $\pm$  radiation, 32% received radiation alone and 32% received no adjuvant treatment or vaginal brachytherapy (VBT) alone. For the micrometastases group, 73% of patients received adjuvant chemotherapy  $\pm$  radiation, 55% received adjuvant radiation  $\pm$  chemotherapy, and 46% received vaginal brachytherapy  $\pm$  chemotherapy  $\pm$  radiation. With a median follow-up of 29 months, they observed a 3-years PFS of 95.5% in the ITC group, 87.6% in the node negative group, 85.5% in the micrometastasis group and 58.5% in the macrometastasis group. In the ITC group, only 1 patient with a carcinosarcoma who received adjuvant treatment relapsed. While no relapse was observed in the 28 patients with ITCs and endometrioid histology and in the 10 patients with ITC who did not receive adjuvant treatment. Actually, the authors suggest that in patients with ITC, the choice of an adjuvant treatment should not be based on the nodal status only, but uterine risk factors should be considered.

A recent international multicenter retrospective study enrolled 247 patients with low volume nodal disease (132 ITCs and 115 micrometastasis). They included patients who underwent surgery with SLN biopsy between 2009 and 2020 and excluded all patients with adnexal involvement or FIGO stage IV disease or synchronous neoplasia or neoadjuvant treatment. Of the patients included, 57% (140 patients) underwent SLN biopsy alone, while the others received SLN biopsy and pelvic and/or paraaortic lymphadenectomy. In the micrometastasis group, 93% of patients underwent an adjuvant treatment (chemotherapy and/or external beam radiation), while 63% in the ITC

group. Among all patients included in the study, they found 38 relapses (21 and 17, in the micrometastasis and ITC groups, respectively), and 15 patients died (11 died of disease). The 2-year recurrence free survival was 84.5% (95% CI, 79.7–89.6%), while the 4-year recurrence-free survival was 77.6% (95% CI, 70.2–85.9%). Most recurrences were distant. The predictors of recurrence were grade 3 disease, non-endometrioid histology, LVSI, and uterine serosal involvement. On multivariate analysis only the last three factors were predictive of recurrence. Considering the endometrioid histology only (212 patients), they found a 4-year recurrence-free survival of 81.8% (95% CI, 73.6–91.0%). In this group of patients, the predictors of recurrence were grade, LVSI, and uterine serosal involvement. On multivariate analysis, only the last two factors were independent predictors of recurrence. Interestingly, in 32 patients with grade 1 endometrioid endometrial cancer with ITC and no risk factors (LVSI or serosal involvement), only one patient had a recurrence. The authors conclude that this group of patients may have a good prognosis even without adjuvant therapy [52].

It is important to stress that literature data are lacking on this topic. For what we know, we believe that micrometastasis should be considered as node positive disease; while for ITC, the uterine factors should also be considered to tailor a possible post-operative treatment.

## 2.2 SLN in endometrial cancer: technical aspects

### 2.2.1 SLN dye

Historically, patent blue dye  $\pm$  radiocolloid has been the most commonly used agent for lymphatic mapping in women with uterine cancers. However, blue dye alone identifies at least one sentinel node in only 80% of patients and bilateral sentinel nodes in approximately 50% of patients [23]. Combining blue dye with radiotracer increases the rate of detection of at least one sentinel node to 88%, but the rate of detection of bilateral sentinel nodes to only 51%.

The fluorescent dye indocyanine green (ICG) has been explored in many studies as an alternative to blue dye for lymphatic mapping in endometrial cancer [53–55], showing better results than the other agents. The best evidence to support the role of ICG to detect SNL is the FILM trial [24]. This international, multicentre, open-label, phase III clinical trial was designed to assess the safety and efficacy of ICG in the identification of lymph nodes in women with clinical stage I endometrial or cervical cancer undergoing SLN mapping. The trial randomly assigned 1:1 to lymphatic mapping with isosulfan blue dye followed by ICG, or ICG followed by isosulfan blue (ISB) dye. Although the study was designed as a non-inferiority trial, the findings suggested that ICG was superior to ISB in detecting at least one SLN and in the bilateral SLN mapping. This trial allowed the FDA approval of ICG for these patients. Similar results were found in another randomized clinical trial com-

paring ICG and ISB [56] and in a prospective collection by Backes *et al.* [57].

### 2.2.2 Site of injection

Three different types of injection have been described for the SLN mapping: (1) uterine subserosal, (2) cervical, and (3) via hysteroscopy [58,59].

The cervical injection is the preferred method, for many reasons: the primary lymphatic drainage of the uterus is from the parametria; the cervix is easily accessible, and in women with endometrial cancer is rarely scarred from prior procedures, such as conization or bulky tumor infiltration; additionally, a uterine fundal serosa mapping does not reflect the parametrial lymphatic drainage of the uterus [60]. The main argument against cervical injection is that it has a lower para-aortic detection rate than the hysteroscopic approach. However, when the pelvic lymph nodes are negative for metastasis, the disease is unlikely to be found in the para-aortic nodes [61]. Additionally, cervical injection showed the highest detection rate compared to the other two [62].

After the induction of anesthesia, the patient is placed in the dorsal lithotomy position. Using a speculum and a spinal needle, 1cc of dye is injected superficially (1–3 mm deep) and 1cc deep (1–2 cm deep) into the cervical stroma at the 3 o'clock and 9 o'clock positions (Fig. 2), for a total of 4 cc of dye. If unable to inject at these two points, a 4-point injection site is acceptable. The option of injecting ICG only superficially at 3 and 9 o'clock is acceptable, but 4 cc total volume is recommended. There is no consensus on the ICG dilution. A concentration between 0.5 to 1.25 mg/mL have been described [21,24]. We generally mix 25 mg of dry powder with 20 mL of sterile water obtaining a 1.25 mg/mL concentration, as reported in the FILM trial [24].

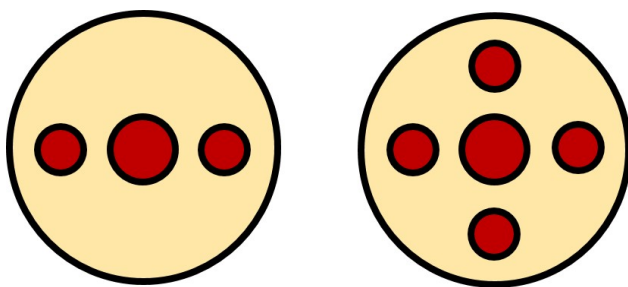


Fig. 2. Different sites of cervical injection in SLN technique.

Other types and sites of injection have been described in the literature, especially in intermediate and high-risk endometrial cancers [63–66] (e.g., fundal hysteroscopic injection or transvaginal ultrasound-guided myometrial injection (TUMIR)). The main reason for these different injection sites is to map the lymphatic channels to the aortic area that skip the pelvic region (infundibulo-pelvic pathway [67]).

These methods would probably help identify: (i) the isolated para-aortic metastases and (ii) patients who will benefit from extended-field radiation therapy. However, the low rate of isolated aortic metastases (<3%) and the unclear benefit of the aortic area staging make these procedures controversial. Generally, cervical injection is the preferred method [19].

### 2.2.3 Route of lymphatic drainage

Two main pelvic lymphatic pathways have been described [67]: an “upper” and “lower” paracervical pathway. Usually, the SLN is identified along the “upper paracervical pathway”, medial to the external iliac, or in the obturator region. The lymphatic trunk crosses over the obliterated umbilical artery, draining to the external iliac, or the obturator nodes, before crossing the external iliac artery, continuing laterally to the common iliac artery and lateral para-aortic and precaval areas. Less frequently, the SLNs are identified along the “lower paracervical pathway”, in the internal iliac and presacral region. The lymphatic way goes cephalad following the mesoureter, in the medial part of the internal iliac artery to the presacral area draining to the internal iliac and presacral nodes, before going medial to the common iliac artery to the medial paraaortic and precaval nodes.

In the FIRES trial, the SLNs were 38% of cases external iliac, 25% obturator, 14% inframesenteric para-aortic, 10% internal iliac, 8% common iliac, 3% presacral, 1% infrarenal para-aortic, and 1% parametrial [21]. Additionally, How *et al.* [68] found that 7.9% of SLNs were detected in areas not routinely harvested during a standard lymph node dissection, such as the internal iliac vein, parametrial, and presacral areas.

Recently, Moloney *et al.* [19] developed an “operation guide” of mandatory, optional, and prohibited steps to standardize the SLN technique for patients with endometrial cancer. For the SLN dissection, they suggest as mandatory: the identification of the obliterated umbilical ligament, the opening of the paravesical space, and starting the dissection at the level of the uterine artery and continuing it laterally away from the uterus.

In the case of non-migration of the dye, tracer re-injection is considered an option [15]. It is crucial to know a few reasons for a possible mapping failure, as described perfectly by Body *et al.* [69]. Firstly, enlarged lymph nodes and advanced FIGO stage have been described as factors for detection failure and false-negative cases [69]. Therefore, the removal of suspect nodes and lymphadenectomy in the non-mapped hemipelvis are of great importance, as per the MSKCC algorithm [20]. Secondly, before concluding that there is no SLN detection, a careful exploration of unusual locations should be performed. A decreased rate of bilateral detection rate has been described in patients with BMI >30. However, literature is controversial on this topic [69,70]. Some technical issues in cervical injection (e.g., spillage or too lateral injection) or diffuse smearing (too much dye in-

jected, too deep injection, or not gentle retroperitoneal dissection) may be related to the failed identification of the SLN. The expertise of the surgeon and gentle dissection of the retroperitoneal spaces may help in these issues. Lastly, a potential pitfall of the SLN mapping using ICG is the removal of “empty nodes”. Empty nodes have been defined as presumed mapped lymph nodes that do not contain nodal tissue at the pathology examination [71]. The incidence is reported between 5% and 8%, probably due to “swollen lymphatic channels” [71]. Being aware of the problem is the first aid in avoiding it. However, if using normal light, asking for an expert opinion, or touching the specimen are not sufficient to solve the problem, a frozen section of the SLN may help [70,71].

#### 2.2.4 Pathology examination: the ultra-staging of the SLN

SLNs are processed using a different technique from the non-sentinel nodes. This technique is called ultra-staging, and it involves two components. First, serial sectioning of the SLN with review of multiple hematoxylin and eosin (H&E) stained slides, and, second, cytokeratin immunohistochemistry (IHC) staining if standard staining method is negative [72]. In patients with endometrial cancer, the detection of nodal metastases is enhanced by applying an ultrastaging protocol. A two-fold increase in detection was previously described [43,73]. In two pioneering trials in SLN mapping, approximately 50% of the positive nodes were negative using the routine H&E staining; however low-volume metastases were detected using an ultra-staging protocol [21,22]. The sectioning and ultra-staging protocols vary among gynecologic pathologists, and internationally accepted guidelines are still unavailable [21,43]. Euscher *et al.* [74] reported no significant advantages using an extensive ultra-staging protocol. In our experience, an intensive ultra-staging protocol (with more than 20 H&E and 4 or more IHC slides per block) did not show an increase in SLN metastasis detection compared to the usually described “bread-loafing” method [75]. The “bread-loafing” method usually comprises: (i) slicing of the SLN perpendicular to the long axis; (ii) obtaining only one block; (iii) obtaining approximately 5 H&Es and 3 IHCs slides per block (each inclusion at an interval of 100 µm). However, many different and also less intensive ultra-staging protocols than what we use have been described [21,43,72,76].

Recently, the one-step nucleic acid amplification (OSNA) has been described as a possible alternative to ultrastaging in endometrial cancer [77,78]. However, more data are needed.

### 3. Conclusions

We believe that SLN biopsy is a reliable alternative to pelvic ± paraortic lymphadenectomy in patients with clinical early-stage endometrial cancer. The SLN has an excellent negative predictive value and sensitivity and it is showing to reduce morbidities. The international guidelines al-

ready accepted it as a possible alternative to lymphadenectomy. However, prospective studies on the oncologic outcome are still ongoing and more data are needed. Additionally, standardization of the technique and of the pathology evaluation would lead to less variability in health practices and outcomes.

### Author contributions

GM—Data collection, manuscript writing; TG—Data collection, manuscript writing; GDM—Data collection, manuscript writing; MA—Data collection, manuscript writing; GT—Data collection, manuscript writing; LB—Data collection, manuscript writing; FL—Project development, data collection, manuscript writing.

### Ethics approval and consent to participate

Not applicable.

### Acknowledgment

We would like to express our gratitude to all those who helped us during the writing of this manuscript. Thanks to all the peer reviewers for their opinions and suggestions and EJGO for taking into consideration the possibility of publishing this review.

### Funding

This research received no external funding.

### Conflict of interest

The authors declare no conflict of interest.

### References

- [1] World Health Organization. GLOBOCAN 2020: estimated cancer incidence, mortality and prevalence worldwide in 2020. 2020. Available at: <https://gco.iarc.fr/today/data/factsheets/cancers/24-Corpus-uteri-fact-sheet.pdf> (Accessed: 29 July 2020).
- [2] PDQ Adult Treatment Editorial Board. Endometrial Cancer Treatment (PDQ®): Health Professional Version. PDQ Cancer Information Summaries [Internet]. National Cancer Institute (US); Bethesda (MD). 2002.
- [3] Orr JW, Holloway RW, Orr PF, Holimon JL. Surgical staging of uterine cancer: an analysis of perioperative morbidity. *Gynecologic Oncology*. 1991; 42: 209–216.
- [4] Partridge EE, Shingleton HM, Menck HR. The National Cancer Data Base report on endometrial cancer. *Journal of Surgical Oncology*. 1996; 61: 111–123.
- [5] Benedetti Panici P, Basile S, Maneschi F, Alberto Lissoni A, Signorelli M, Scambia G, *et al.* Systematic pelvic lymphadenectomy vs no lymphadenectomy in early-stage endometrial carcinoma: randomized clinical trial. *Journal of the National Cancer Institute*. 2008; 100: 1707–1716.
- [6] ASTEC study group, Kitchener H, Swart AM, Qian Q, Amos C, Parmar MK, *et al.* Efficacy of systematic pelvic lymphadenectomy in endometrial cancer (MRC ASTEC trial): a randomised study. *Lancet*. 2009; 373: 125–136.
- [7] Achouri A, Huchon C, Bats AS, Bensaïd C, Nos C, Lécure F. Complications of lymphadenectomy for gynecologic cancer. *European Journal of Surgical Oncology*. 2013; 39: 81–86.

- [8] Abu-Rustum NR, Alektiar K, Iasonos A, Lev G, Sonoda Y, Aghajanian C, *et al.* The incidence of symptomatic lower-extremity lymphedema following treatment of uterine corpus malignancies: a 12-year experience at Memorial Sloan-Kettering Cancer Center. *Gynecologic Oncology*. 2006; 103: 714–718.
- [9] Creutzberg CL, van Putten WL, Koper PC, Lybeert ML, Jobsen JJ, Wárlám-Rodenhuis CC, *et al.* Surgery and postoperative radiotherapy versus surgery alone for patients with stage-1 endometrial carcinoma: multicentre randomised trial. *Lancet*. 2000; 355: 1404–1411.
- [10] Mariani A, Dowdy SC, Cliby WA, Gostout BS, Jones MB, Wilson TO, *et al.* Prospective assessment of lymphatic dissemination in endometrial cancer: a paradigm shift in surgical staging. *Gynecologic Oncology*. 2008; 109: 11–18.
- [11] de Hullu JA, Hollema H, Piers DA, Verheijen RH, van Diest PJ, Mourits MJ, *et al.* Sentinel lymph node procedure is highly accurate in squamous cell carcinoma of the vulva. *Journal of Clinical Oncology*. 2000; 18: 2811–2816.
- [12] Glaser G, Dinoi G, Multinu F, Yost K, Al Hilli M, Larish A, *et al.* Reduced lymphedema after sentinel lymph node biopsy versus lymphadenectomy for endometrial cancer. *International Journal of Gynecological Cancer*. 2021; 31: 85–91.
- [13] Nagar H, Wietek N, Goodall RJ, Hughes W, Schmidt-Hansen M, Morrison J. Sentinel node biopsy for diagnosis of lymph node involvement in endometrial cancer. *The Cochrane Database of Systematic Reviews*. 2021; 6: CD013021.
- [14] National Comprehensive Cancer Network. NCCN Clinical Practice Guidelines in Oncology, Uterine Neoplasms. Version 3. 2021. Available at: [http://www.nccn.org/professionals/physician\\_gls/pdf/uterine.pdf](http://www.nccn.org/professionals/physician_gls/pdf/uterine.pdf) (Accessed: 22 November 2021).
- [15] Concin N, Matias-Guiu X, Vergote I, Cibula D, Mirza MR, Marantz S, *et al.* ESGO/ESTRO/ESP guidelines for the management of patients with endometrial carcinoma. *International Journal of Gynecological Cancer*. 2021; 31: 12–39.
- [16] Morton DL, Wen DR, Wong JH, Economou JS, Cagle LA, Storm FK, *et al.* Technical details of intraoperative lymphatic mapping for early stage melanoma. *Archives of Surgery*. 1992; 127: 392–399.
- [17] Cody HS, Hill AD, Tran KN, Borgen PI. Credentialing for breast lymphatic mapping: how many cases are enough? *Annals of Surgery*. 1999; 229: 723–726.
- [18] Burke TW, Levenback C, Tornos C, Morris M, Wharton JT, Gershenson DM. Intraabdominal lymphatic mapping to direct selective pelvic and paraaortic lymphadenectomy in women with high-risk endometrial cancer: results of a pilot study. *Gynecologic Oncology*. 1996; 62: 169–173.
- [19] Moloney K, Janda M, Frumovitz M, Leitao M, Abu-Rustum NR, Rossi E, *et al.* Development of a surgical competency assessment tool for sentinel lymph node dissection by minimally invasive surgery for endometrial cancer. *International Journal of Gynecological Cancer*. 2021; 31: 647–655.
- [20] Barlin JN, Khoury-Collado F, Kim CH, Leitao Jr MM, Chi DS, Sonoda Y, *et al.* The importance of applying a sentinel lymph node mapping algorithm in endometrial cancer staging: beyond removal of blue nodes. *Gynecologic Oncology*. 2012; 125: 531–535.
- [21] Rossi EC, Kowalski LD, Scalici J, Cantrell L, Schuler K, Hanna RK, *et al.* A comparison of sentinel lymph node biopsy to lymphadenectomy for endometrial cancer staging (FIRES trial): a multicentre, prospective, cohort study. *The Lancet Oncology*. 2017; 18: 384–392.
- [22] Ballester M, Dubernard G, Lécuru F, Heitz D, Mathevet P, Marret H, *et al.* Detection rate and diagnostic accuracy of sentinel-node biopsy in early stage endometrial cancer: a prospective multicentre study (SENTI-ENDO). *The Lancet Oncology*. 2011; 12: 469–476.
- [23] Bodurtha Smith AJ, Fader AN, Tanner EJ. Sentinel lymph node assessment in endometrial cancer: a systematic review and meta-analysis. *American Journal of Obstetrics and Gynecology*. 2017; 216: 459–476.e10.
- [24] Frumovitz M, Plante M, Lee PS, Sandadi S, Lilja JF, Escobar PF, *et al.* Near-infrared fluorescence for detection of sentinel lymph nodes in women with cervical and uterine cancers (FILM): a randomised, phase 3, multicentre, non-inferiority trial. *The Lancet Oncology*. 2018; 19: 1394–1403.
- [25] Persson J, Salehi S, Bollino M, Lönnerfors C, Falconer H, Geppert B. Pelvic Sentinel lymph node detection in High-Risk Endometrial Cancer (SHREC-trial) - the final step towards a paradigm shift in surgical staging. *European Journal of Cancer*. 2019; 116: 77–85.
- [26] Cusimano MC, Vicus D, Pulman K, Maganti M, Bernardini MQ, Bouchard-Fortier G, *et al.* Assessment of Sentinel Lymph Node Biopsy vs Lymphadenectomy for Intermediate- and High-Grade Endometrial Cancer Staging. *JAMA Surgery*. 2021; 156: 157–164.
- [27] Soliman PT, Westin SN, Dioun S, Sun CC, Euscher E, Munsell MF, *et al.* A prospective validation study of sentinel lymph node mapping for high-risk endometrial cancer. *Gynecologic Oncology*. 2017; 146: 234–239.
- [28] Touhami O, Grégoire J, Renaud MC, Sebastianelli A, Plante M. Performance of sentinel lymph node (SLN) mapping in high-risk endometrial cancer. *Gynecologic Oncology*. 2017; 147: 549–553.
- [29] Daraï E, Dubernard G, Bats AS, Heitz D, Mathevet P, Marret H, *et al.* Sentinel node biopsy for the management of early stage endometrial cancer: long-term results of the SENTI-ENDO study. *Gynecologic Oncology*. 2015; 136: 54–59.
- [30] Buda A, Gasparri ML, Puppo A, Mereu L, De Ponti E, Di Martino G, *et al.* Lymph node evaluation in high-risk early stage endometrial cancer: A multi-institutional retrospective analysis comparing the sentinel lymph node (SLN) algorithm and SLN with selective lymphadenectomy. *Gynecologic Oncology*. 2018; 150: 261–266.
- [31] Buda A, Restaino S, Di Martino G, De Ponti E, Monterossi G, Dinoi G, *et al.* The impact of the type of nodal assessment on prognosis in patients with high-intermediate and high-risk ESMO/ESGO/ESTRO group endometrial cancer. A multicenter Italian study. *European Journal of Surgical Oncology*. 2018; 44: 1562–1567.
- [32] Zahl Eriksson AG, Ducie J, Ali N, McGree ME, Weaver AL, Bogani G, *et al.* Comparison of a sentinel lymph node and a selective lymphadenectomy algorithm in patients with endometrioid endometrial carcinoma and limited myometrial invasion. *Gynecologic Oncology*. 2016; 140: 394–399.
- [33] Schlappe BA, Weaver AL, Ducie JA, Eriksson AGZ, Dowdy SC, Cliby WA, *et al.* Multicenter study comparing oncologic outcomes between two nodal assessment methods in patients with deeply invasive endometrioid endometrial carcinoma: A sentinel lymph node algorithm versus a comprehensive pelvic and paraaortic lymphadenectomy. *Gynecologic Oncology*. 2018; 151: 235–242.
- [34] Bogani G, Papadia A, Buda A, Casarin J, Di Donato V, Gasparri ML, *et al.* Sentinel node mapping vs. sentinel node mapping plus back-up lymphadenectomy in high-risk endometrial cancer patients: Results from a multi-institutional study. *Gynecologic Oncology*. 2021; 161: 122–129.
- [35] Basaran D, Bruce S, Aviki EM, Mueller JJ, Broach VA, Cadoo K, *et al.* Sentinel lymph node mapping alone compared to more extensive lymphadenectomy in patients with uterine serous carcinoma. *Gynecologic Oncology*. 2020; 156: 70–76.
- [36] Abu-Rustum NR, Khoury-Collado F, Pandit-Taskar N, Soslow

- RA, Dao F, Sonoda Y, *et al.* Sentinel lymph node mapping for grade 1 endometrial cancer: is it the answer to the surgical staging dilemma? *Gynecologic Oncology*. 2009; 113: 163–169.
- [37] Mariani A, Webb MJ, Keeney GL, Haddock MG, Calori G, Podratz KC. Low-risk corpus cancer: Is lymphadenectomy or radiotherapy necessary? *American Journal of Obstetrics and Gynecology*. 2000; 182: 1506–1519.
- [38] Suidan RS, Sun CC, Cantor SB, Mariani A, Soliman PT, Westin SN, *et al.* Three Lymphadenectomy Strategies in Low-Risk Endometrial Carcinoma: A Cost-Effectiveness Analysis. *Obstetrics and Gynecology*. 2018; 132: 52–58.
- [39] Schiavone MB, Zivanovic O, Zhou Q, Leitao MM Jr, Levine DA, Soslow RA, *et al.* Survival of Patients with Uterine Carcinosarcoma Undergoing Sentinel Lymph Node Mapping. *Annals of Surgical Oncology*. 2016; 23: 196–202.
- [40] Schiavone MB, Scelzo C, Straight C, Zhou Q, Alektiar KM, Makker V, *et al.* Survival of Patients with Serous Uterine Carcinoma Undergoing Sentinel Lymph Node Mapping. *Annals of Surgical Oncology*. 2017; 24: 1965–1971.
- [41] Grassi T, Mariani A, Cibula D, Soliman PT, Suman VJ, Weaver AL, *et al.* A prospective multicenter international single-arm observational study on the oncological safety of the sentinel lymph node algorithm in stage I intermediate-risk endometrial cancer (SELECT, SEntinel Lymph node Endometrial Cancer Trial). *International Journal of Gynecological Cancer*. 2020; 30: 1627–1632.
- [42] Colombo N, Creutzberg C, Amant F, Bosse T, González-Martín A, Ledermann J, *et al.* ESMO-ESGO-ESTRO Consensus Conference on Endometrial Cancer: diagnosis, treatment and follow-up. *Annals of Oncology*. 2016; 27: 16–41.
- [43] Kim CH, Soslow RA, Park KJ, Barber EL, Khoury-Collado F, Barlin JN, *et al.* Pathologic ultrastaging improves micrometastasis detection in sentinel lymph nodes during endometrial cancer staging. *International Journal of Gynecological Cancer*. 2013; 23: 964–970.
- [44] Han G, Lim D, Leitao MM Jr, Abu-Rustum NR, Soslow RA. Histological features associated with occult lymph node metastasis in FIGO clinical stage I, grade I endometrioid carcinoma. *Histopathology*. 2014; 64: 389–398.
- [45] McCready DR, Yong WS, Ng AK, Miller N, Done S, Youngson B. Influence of the new AJCC breast cancer staging system on sentinel lymph node positivity and false negative rates. *Journal of the National Cancer Institute*. 2004; 96: 873–875.
- [46] Buda A, Di Martino G, Restaino S, De Ponti E, Monterossi G, Giuliani D, *et al.* The impact on survival of two different staging strategies in apparent early stage endometrial cancer comparing sentinel lymph nodes mapping algorithm and selective lymphadenectomy: an Italian retrospective analysis of two reference centers. *Gynecologic Oncology*. 2017; 147: 528–534.
- [47] Ducie JA, Eriksson AGZ, Ali N, McGree ME, Weaver AL, Bogani G, *et al.* Comparison of a sentinel lymph node mapping algorithm and comprehensive lymphadenectomy in the detection of stage IIIC endometrial carcinoma at higher risk for nodal disease. *Gynecologic Oncology*. 2017; 147: 541–548.
- [48] Holloway RW, Abu-Rustum NR, Backes FJ, Boggess JF, Gotlieb WH, Jeffrey Lowery W, *et al.* Sentinel lymph node mapping and staging in endometrial cancer: a Society of Gynecologic Oncology literature review with consensus recommendations. *Gynecologic Oncology*. 2017; 146: 405–415.
- [49] Todo Y, Kato H, Okamoto K, Minobe S, Yamashiro K, Sakuragi N. Isolated tumor cells and micrometastases in regional lymph nodes in stage I to II endometrial cancer. *Journal of Gynecologic Oncology*. 2016; 27: e1.
- [50] St Clair CM, Eriksson AG, Ducie JA, Jewell EL, Alektiar KM, Hensley ML, *et al.* Low-volume lymph node metastasis discovered during sentinel lymph node mapping for endometrial carcinoma. *Annals of Surgical Oncology*. 2016; 23: 1653–1659.
- [51] Plante M, Stanleigh J, Renaud MC, Sebastianelli A, Grondin K, Grégoire J. Isolated tumor cells identified by sentinel lymph node mapping in endometrial cancer: does adjuvant treatment matter? *Gynecologic Oncology*. 2017; 146: 240–246.
- [52] Ghoniem K, Larish AM, Dinoi G, Zhou XC, Alhilli M, Wallace S, *et al.* Oncologic outcomes of endometrial cancer in patients with low-volume metastasis in the sentinel lymph nodes: An international multi-institutional study. *Gynecologic Oncology*. 2021; 162: 590–598.
- [53] Buda A, Crivellaro C, Elisei F, Di Martino G, Guerra L, De Ponti E, *et al.* Impact of indocyanine green for sentinel lymph node mapping in early stage endometrial and cervical cancer: comparison with conventional radiotracer (99m)Tc and/or blue dye. *Annals of Surgical Oncology*. 2016; 23: 2183–2191.
- [54] How J, Gotlieb WH, Press JZ, Abitbol J, Pelmus M, Ferenczy A, *et al.* Comparing indocyanine green, technetium, and blue dye for sentinel lymph node mapping in endometrial cancer. *Gynecologic Oncology*. 2015; 137: 436–442.
- [55] Jewell EL, Huang JJ, Abu-Rustum NR, Gardner GJ, Brown CL, Sonoda Y, *et al.* Detection of sentinel lymph nodes in minimally invasive surgery using indocyanine green and near-infrared fluorescence imaging for uterine and cervical malignancies. *Gynecologic Oncology*. 2014; 133: 274–277.
- [56] Rozenholc A, Samouelian V, Warkus T, Gauthier P, Provencher D, Sauthier P, *et al.* Green versus blue: Randomized controlled trial comparing indocyanine green with methylene blue for sentinel lymph node detection in endometrial cancer. *Gynecologic Oncology*. 2019; 153: 500–504.
- [57] Backes FJ, Cohen D, Salani R, Cohn DE, O'Malley DM, Fanning E, *et al.* Prospective clinical trial of robotic sentinel lymph node assessment with isosulfane blue (ISB) and indocyanine green (ICG) in endometrial cancer and the impact of ultrastaging (NCT01818739). *Gynecologic Oncology*. 2019; 153: 496–499.
- [58] Khoury-Collado F, Abu-Rustum NR. Lymphatic mapping in endometrial cancer: a literature review of current techniques and results. *International Journal of Gynecological Cancer*. 2008; 18: 1163–1168.
- [59] Abu-Rustum NR, Khoury-Collado F, Gemignani ML. Techniques of sentinel lymph node identification for early-stage cervical and uterine cancer. *Gynecologic Oncology*. 2008; 111: S44–50.
- [60] Abu-Rustum NR. Sentinel Lymph Node Mapping for Endometrial Cancer: A Modern Approach to Surgical Staging. *Journal of the National Comprehensive Cancer Network*. 2014; 12: 288–297.
- [61] Abu-Rustum NR, Gomez JD, Alektiar KM, Soslow RA, Hensley ML, Leitao MM Jr, *et al.* The incidence of isolated paraaortic nodal metastasis in surgically staged endometrial cancer patients with negative pelvic lymph nodes. *Gynecologic Oncology*. 2009; 115: 236–238.
- [62] Ditto A, Casarin I, Pinelli C, Perrone AM, Scollo P, Martinelli F, *et al.* Hysteroscopic versus cervical injection for sentinel node detection in endometrial cancer: A multicenter prospective randomised controlled trial from the Multicenter Italian Trials in Ovarian cancer (MITO) study group. *European Journal of Cancer*. 2020; 140: 1–10.
- [63] Martinelli F, Ditto A, Bogani G, Leone Roberti Maggiore U, Signorelli M, *et al.* Sentinel lymph node mapping in endometrial cancer: performance of hysteroscopic injection of tracers. *International Journal of Gynecological Cancer*. 2020; 30: 332–338.
- [64] Angeles MA, Migliorelli F, Vidal-Sicart S, Saco A, Ordi J, Ros C, *et al.* Paraaortic sentinel lymph node detection in intermediate and high-risk endometrial cancer by transvaginal ultrasound-guided myometrial injection of radiotracer (TUMIR). *Journal of*



Gynecologic Oncology. 2021; 32: e52.

- [65] Farazestanian M, Yousefi Z, Zarifmahmoudi L, Hasanzadeh Mofrad M, Kadkhodayan S, Sadeghi R. Concordance Between Intracervical and Fundal Injections for Sentinel Node Mapping in Patients With Endometrial Cancer?: A Study Using Intracervical Radiotracer and Fundal Blue Dye Injections. *Clinical Nuclear Medicine*. 2019; 44: e123–e127.
- [66] Torné A, Pahisa J, Vidal-Sicart S, Martínez-Roman S, Paredes P, Puerto B, *et al.* Transvaginal ultrasound-guided myometrial injection of radiotracer (TUMIR): a new method for sentinel lymph node detection in endometrial cancer. *Gynecologic Oncology*. 2013; 128: 88–94.
- [67] Geppert B, Lönnerfors C, Bollino M, Arechvo A, Persson J. A study on uterine lymphatic anatomy for standardization of pelvic sentinel lymph node detection in endometrial cancer. *Gynecologic Oncology*. 2017; 145: 256–261.
- [68] How J, Boldeanu I, Lau S, Salvador S, How E, Gotlieb R, *et al.* Unexpected locations of sentinel lymph nodes in endometrial cancer. *Gynecologic Oncology*. 2017; 147: 18–23.
- [69] Body N, Grégoire J, Renaud MC, Sebastianelli A, Grondin K, Plante M. Tips and tricks to improve sentinel lymph node mapping with Indocyanin green in endometrial cancer. *Gynecologic Oncology*. 2018; 150: 267–273.
- [70] Tanner EJ, Sinno AK, Stone RL, Levinson KL, Long KC, Fader AN. Factors associated with successful bilateral sentinel lymph node mapping in endometrial cancer. *Gynecologic Oncology*. 2015; 138: 542–547.
- [71] Casarin J, Multinu F, Pasupathy K, Weaver A, McGree M, Tortorella L, *et al.* Frozen Section for Detection of Lymph Nodes After Cervical Injection with Indocyanine Green (ICG) for Sentinel Lymph Node Technique in Endometrial Cancer Staging. *Annals of Surgical Oncology*. 2018; 25: 3692–3698.
- [72] Euscher ED, Malpica A. Gynaecological malignancies and sentinel lymph node mapping: an update. *Histopathology*. 2020; 76: 139–150.
- [73] Holloway RW, Gupta S, Stavitzski NM, Zhu X, Takimoto EL, Gubbi A, *et al.* Sentinel lymph node mapping with staging lymphadenectomy for patients with endometrial cancer increases the detection of metastasis. *Gynecologic Oncology*. 2016; 141: 206–210.
- [74] Euscher E, Sui D, Soliman P, Westin S, Ramalingam P, Bassett R, *et al.* Ultrastaging of Sentinel Lymph Nodes in Endometrial Carcinoma According to Use of 2 Different Methods. *International Journal of Gynecological Pathology*. 2018; 37: 242–251.
- [75] Grassi T, Dell’Orto F, Jaconi M, Lamanna M, De Ponti E, Paderno M, *et al.* Two ultrastaging protocols for the detection of lymph node metastases in early-stage cervical and endometrial cancers. *International Journal of Gynecological Cancer*. 2020; 30: 1404–1410.
- [76] Burg LC, Hengeveld EM, In ’t Hout J, Bulten J, Bult P, Zusterzeel PLM. Ultrastaging methods of sentinel lymph nodes in endometrial cancer - a systematic review. *International Journal of Gynecological Cancer*. 2021; 31: 744–753.
- [77] Fanfani F, Monterossi G, Di Meo ML, La Fera E, Dell’Orto F, Gioè A, *et al.* Standard ultra-staging compared to one-step nucleic acid amplification for the detection of sentinel lymph node metastasis in endometrial cancer patients: a retrospective cohort comparison. *International Journal of Gynecological Cancer*. 2020; 30: 372–377.
- [78] Diestro MD, Berjón A, Zapardiel I, Yébenes L, Ruiz I, Lekuona A, *et al.* One-Step Nucleic Acid Amplification (OSNA) of Sentinel Lymph Node in Early-Stage Endometrial Cancer: Spanish Multicenter Study (ENDO-OSNA). *Cancers*. 2021; 13: 4465.