

Uterine mullerian adenosarcoma in very young patient

Tajossadat Allameh¹, Elham Naghshineh¹, Leila Mousavi Seresht², Parvin Rajabi³, Narges Izadi-Mood⁴

¹Department of Obstetrics and Gynecology, School of Medicine, Isfahan University of Medical Sciences, Isfahan, Iran

²Department of Obstetrics and Gynecology, School of Medicine, Isfahan University of Medical Sciences, Isfahan, Iran

³Professor of pathology, Department of Pathology, School of Medicine, Isfahan University of Medical Sciences, Isfahan, Iran

⁴Professor of pathology, Department of Pathology, School of Medicine, Tehran University of Medical Sciences, Tehran, Iran

Summary

Introduction: Uterine adenosarcoma mostly seen in elderly and there are limited data on appropriate approach in premenopausal patient and the accurate prognosis. Herein we aimed to present a young case of Müllerian adenosarcoma of uterus which had only 9 years old. **Case report:** A 9-year-old pre-pubertal girl presented to the gynecology department of Isfahan University of Medical Sciences-Iran with the vaginal bleeding. An intrauterine mass was noted via hysteroscopic examination as the reason of abnormal bleeding. The final pathology revealed Müllerian adenosarcoma of uterus. Subsequently hysterectomy was done due to persistent profuse vaginal bleeding; with ovarian preservation. **Conclusion:** Due to rarity of Müllerian adenosarcoma, the gynecologists and pathologists should be reminded about the possibility of the diagnosis in young patients too.

Key words: Müllerian adenosarcoma; Uterine; Mesenchymal tumor; Childhood; Vaginal bleeding; Adolescent.

Introduction

Uterine Müllerian adenosarcoma (MA) is typically a variant of endometrial stromal sarcoma with benign epithelial component which reported first in 1974 [1]. Uterine MA is relatively rare and account less than 5% of uterine sarcoma which is only less than 3% of all uterine neoplasm. Based on this rarity the FIGO classification had classified this group of uterine cancer in a different manner [2, 3].

In general, the clinical behavior of uterine sarcomas is unfavorable but it supposed that the polypoid MA behave as a low grade tumor most of the time and the prognosis depends on the sarcomatous component growth rate [3-5]. The standard treatment in uterine sarcomas is total hysterectomy and bilateral salpingo-oophorectomy (BSO) [1, 3]. While the safety of ovarian preservation in uterine limited leiomyosarcoma had been derived from population based database, due to small case series of adenosarcoma there is no consensus on oncologic outcome of this approach in reproductive age [6, 7].

Here we decided to define the optimal management in Müllerian adenosarcoma with evaluating the oncologic outcome of similar FIGO subtype cases report and describe possibly the youngest case of uterine Müllerian adenosarcoma in the world.

Case report

A 9-year-old previously healthy girl presented in November 2018 with chief complaint of vaginal bleeding started 2 months before attending the hospital. The pubertal development was rejected because there was no sign of breast maturation or hair growing on the pubic and axillary area. There was no sign in favor of sexual abuse and the hymen was intact. In assessing the source of abnormal vaginal bleeding, hormonal function

test and pelvic ultrasonography was requested. The FSH & LH was reported lower than normal and the elevated ESR was the lone finding; in about 102.

An enlarged uterus approximately 78*56*40 mm with thick heterogeneous endometrial thickness near 16 mm with multiple cystic area was shown on sonography. The patient subsequently underwent vaginoscopy and hysteroscopic examination. The vagina and cervix appeared normal but surprisingly a huge polypoid mass which occupied intra-uterine cavity was noted with no endometrial hyperplasia in regards (Figure 1-A). The mass had resected totally (Figure 1-B) and the histological examination of the mass revealed Müllerian adenosarcoma (Figure 1-C). The hysteroscopic sample was reviewed with another gynecopathologist and low grade polypoid Müllerian adenosarcoma with mild to moderate atypia, hemorrhagic necrosis and few mitosis was confirmed.

A further investigation, such as chest radiography and Abdomino/pelvic magnetic resonance imaging (MRI) of the pelvis was done preoperatively. Unfortunately MRI of pelvis which had performed 2 weeks after hysteroscopic resection of the uterine mass again showed a polypoid nodule (3*2.5 cm) with no obvious myometrial invasion (Figure 2). There was no evidence of distant metastasis on other imaging.

After a thorough evaluation of the literature, the patient and her parents were discussed by the multidisciplinary team about the disease prognosis, The standard treatment and the other possible options. Complete staging laparotomy with ovarian preservation was the final decision. They declined the less aggressive approach due to non-documented safety based on limited prior case reports and the patient persistent symptom of abnormal vaginal bleeding. The procedure was performed uneventful in December 2018. On gross examination

Table 1. — The youngest stage I (17) Müllerian adenosarcoma (uterine & cervical) in literature; characteristic, management and available prognosis.

Reference	Location	Case (age)	Chief complaint	Primary treatment	Prognosis	Disease free period
[5]	Uterine	21	Menorrhagia & anemia	Local excision	Normal delivery and local recurrences	3 years
[6]	Uterine	31 (the mean age)		7 had local excision	1 Normal delivery, 2 recurrences after conservative M, One with metastasis (this one had sarcomatous overgrowth before)	13-27 months
[15]	Cervix	10 y	Vaginal bleeding and cervical mass	TAH-BSO-staging		-
[9]	Uterine	15 y	With heterologous component		TAH-BSO-ChT-RT	-
[14]	Cervix	11- 25Y	With heterologous component	metrorrhagia	TAH (simple or radical) ± BSO-RT-ChT	1.5-3.5 years
[12]	Cervix	15	With heterologous component	metrorrhagia	Local excision	4 years
[13]	Cervix	23	With heterologous component		Local excision	Lost follow up!
[7]	Cervix	28		metrorrhagia	Local excision	-
[18]	Cervix	26	With heterologous component	Pelvic pain and bleeding	TAH	No follow-up

TAH: total abdominal hysterectomy, RT: radiotherapy adjuvant, ChT: chemotherapy adjuvant, BSO: bilateral salpingoophorectomy.

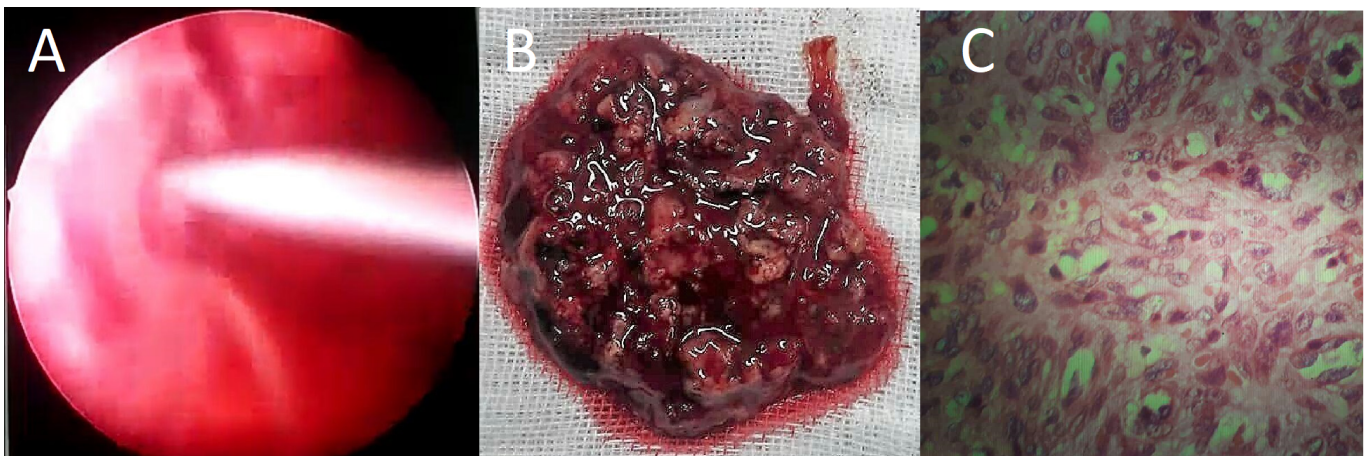


Figure 1. — Hysteroscopic view of endometrial mass (A) which was resected completely (B), The pathologic examination of the sample was suggestive of Adenosarcoma (C: 400× HPF).

the uterus was larger than normal size and there was no signs of macroscopic involvement of other organs. Pathologic examination documented the polypoid low grade uterine MA in about 4*4*2 cm with near 2mm myometrial invasion; (Figure 3), the tumor was characterized by benign epithelial component and malignant sarcomatous stromal component with more than 2mitosis/HPF based on WHO criteria [3]; the other sample was free of malignancy (Figure 4). She was discharged well two days after surgery and is currently disease free after four months.

Discussion

Low grade uterine Müllerian adenosarcoma (MA) as an biphasic neoplasm are expected to have good prognosis in the absence of myometrial deep invasion and sarcomatous overgrowth [1, 3]. The commonest presenting symptom is vaginal bleeding [3]. There is no proven etiology for MA; the lone

possible risk factor based on previous study is prior pelvic radiation history, hormone or tamoxifen therapy [3, 8] which was not found in our case at all.

Fortunately most of the time these neoplasm presented in early stage and the prognosis is based on sarcomatous stromal architecture [3]. The absence of sarcomatous overgrowth, lymphovascular and deep myometrial invasion lead to 5-years survival of 100 % [1, 5]. Adenofibroma as a benign polypoid lesion must be differentiated from the diagnosis of uterine MA with caution; whit marked atypia in mesenchymal cells and more than 1 mitotic figure per 10HPF [3]. The other differential diagnoses are Müllerian mesenchymal malignant tumor and rhabdomyosarcoma [3].

The commonest age of MA presentation is postmenopausal patient, it seems that cervical MA is more common in younger age than uterine originated tumor [9]. Based on previous case reports the youngest age for low grade uterine MA was 15

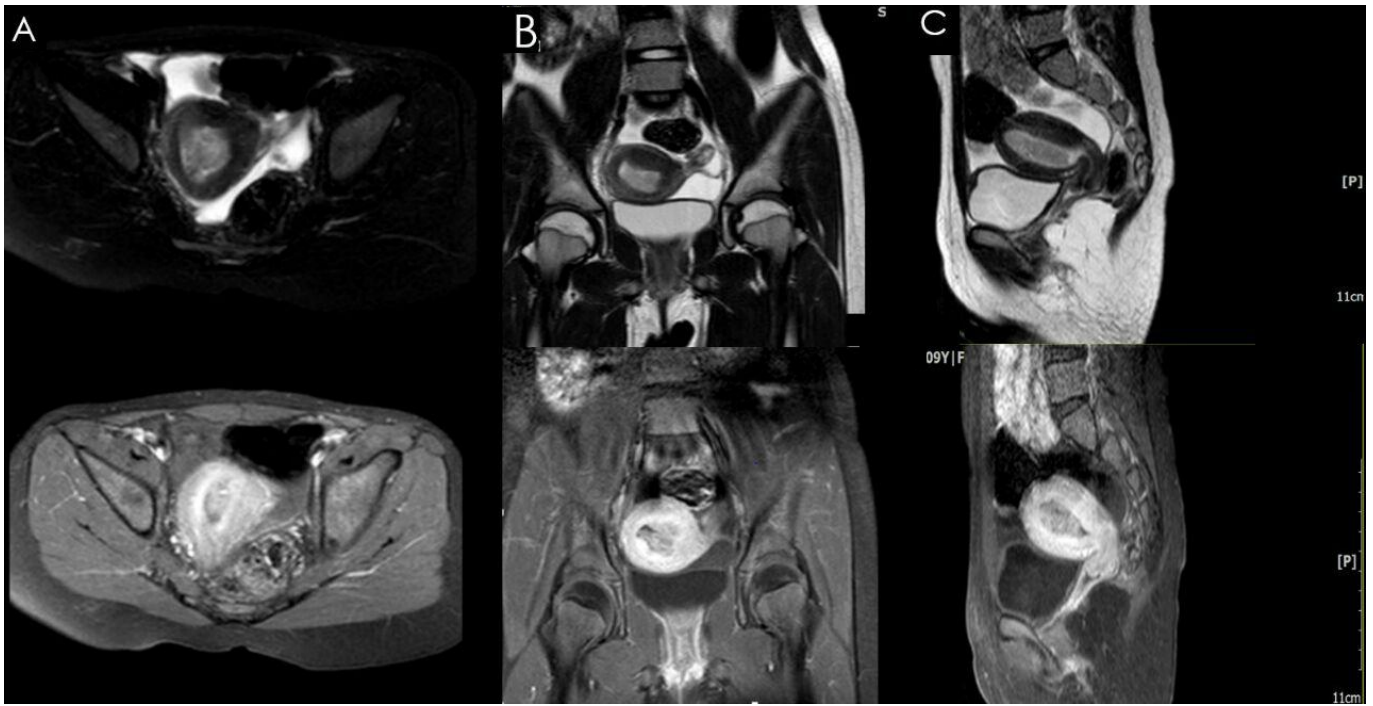

Figure 2. — MRI shows a normal endometrium and myometrium with a mass originating in the corpus body (sagittal, coronal, axial view in T1 & T2 gradient slice; A, B, C).

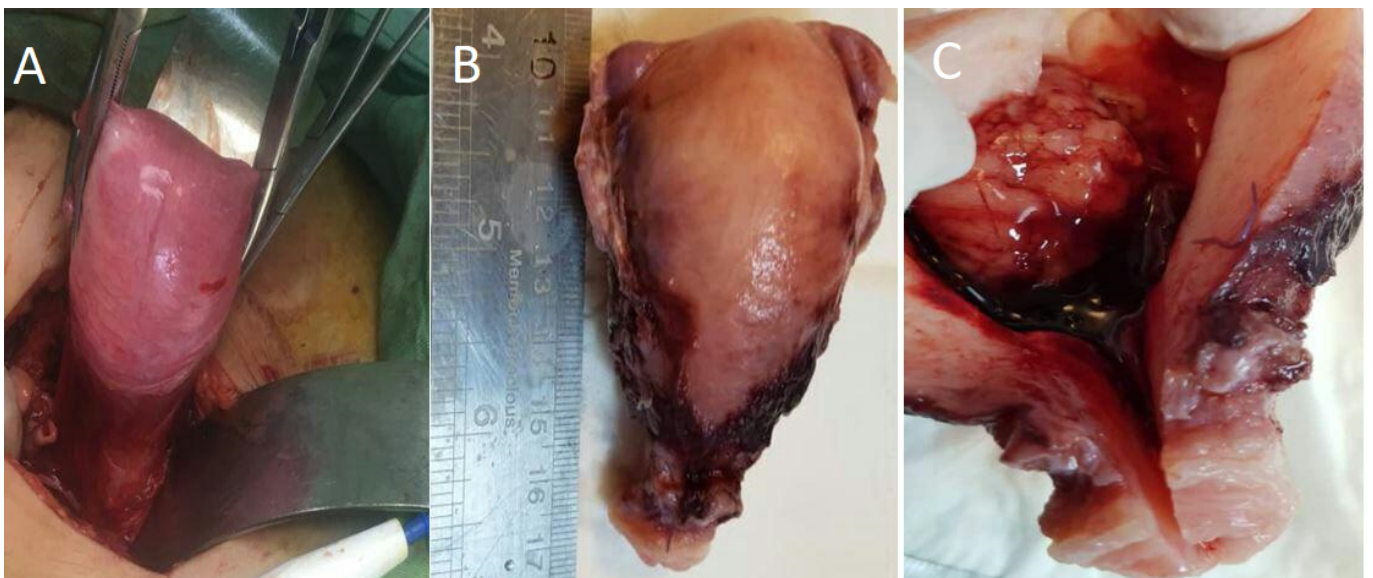


Figure 3. — The hysterectomy specimen (A), The histologic examination of the uterus showed a 8*5*3 cm corpus uteri (B) with a 4*4*2 cm polypoid mass with 2 mm invasion to myometrium (C).

years [7]. So there is limited data concerning the prognosis of fertility preservation in reproductive age patient [3, 5]. The gold standard of treatment is surgical staging but there is some studies that showed no adverse oncologic outcome in regards of local excision or at least ovarian preservation in reproductive age [3, 4, 9]. Also there is no consensus on the rule of lymph node dissection (LND) in MA [2].

Ovarian preservation is based on the low probability of

ovarian metastasis but to the best of our knowledge mesenchymal element of MA have Estrogen receptor expression so evidence on the safety of ovarian preservation is limited and there are some studies on the high possibility of recurrence by conservative surgery [2]. Furthermore there is less than 5 cases with successful pregnancy after MA fertility preservation approach [1]. It must emphasis on the long term follow-up for this patient due to the possibility of late recurrences even after

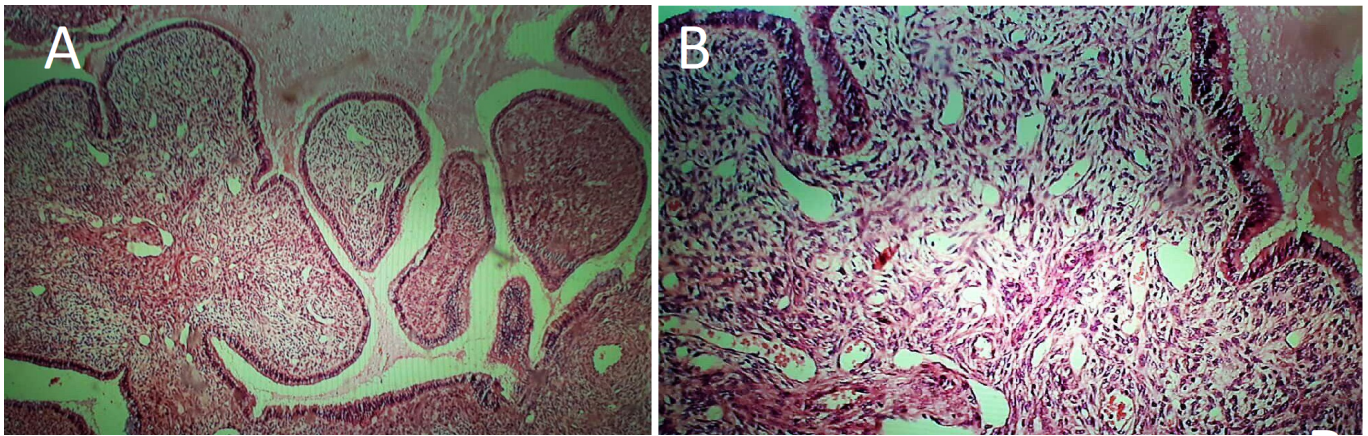


Figure 4. — The microscopic examination confirmed the low grade müllerian adenosarcoma with spindle & papillary like structure with mild to moderate pleomorphism and nuclear atypia (3/10 HPF) (A, B: 40 \times , 100 \times HPF).

11 years [2, 9]. Table 1 shows the youngest stage 1 Müllerian adenosarcoma (uterine& cervical) in literature.

Based on favorable pathologic criteria of present young case; lack of gross abnormalities via intraoperative inspection, absence of lymphovascular invasion and heterologous or sarcomatous overgrowth component; the poor prognostic characteristic of MA; BSO and LND was omitted from surgical planning [4, 2]. Adjuvant therapy was not done for present patient because of absence of sarcomatous overgrowth or heterologous tissue and no residue of tumor after surgery [10].

Conclusions

Due to rarity of Müllerian adenosarcoma (MA), The gynecologists and pathologists should be reminded about the possibility of this diagnosis. The optimal management of MA is uncertain and the safety of either uterine or ovary preservation is still under exploration and so should be individualized, Long term surveillance is warranted to provide more information about these unusual neoplasm behavior and the significance of genetic and race on the age of MA presentation.

Acknowledgements

We would like to acknowledge Dr Zahrasadat Allameh for her review.

Conflict of Interest

All authors declare that there is no conflict of interests regarding the publication of this article.

Submitted: September 10, 2019

Accepted: October 28, 2019

Published: October 15, 2020

References

- [1] Wu R.I., Schorge J.O., Cin P.D., Young R.H., Oliva E.: "Müllerian adenosarcoma of the uterus with low-grade sarcomatous overgrowth characterized by prominent hydropic change resulting in mimicry of a smooth muscle tumor". *Int. J. Gynecol. Pathol.*, 2014, 33, 573.
- [2] Nasioudis D., Chapman-Davis E., Frey M., Holcomb K.: "Safety of ovarian preservation in premenopausal women with stage I uterine sarcoma". *J. gynecol. oncol.* 2017, 19, 28.
- [3] Patrelli T.S., Gizzo S., Di Gangi S., Guidi G., Rondinelli M., Nardelli G.B.: "Cervical Müllerian adenosarcoma with heterologous sarcomatous overgrowth: a fourth case and review of literature". *BMC Cancer*, 2011, 11, 236.
- [4] Goh C., Lin X.H., Chin P.S., Lim Y.K.: "Uterine preservation in a young patient with adenosarcoma of the uterus—Case report and review of literature". *Gynecol. Oncol.Rep.*, 2018, 25, 27.
- [5] Lee Y., Kim D., Suh D., Kim J., Kim Y., Kim Y., *et al.*: "Feasibility of uterine preservation in the management of early-stage uterine adenocarcinomas: a single institute experience". *World J. Surg. oncol.*, 2017, 15, 87.
- [6] Yoon A., Park J.Y., Park J.Y., Lee Y.Y., Kim T.J., Choi C.H., *et al.*: "Prognostic factors and outcomes in endometrial stromal sarcoma with the 2009 FIGO staging system: a multicenter review of 114 cases". *Gynecol. Oncol.*, 2014, 132, 70.
- [7] Li N., Wu L.Y., Zhang H.T., An J.S., Li X.G., Ma S.K.: "Treatment options in stage I endometrial stromal sarcoma: a retrospective analysis of 53 cases". *Gynecol. Oncol.*, 2008, 108, 306.
- [8] Sangale N.A., Lele S.M.: "Uterine mesenchymal tumors". *Indian J. Pathol. Microbiol.*, 2011, 54, 243.
- [9] Ramos P., Ruiz A., Carabias E., Piñero I., Garzon A., Alvarez I.: "Müllerian adenocarcinoma of the cervix with heterologous elements: report of a case and review of the literature". *Gynecol. oncol.*, 2002, 84, 161.
- [10] Morales F.D.A., Medina R.M.L., Trujillo L.M., Beltrán M.I., Dulcey I.C.: "Müllerian adenocarcinoma of the uterine cervix with sarcomatous overgrowth: A case report of aggressive disease in a young patient". *Int.J. Sur. Case Rep.*, 2016, 27, 155.

Corresponding Author:

TAJOSSADAT ALLAMEH, M.D.

Fellowship of gynecologyoncology, Department of Obstetrics and Gynecology,

School of Medicine, Isfahan University of Medical Sciences, Isfahan (Iran)

e-mail: tallameh@med.mui.ac.ir.