

Cervical cone dimension and linear CIN extension trend: 28 years' experience of a tertiary center

Mario Preti¹, Niccolò Gallio^{1,*}, Federica Bevilacqua¹, Giorgia Pasquero¹, Leonardo Micheletti¹, Chiara Benedetto¹

¹Department of Surgical Sciences, Gynecology and Obstetrics 1, City of Health and Science, University of Torino, 10126 Torino, Italy

*Correspondence: niccolo.gallio@edu.unito.it (Niccolò Gallio)

DOI:10.31083/j.ejgo4205132

This is an open access article under the CC BY 4.0 license (<https://creativecommons.org/licenses/by/4.0/>).

Submitted: 7 May 2021 Revised: 6 July 2021 Accepted: 20 July 2021 Published: 15 October 2021

Objective: To evaluate trend in cervical cone length and CIN linear extension in women treated in a tertiary referral centre over a 28 years period. **Methods:** A retrospective study including 3716 women treated with cervical conization for biopsy-proven HSIL (CIN grade 2 and 3), glandular lesions and microinvasive squamous cervical cancer from 1992 to 2020. Relevant clinical and histopathological data were collected. **Results:** A mean cone length of 9.5 mm (SD 5.1 mm, range 1–40 mm) and CIN linear extension of 6.58 mm (SD 3.38 mm, range 1–45 mm) were found. A 35% significant decrease in cone length was observed in the 28 years period, while no differences were found in CIN extension. Furthermore, ectocervical and endocervical margin positivity rates were stable over the study period and not affected by decreasing cone length. **Conclusion:** The current study reported a significant trend of reduction in cone length from 1992 to 2020 while margin status was unaffected. This may reflect less invasive approach and increased attention to obstetric outcomes.

Keywords

Cervical intraepithelial neoplasia; Screening; Cervical conization; Cone dimension; Linear CIN extension

1. Introduction

Incidence and mortality of cervical cancer have steadily decreased over the last 30 years, since introduction of organized screening programs, whose aim is to detect and treat Cervical Intraepithelial Neoplasia (CIN) lesions before they progress to invasive disease [1]. In Italy, for instance, organized screening program brought a reduction of approximately 40% of cervical cancer incidence after 10 years from introduction and stabilized thereafter [2].

At the same pace disease stages have been changed, and a 55% increase in CIN3 incidence together with a 50–55% decrease in early and advanced invasive cancer from 1995 to 2014 were reported [3].

While preinvasive lesion treatment using Large Loop Excision of the Transformation Zone/Loop Electrosurgical Excision Procedure LLETZ/LEEP has proven to be highly effective in reducing subsequent cervical cancer incidence [4], diagnosis and treatment for CIN occur mainly in women in reproductive age with reported adverse obstetric outcomes [5]. Therefore, minimal impact on women reproductive fu-

ture is of utmost importance as well as the high effectiveness of CIN treatment.

Some studies have underlined a decreasing trend in cone dimensions and in particular in cone length [6–8], considering the awareness of treatment impact on reproductive health.

The aim of this study is to present 28 years trends in cone dimension and CIN linear lesion extension in a large tertiary referral center in Northern Italy.

2. Methods

We conducted a retrospective cohort study of all patients undergoing cervical conization (cold knife, LEEP, or radiofrequency needle) for biopsy-proven cervical High Grade Squamous Intraepithelial Lesion (HSIL) (encompassing CIN grade 2 and 3), glandular lesions and microinvasive squamous cervical carcinoma at the tertiary referral center Lower Genital Tract Disease Clinic Unit 1 of the Department of Surgical Sciences, University of Torino, from January 1992 and to December 2020.

Women were referred to our center by either organized cervical cancer screening program or private gynecological practice.

The following histological information were collected:

(1) The three dimensions of each cone specimen, measured by the pathologist in millimeter using a ruler after formalin fixation. The first and second measures were the two perpendicular radius of cone base. Cone length was considered from external cervical os to the most distal margin.

(2) Area of the cone base was calculated using ellipse formula ($\text{Area} = \pi \times r1 \times r2$).

(3) Margins status was considered: ectocervical margin, endocervical margin and “deep” margin (lateral margin involving endocervical gland crypts).

(4) Endocervical crypt involvement: absent, focal in case of <50% gland depth involvement, and massive in case of >50% gland depth involvement.

(5) Linear extension of CIN lesion measured in millimeter with a microscope ruler.

(6) Histopathological diagnosis was recorded according WHO classification [9] as negative, CIN1, CIN2, CIN3, mi-

croinvasive or invasive squamous cell carcinoma, AIS (Adenocarcinoma *in Situ*) or Invasive Adenocarcinoma.

We always considered worst histological diagnosis in case of concomitant lesions.

Surgical procedures were carried out in outpatient or inpatient setting under local anesthesia. After application of 5% acetic acid, conization was guided by a colposcope and in case of LEEP using the most adequate loop size according to dimension of the transformation zone. Only four gynaecologists were involved in surgery procedures and a standardized technique was used.

Regarding linear CIN lesion extension analysis, we excluded both squamous and glandular invasive and microinvasive carcinoma.

Descriptive analysis was carried out and the maximum, minimum and mean values for quantitative variables and percentages for qualitative variables. Statistical software SPSS 27 (SPSS Inc®, Chicago, IL, USA) was used for dataset analysis. In order to obtain evenly divided number of conization for trend analysis, time frame was divided in four categories 1992–2003, 2004–2010, 2011–2016, 2017–2020. Chi-square test or Fisher exact test were used for comparing proportions, as appropriate. A *p* value < 0.05 was considered statistically significant. In order to compare trends one-way ANOVA test was used.

This study was approved by internal Ethical committee and conducted according to Helsinki's principles.

Informed consent was obtained from each patient for study participation.

3. Results

Starting from January 1992 through December 2020, 3837 women underwent cervical conization for CIN treatment. 121 patients were excluded because complete histopathological data were missing. A total of 3716 women were included in final analysis.

The distribution during the 28 years considered is: 876 women in 1992–2003, 889 in 2004–2010, 1036 in 2011–2016 and 915 in 2017–2020.

Women mean age was 37 years (SD 9.3 years, range 18.1–77 years). No significant difference regarding mean age at the time of the cone emerged over the whole study period, from mean age of 37.13 years in 1992–2003 to 39.43 years in 2017–2020.

Number of cervical conizations per year increased during study period, starting from 12 in 1992 to 233 conization in 2020, with a maximum of 244 conizations in 2019, as shown in Fig. 1.

LEEP was the most frequent technique, accounting for 95.3% of all treatments, while cold knife conization was performed in 2.7% and radiofrequency needle in 2% of patients. The percentage of cold knife treatment was stable over the study period and did not affect the overall length trend observed in the present study.

A single surgical specimen was retrieved in 71.4% of pa-

Table 1. Histopathological diagnosis on cone specimens.

Diagnosis	N (%)
CIN 1	429 (11.5)
CIN 2	1140 (30.7)
CIN 3	1770 (47.6)
AIS	44 (1.2)
Invasive adenocarcinoma	19 (0.5)
Microinvasive squamous carcinoma	30 (0.8)
Invasive squamous carcinoma	35 (0.9)
Not classifiable	140 (3.8)
Negative	109 (2.9)

tients, while in 21.6% multiple specimens were performed (either a top hat excision for endocervical lesions or a lateral enlargement).

Final histopathologic diagnosis is reported in Table 1: High Grade Squamous Intraepithelial Lesion (encompassing CIN 2 and 3) was found in 78.3% of cervical specimens (2910 women) while CIN1 was reported in 11.5%. Glandular lesions were reported in 63 patients (1.7%), in particular 44 adenocarcinomas *in situ* (AIS, 1.2%) and 19 invasive adenocarcinomas (0.5%). In 2.9% patients (109) no evidence of lesion was found at histopathological diagnosis.

Details on clinical pathological results are reported in Table 2. Dimensions of the cone base were recorded and mean first dimension of the cone base (ectocervix) was 17.5 mm (SD 5.1 mm), mean second dimension 13.7 mm (SD 4.3 mm). Mean area of the cone base was 197.6 mm² (SD 105.8 mm²), while no differences in mean area were found over the study period.

Mean total length of the cone was 9.5 mm (SD 5.1 mm, distribution is shown in Fig. 2 and distribution per year is detailed in Fig. 3) and linear CIN extension was 6.58 mm (SD 3.38 mm, range 1–45 mm).

Fig. 4 presents trend of cone length in the whole study period. A significant decrease in cone length was observed and in particular mean cone length in 2017–2020 (7.81mm, SD 3.85) was significantly lower than in 1992–2003 (12.07 mm, SD 5.62), *p* < 0.001, one-way ANOVA. A 35% reduction in cone length was found when comparing mean length of conization made in first period of analysis (1992–2003) and the most recent (2017–2020).

Mean linear extension of the lesion was 6.58 mm (SD 3.38 mm, range 1–45 mm). From 1992–2003 mean extension was 6.61 mm (SD 3.96 mm) to 2017–2020 6.28 mm (SD 2.98 mm) and no statistically significant reduction was found (Fig. 5).

Margin status was recorded and endocervical margin was positive in 26.5% cases, esocervical margin in 32.4% and deep (lateral) margin 3.5% of cases. No significant trend in margin positivity was observed over the study period.

Endocervical crypt involvement was reported as focal in 53.2% (1977 women), massive in 12.5% (463) and negative in 15.6% (581).

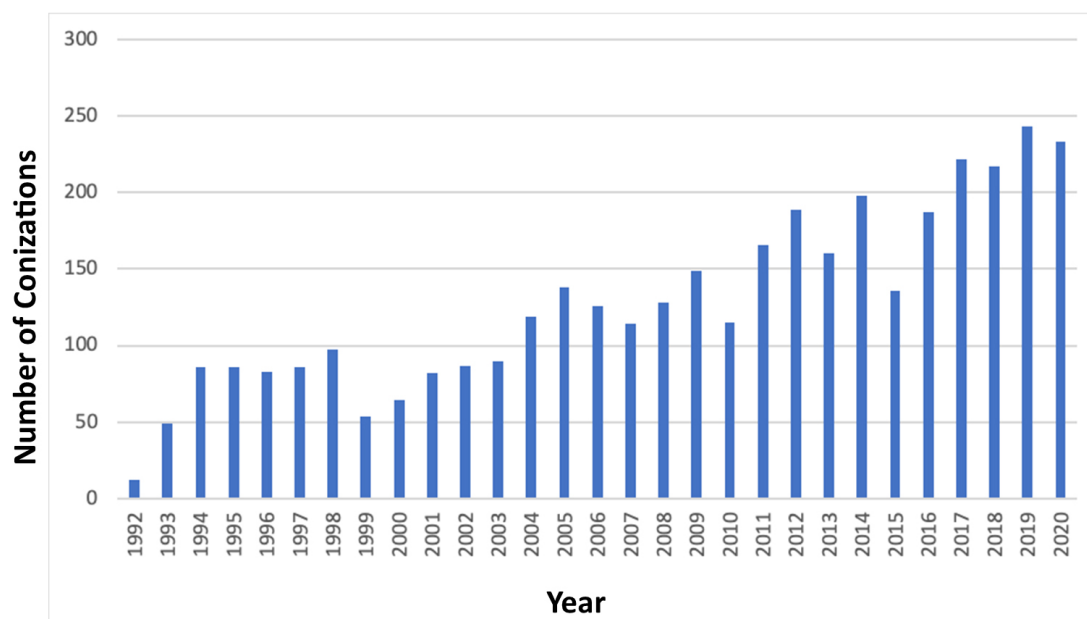


Fig. 1. Distribution of cervical conizations during study period.

Table 2. Trends in mean age, mean cone length, mean cone base area, mean linear lesion extension over the study period.

	1992–2003	2004–2010	2011–2016	2017–2020	<i>p</i>
N° treated patients	876	889	1036	915	NS
Mean age (SD)	37.13 y (10.23)	36.51 y (9.44)	37.57 y (9.34)	39.43 y (9.77)	NS
Mean cone length (SD)	12.07 mm (5.62)	8.86 mm (4.97)	8.94 mm (4.21)	7.81 mm (3.85)	<i>p</i> < 0.001
Mean cone base area (SD)	199.07 mm ² (103.52)	190.35 mm ² (106.54)	210.59 mm ² (114.06)	184.01 mm ² (98.07)	NS
Mean linear lesion extension (SD)	6.61 mm (3.96)	6.05 mm (3.26)	6.79 mm (3.60)	6.28 mm (2.98)	NS
Ectocervical margin positivity	31.5%	32.1%	32.4%	33.5%	NS
Endocervical margin positivity	27.3%	26.6%	25.7%	26.3%	NS

NS, not significant.

4. Discussion

The impact of cervical conization on future obstetric outcomes has been extensively discussed in medical literature and recent metanalysis have demonstrated that surgically treated women are at higher risk of preterm delivery, second-trimester pregnancy loss and other negative outcomes [5, 10].

These adverse effects are thought to be related mainly to cone depth and the alteration of cervical integrity that lead to disruption of a complex anatomical barrier. Removal of a portion of cervix may decrease the tensile strength of collagen, which is important for maintaining pregnancy until term and also destruction of glands may impact mucus production and facilitate migration of vaginal pathogen through membranes [10]. There is uncertainty about the exact pathogenic mechanism of cervical disruption: this could be linked to destruction of epithelial cervical reserve cells and stromal repair cells, that are responsible of regeneration process [11, 12]. Thus, greater cervical cone dimension implies increased destruction of reserve cells and impaired regeneration increasing the risk of adverse obstetrics outcomes.

Our study showed a significant reduction in cervical cone

length from 1992 through 2020 in a referral tertiary center. A 35% reduction in mean cone length from 1992 through 2020, from 12.07 mm to 7.81 mm was reported, possibly indicating a more precise and conservative approach towards CIN treatment. This finding is in agreement with published data, as Ciavattini [6] reported a significant decrease in length of cone excision from 14 mm in 2006 to 12.3 in 2014. Also Sopracordevole [7] outlined a 30% reduction in length of cone specimen from 1996 to 2015.

In our cohort, length reduction did not lead to increased rates of margin positivity, as ectocervical and endocervical margin positivity rates were unaffected by decreasing cone length.

On the other hand, no significant reduction in CIN lesion linear extension was found over the study period.

Data regarding obstetric history from our series were not available and in particular regarding abortion rates and preterm deliveries, so that it is impossible to correlate our finding with immediate beneficial effects on reproductive health. A study from our department of Obstetrics and Gynaecology, even if from another unit, found that exci-

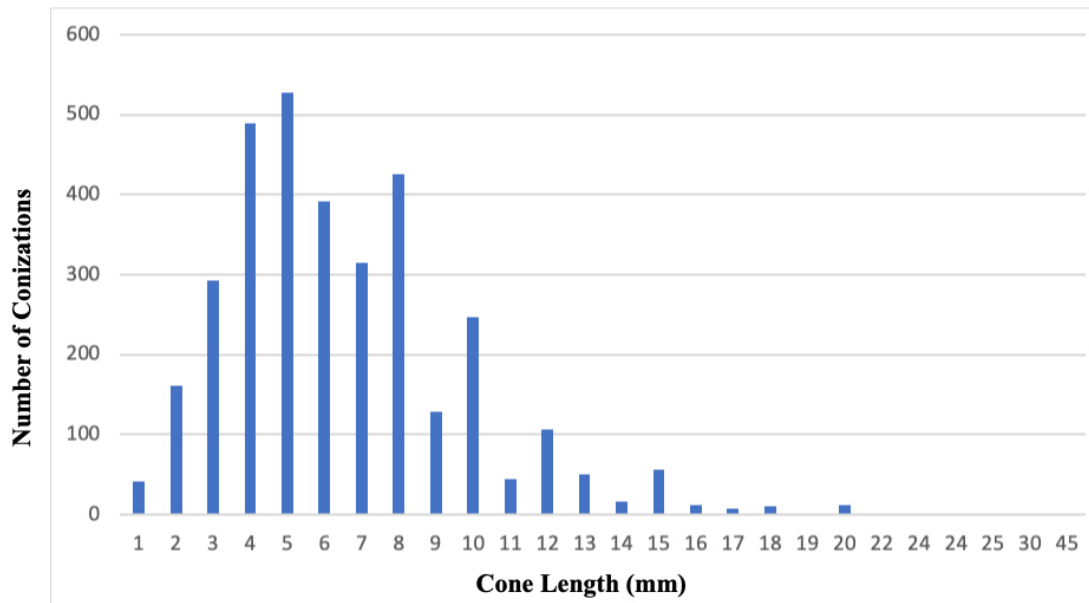


Fig. 2. Cone length distribution in mm.

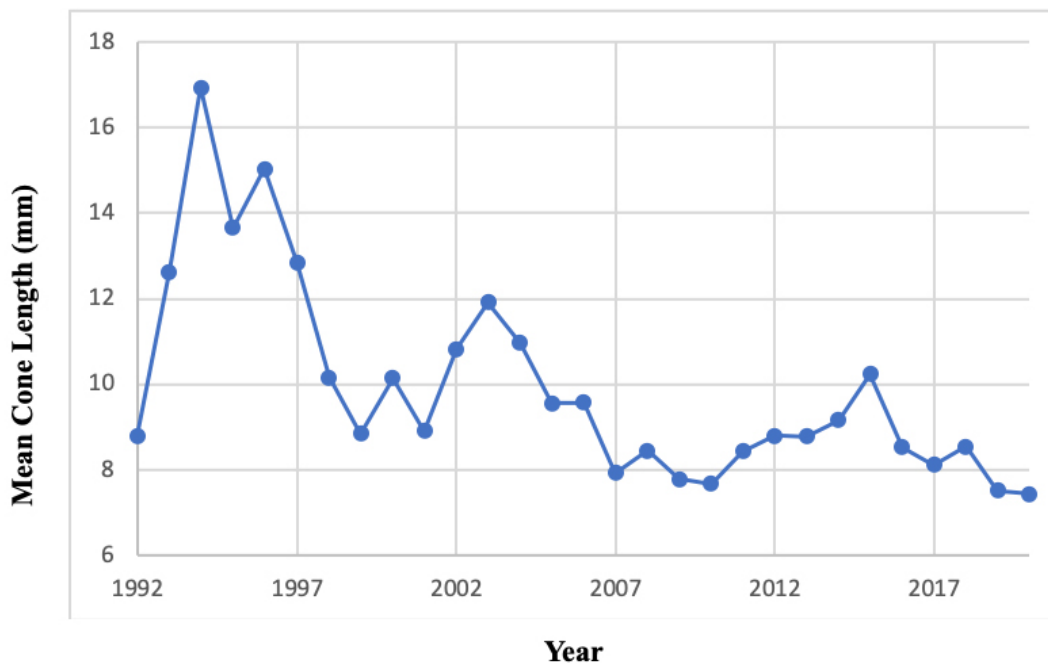


Fig. 3. Length of cone excision per year of procedure, expressed in mm.

sional treatment of CIN significantly increases Premature Rupture of Membranes (PROM) (40% vs 23.22%, $p < 0.0001$) and Preterm Premature Rupture of Membranes (pPROM, 13.13% vs 2.71% $p < 0.0001$) risk [13]. Also dystocic deliveries were more frequent in treated women (18.75% vs 4.48% $p < 0.0001$). A recent review and meta-analysis by Kirgiou [5] reported that cone depth of treatment was found as a statistically significant factor for preterm birth, as it is increased for excision exceeding 14 mm in depth. Risk for preterm delivery was 1.54 higher for cone length < 10 – 12 mm, and it rises to 4.91 if > 20 mm.

As negative obstetric outcomes were reported more frequently in cone depth > 14 mm, we underline the reduced percentage of cone > 14 mm from 45.6% in 1992–2003 to only 8.79% in 2017–2020.

An increased attention to obstetric outcomes [6, 7] may have led to decreasing cone length trend in our case series. Furthermore, the use of colposcopy-guided conization could have allowed more precise excision of CIN lesion and less excised tissue compared to free-hand surgery.

Further studies should also assess whether less invasive and conservative surgical procedures will lead to favorable

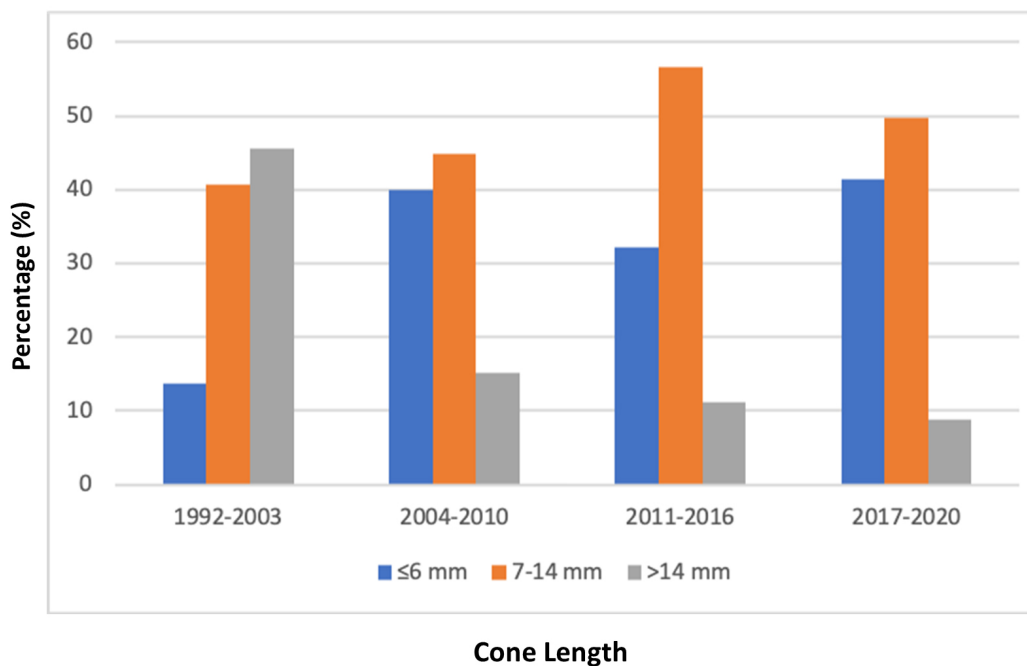


Fig. 4. Trend of cone length over the study period, expressed as percentage.

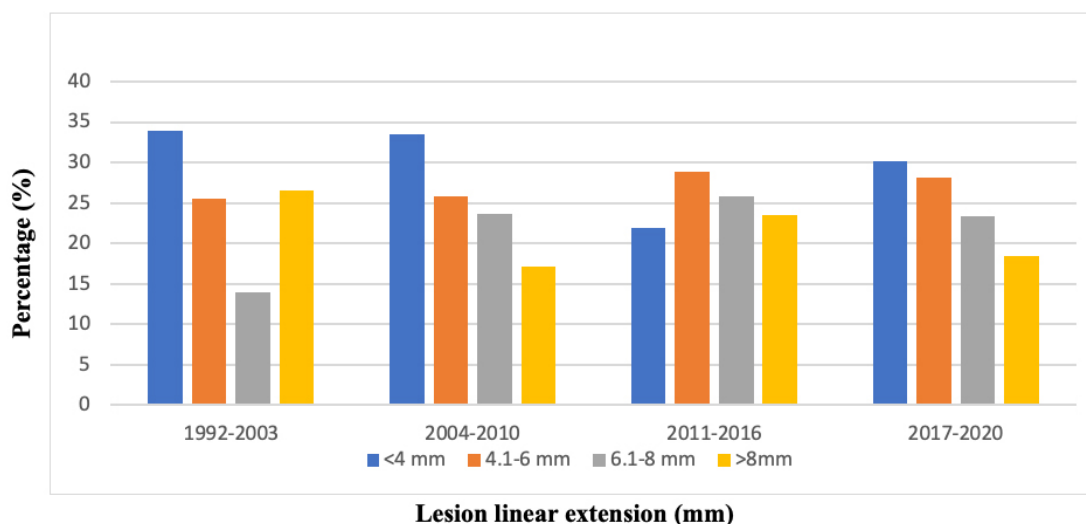


Fig. 5. Trend of linear CIN extension over the study period, expressed as percentage.

oncological outcomes. A study by Lara-Penaranda showed that conization height smaller than 10 mm did not affect disease persistence or HPV infection in 18 months follow up, even if a small number of participants was included in the study [14]. We did not observe any increase in margin positivity in our series, but longer follow up and further studies are needed to analyze long term risk of recurrence and progression to carcinoma.

The main strong point of this study is high number of patients involved from a single institution over 28 years and the same surgical method used in more than 95% of cases. In addition, the limited number of gynecologists involved may re-

duce the risk of potential bias in data collection and analysis.

However, the retrospective nature of the present study has some limitations. It has been possible to retrieve clinical data already recorded in medical charts, but there have been missed information regarding future obstetrical outcomes (such as abortion rates and preterm delivery) of patients included in the study.

5. Conclusions

In conclusion, our study reported a significant trend of reduction in mean cone length from 1992 to 2020, possibly reflecting increased attention on preserving future obstetric

outcomes. Also, ectocervical and endocervical margins positivity rates were unaffected by decreasing cone length. On the other hand, no significant reduction trend in CIN linear lesion extension was observed during study period. Further studies are needed to assess the impact of this reduction on margin status and future oncological outcomes.

Author contributions

MP, LM, CB designed the research study. MP and NG performed the research. MP, NG, FB wrote the manuscript. GP revised the manuscript. All authors read and approved the final manuscript.

Ethics approval and consent to participate

All subjects gave their informed consent for inclusion before they participated in the study. The study was conducted in accordance with the Declaration of Helsinki, and the protocol was approved by the Ethics Committee of Città della Salute e della Scienza di Torino (approval number: 2017/1512).

Acknowledgment

The authors express their gratitude to the staff of histopathological unit of University of Torino for their precious contribution.

Funding

This research received no external funding.

Conflict of interest

The authors declare no conflict of interest.

References

- [1] Arbyn M, Raifu AO, Weiderpass E, Bray F, Anttila A. Trends of cervical cancer mortality in the member states of the European Union. *European Journal of Cancer*. 2009; 45: 2640–2648.
- [2] Bucchi L, Baldacchini F, Mancini S, Ravaioli A, Giuliani O, Vattiato R, *et al*. Estimating the impact of an organised screening programme on cervical cancer incidence: a 26-year study from northern Italy. *International Journal of Cancer*. 2018; 144: 1017–1026.
- [3] Bucchi L, Mancini S, Baldacchini F, Giuliani O, Ravaioli A, Vattiato R, *et al*. Changes in the incidence of cervical tumours by disease stage in a cytology-based screening programme. *Journal of Medical Screening*. 2020; 27: 96–104.
- [4] Melnikow J, McGahan C, Sawaya GF, Ehlen T, Coldman A. Cervical Intraepithelial Neoplasia Outcomes after Treatment: Long-term Follow-up from the British Columbia Cohort Study. *Journal of the National Cancer Institute*. 2009; 101: 721–728.
- [5] Kyrgiou M, Athanasiou A, Paraskevaidi M, Mitra A, Kalliala I, Martin-Hirsch P, *et al*. Adverse obstetric outcomes after local treatment for cervical preinvasive and early invasive disease according to cone depth: systematic review and meta-analysis. *British Medical Journal*. 2016; 354: i3633.
- [6] Ciavattini A, Clemente N, Liverani CA, Cattani P, Giannella L, Delli Carpini G, *et al*. Cervical Excision Procedure: a Trend of Decreasing Length of Excision Observed in a Multicenter Survey. *Journal of Lower Genital Tract Disease*. 2017; 21: 279–283.
- [7] Sopracordevole F, Clemente N, Delli Carpini G, Giorda G, Del Fabro A, Moriconi L, *et al*. Trend of decreasing length of cervical cone excision during the last 20 years. *European Review for Medical and Pharmacological Sciences*. 2017; 21: 4747–4754.
- [8] Liverani CA, Di Giuseppe J, Clemente N, Delli Carpini G, Monti E, Fanetti F, *et al*. Length but not transverse diameter of the excision specimen for high-grade cervical intraepithelial neoplasia (CIN 2–3) is a predictor of pregnancy outcome. *European Journal of Cancer Prevention*. 2016; 25: 416–422.
- [9] Kurman R, Carcangiu ML, Herrington CS, Young YR. WHO classification of tumors of female reproductive organs. *World Health Organization Classification of Tumors*. Lyon: International Agency for Research on Cancer. 2014.
- [10] Phadnis SV, Atilade A, Bowring J, Kyrgiou M, Young MPA, Evans H, *et al*. Regeneration of cervix after excisional treatment for cervical intraepithelial neoplasia: a study of collagen distribution. *BJOG: an International Journal of Obstetrics and Gynaecology*. 2011; 118: 1585–1591.
- [11] Martens JE, Smedts FMM, Ploeger D, Helmerhorst TJM, Ramaekers FCS, Arends JW, *et al*. Distribution pattern and marker profile show two subpopulations of reserve cells in the endocervical canal. *International Journal of Gynecological Pathology*. 2009; 28: 381–388.
- [12] Ueki M, Ueda M, Kurokawa A, Morikawa M, Kusakabe T. Cytologic study of the tissue repair cells of the uterine cervix. with special reference to their origin. *Acta Cytologica*. 1992; 36: 310–318.
- [13] Maina G, Ribaldone R, Danese S, Lombardo V, Cavagnetto C, Plazzotta C, *et al*. Obstetric outcomes in patients who have undergone excisional treatment for high-grade cervical squamous intraepithelial neoplasia. *European Journal of Obstetrics, Gynecology, and Reproductive Biology*. 2019; 236: 210–213.
- [14] Lara-Peñaranda R, Rodríguez-López PM, Plitt-Stevens J, Ortiz-González A, Remezal-Solano M, Martínez-Cendán JP. Does the trend toward less deep excisions in LLETZ to minimize obstetric risk lead to less favorable oncological outcomes? *International Journal of Gynecology & Obstetrics*. 2020; 148: 316–324.