

Two cases of uterus-conserving treatment for early stage endometrial cancer

Y.-S. Kwon¹, K. S. Im², S. B. Yoo², W. I. Kim²

¹Department of Obstetrics and Gynecology, Nowon Eulji Medical Center, Eulji University, Seoul

²Department of Anesthesiology and Pain Medicine, Uijeongbu St Mary's Hospital, College of Medicine, Catholic University of Korea, Seoul (Korea)

Summary

The aim of study is to present two successful cases of conservative surgical treatment of women with early-stage endometrial cancer who desired to have fertility in the two cases. A 32-year-old nulligravid woman had Stage IA endometrial cancer which was a 1.5-cm sized lesion confined to the left fundal side of the uterus. The other 35-year-old nulligravid woman had a 2-cm sized lesion suspicious for deep myometrial involvement suggesting Stage IB endometrial cancer. The women underwent hysteroscopic complete resection of tumor with safe resection margin just after laparoscopic tubal ligation, followed by insertion of a progesterone-releasing intrauterine device. The patients have no evidence of recurrence for 26 months and 27 months of follow-up, respectively. Hysteroscopic complete resection of tumor with safe margin combined with bilateral tubal ligation, followed by a progesterone-releasing intrauterine device could be a good option for early-stage endometrial cancer.

Key words: Endometrial cancer; Hysteroscopy; Laparoscopy; Tubal ligation.

Introduction

Endometrial cancer is the fourth most common cancer in women, with a prevalence rate of 23.5 per 100,000 [1]. Among the women who have endometrial cancer, 25% are premenopausal and 14.4-25% are under 40 years of age at diagnosis [2]. Conventional treatment of early-stage endometrial cancer is total abdominal hysterectomy and bilateral salpingo-oophorectomy with lymph node assessment. However, in young patients who desire future fertility, conservative management could be considered. There are no consensus guidelines on conservative treatment of early-stage endometrial cancer. There are some studies on medical treatment and surgical treatment or a combination of both, but only a few reports have been published and there is no comparative study. The most commonly used surgical technique for preserving the uterus is hysteroscopic resection. However, intraperitoneal seeding of cancer should be considered when using a hysteroscope [3]. The authors describe two cases in which a uterus-conserving surgical approach was used for treating early-stage endometrial cancer, along with laparoscopic bilateral tubal ligation to prevent intraperitoneal dissemination during hysteroscopic resection, followed by insertion of a progesterone-releasing intrauterine device.

Case Report

Case 1

A 32-year-old nulligravid was referred to the present hospital for further evaluation and treatment of pathologically confirmed endometrial adenocarcinoma FIGO (International Federation of Gynecology and Obstetrics), endometrioid type grade 1. Initial ultrasound showed anteverted normal-sized uterus with a 1.9×1.3-cm hyperechoic thickened lesion in the left fundal wall. MRI suggested TNM Stage T1a endometrial cancer which was a 1.5-cm lesion confined to the left fundal side of the uterus without myometrial invasion without metastatic lymph node (Figure 1a). She had married a year ago; hence, she wanted to preserve her fertility. The patient was informed about the risk of recurrence, residual cancer and future fertility, and after receiving this information, she gave consent to hysteroscopic resection after laparoscopic bilateral tubal ligation. The authors explained to the patient that conception should be attempted through in vitro fertilization.

The patient underwent laparoscopic tubal ligation with clips without an evidence of peritoneal extrauterine disease. After that,

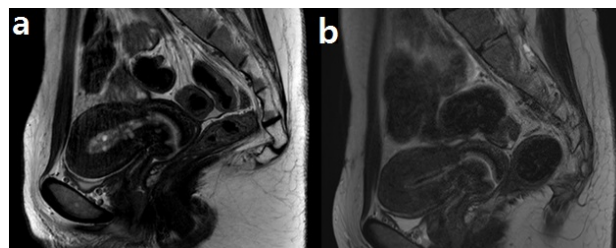


Figure 1. — T2-weighted MRI at the time of diagnosis and three months after the treatment. (a) Sagittal view of preoperative MRI at the time of diagnosis. (b) Sagittal view of postoperative MRI, three months after the surgery.

Published: 15 February 2020

Eur. J. Gynaecol. Oncol. - ISSN: 0392-2936
XLI, n. 1, 2020
doi: 10.31083/j.ejgo.2020.01.4863

©2020 Kwon et al.
Published by IMR Press

This is an open access article under the CC BY-NC 4.0 license
<https://creativecommons.org/licenses/by-nc/4.0/>.

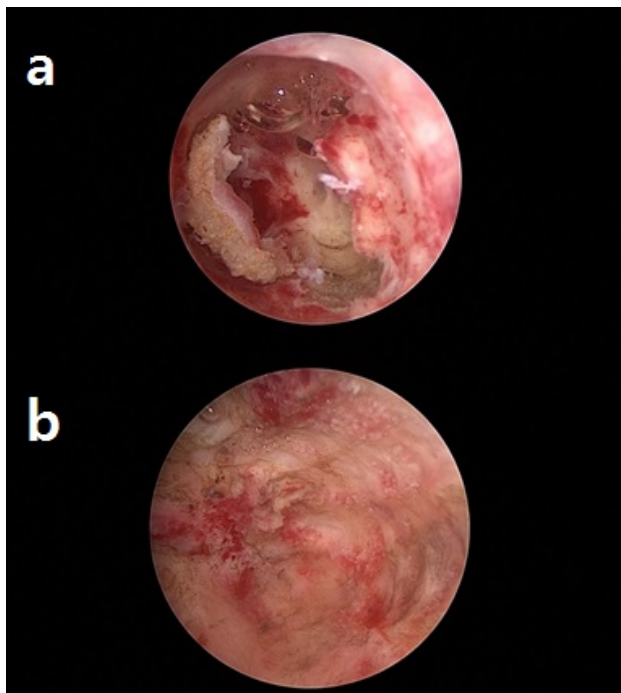


Figure 2. — Hysteroscopic images of uterine cavity. (a) Before hysteroscopic resection. (b) After hysteroscopic resection.

hysteroscopic resection was performed using a 26F unipolar resectoscope with a 24F loop electrode (Figures 2a, b). The lesion was resected and during surgery, all fragments for frozen tissue slides were sent to the pathology department to assess involvement of the resection margin or myometrial invasion. A resectoscopic approach was performed three times until a clear resection margin was confirmed by a pathologist. The lesion and the surrounding endometrium including myometrium were completely resected. Excluding the resected lesion, the other side of the endometrial tissue was saved for preserving the implantation capacity. Then, a levonorgestrel-releasing uterine device was inserted into the uterus.

MRI was performed at three months after the surgery and there was no evidence of cancer (Figure 1b). Six months after surgery, the endometrium was clear on ultrasonography and the pathological report of endometrial aspiration biopsy revealed an atrophic endometrial gland suggestive of the exogenous progestin effect without hyperplasia or malignancy. The intrauterine device was kept in place for one year and then removed. Six months after removal of LNG-IUS, follow-up biopsy showed a mixture of inactive and secretory glands negative for malignancy. The patient was referred to the infertility and sterility department. The patient achieved pregnancy by in vitro fertilization, four months after the surgery and she delivered a male, 3,140 grams at 39 weeks of gestation without complication, such as uterine rupture or placenta accreta.

Case 2

A 35-year-old obese nulligravid woman was referred from a local clinic after endometrial biopsy confirmed endometrial adenocarcinoma FIGO endometrioid type grade 2 to 3. Her BMI was 37.47 kg/m² and she had type 2 diabetes requiring metformin and insulin. On the MRI image, there was a 2-cm soft tissue lesion con-

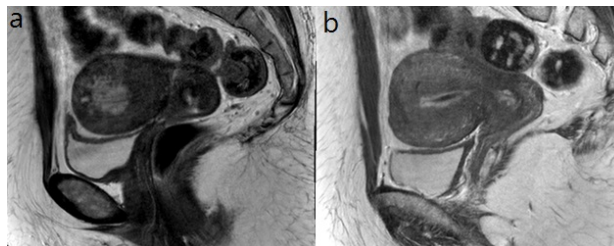


Figure 3. — T2-weighted MRI at the time of diagnosis and three months after treatment. (a) Sagittal view of preoperative MRI at the time of diagnosis. (b) Sagittal view of postoperative MRI, three months after the surgery.

ned to the left fundal myometrium suspicious for deep myometrial involvement suggesting TNM Stage T1b endometrial cancer without metastatic lymph node (Figure 3a). Because she had a strong desire to preserve her uterus, the authors planned hysteroscopic resection with laparoscopic tubal ligation. The patient agreed regarding the risk of residual malignancy, future subfertility, and need for in vitro fertilization. The patient underwent hysteroscopic resection using a 26F unipolar resectoscope with a 24F loop electrode just after bilateral tubal ligation with clips. Because the initially obtained frozen section showed myometrial invasion, the endometrium was resected further. No cancerous lesion was found in the second fragment. A levonorgestrel-releasing uterine device was inserted after surgery. The adjuvant six cycles of chemotherapy with cyclophosphamide, adriamycin, and cisplatin (CAP) was planned initially due to invasion of more than half of the myometrium; however, the patient received four cycles of postoperative chemotherapy and then refused further chemotherapy due to her severe depression. Before the third cycle of chemotherapy, MRI and endometrial biopsy showed no evidence of malignancy (Figure 3b). In the pathologic report of endometrial curettage biopsy, there was decidualized tissue without malignancy at one year on endometrial biopsy. The levonorgestrel-releasing uterine device was maintained considering the patient's desire for contraception. The patient has no evidence of recurrence for 27 months of follow-up.

Discussion

Endometrial cancer has two pathologic types, type I and type II. Type I is a low-grade, slow-growing cancer with a background of endometrial hyperplasia. It occurs frequently in younger women who have certain risk factors for endometrial hyperplasia, which are obesity, type 2 diabetes, and chronic anovulation like polycystic ovary syndrome (PCOS), or in postmenopausal women with unopposed estrogen exposure. Recently young women with desire of a baby have been exposure increasingly to these risks factor.

Conservative treatment strategy is required in the young women with the desire of child-bearing. However, there is no standard guideline in conservative treatment of early-stage endometrial carcinoma. There are numerous studies assessing the efficacy of different types of progestins like medroxyprogesterone acetate, vaginal micronized progesterone, megestrol acetate, and levonorgestrel-releasing intrauterine device, but the results are limited in determining

the effective treatment for endometrial cancer. A meta-analysis by Gallos *et al.* [4] reported a relapse rate of endometrial cancer of 40.6%. Currently, there is no evidence from randomized controlled trials of progestin treatment that proves a pathological complete response. Therefore, a surgical approach is required to eliminate the cancerous lesion as much as possible. Hysteroscopic resection could be the choice in regional resection of the endometrium. Hysteroscopic resection is indicated only for focal lesions; hence, it is important to obtain correct imaging information in order to make a decision about excising the lesion completely and preserving a normal endometrium. For sufficiently determining complete resection, the specimen was sent to the pathologist for frozen slide evaluation to confirm a negative resection margin during the operation. This surgical approach aims to maximally resect the cancerous lesion and to preserve the uninvaded endometrium available for implantation without spillage of cancer during hysteroscopic procedure. A meta-analysis of hysteroscopy and cancer cell dissemination suggests that hysteroscopy in patients with endometrial cancer results in a statistically significantly higher incidence of endometrial cancer cell seeding within the peritoneal cavity [3]. Laparoscopic proximal tubal ligation can prevent peritoneal spread of cancer cells as much as possible, although it is still controversial whether cancer cells grow after seeding. Moreover, laparoscopic examination is possible if there is a lesion suggestive of extrauterine disease, including peritoneal cytology.

The important aspect is thorough explanation of risks and benefits of fertility-preserving treatment with informed consent for procedures including in vitro fertilization from patient who desire a conservative treatment of endometrial cancer. Also, a patient needs to consult a fertility specialist before and after the surgery so that she can be informed about the risk factors for endometrial cancer (chronic anovulation, obesity, diabetes, and PCOS) are related to subfertility. In the second case, the patient received chemotherapy due to deep myometrial invasion. Before chemotherapy, oocyte, embryo or ovarian tissue cryopreservation can be considered. Even when choosing a chemotherapeutic agent, deliberate consideration of ovarian dysfunction is recommended [5].

After hysteroscopic resection to conserve the uterus, post-operative progestin therapy is considered to prevent relapse and to treat premalignant endometrial hyperplasia [6, 7]. Although there is no comparative study of progestin therapies for conservative treatment of endometrial cancer, there are a few reports which suggest that regression and relapse rates of levonorgestrel-releasing intrauterine device were comparable with those of oral progestins in case of endometrial hyperplasia [8, 9]. In the present two cases, a levonorgestrel-releasing intrauterine device was inserted after surgery because it can achieve better compliance than oral or injective progestins, and it produces a higher level of progesterone than other systemic progestins at a dose of 20 µg daily. In addition, levonorgestrel-releasing intrauterine device acts

directly on the endometrium; hence, systemic side effects are less than that of systemic progestins. As shown in the present two cases, endometrial pipelle biopsy can be performed without removing the device during the surveillance period.

Before hysteroscopic operation, deliberate consultation for fertility preservation should be accompanied by counseling regarding the prognosis of endometrial cancer. If the patient desires to preserve fertility, hysteroscopic resection combined with bilateral tubal ligation, followed by insertion of a progesterone-releasing intrauterine device can be a good option for early-stage endometrial cancer. However, in order to establish the guidelines for fertility-preserving treatment of endometrial cancer, further study with a larger number of patients is needed.

References

- [1] Baker J., Obermair A., GebSKI V., Janda M.: "Efficacy of oral or intrauterine device-delivered progestin in patients with complex endometrial hyperplasia with atypia or early endometrial adenocarcinoma: a meta-analysis and systematic review of the literature". *Gynecol. Oncol.*, 2012, 125, 263.
- [2] Gadducci A., Spirito N., Baroni E., Tana R., Genazzani A.R.: "The fertility-sparing treatment in patients with endometrial atypical hyperplasia and early endometrial cancer: a debated therapeutic option". *Gynecol. Endocrinol.*, 2009, 25, 683.
- [3] Polyzos N.P., Mauri D., Tsioras S., Messini C.I., Valachis A., Messinis I.E.: "Intraperitoneal dissemination of endometrial cancer cells after hysteroscopy: a systematic review and meta-analysis". *Int. J. Gynecol. Cancer.*, 2010, 20, 261.
- [4] Gallos I.D., Yap J., Rajkhowa M., Luesley D.M., Coomarasamy A., Gupta J.K.: "Regression, relapse, and live birth rates with fertility-sparing therapy for endometrial cancer and atypical complex endometrial hyperplasia: a systematic review and metaanalysis". *Am. J. Obstet. Gynecol.*, 2012, 207, 266.
- [5] Gracia C.R., Sammel M.D., Freeman E., Prewitt M., Carlson C., Ray A., *et al.*: "Impact of cancer therapies on ovarian reserve". *Fertil. Steril.*, 2012, 97, 134.
- [6] Laurelli G., Di Vagno G., Scaffa C., Losito S., Del Giudice M., Greggi S.: "Conservative treatment of early endometrial cancer: preliminary results of a pilot study". *Gynecol. Oncol.*, 2011, 120, 43.
- [7] Mazzon I., Corrado G., Masciullo V., Morriconi D., Ferrandina G., Scambia G.: "Conservative surgical management of stage IA endometrial carcinoma for fertility preservation". *Fertil. Steril.*, 2010, 93, 1286.
- [8] Gallos I.D., Krishan P., Shehmar M., Ganesan R., Gupta J.K.: "LNG-IUS versus oral progestogen treatment for endometrial hyperplasia: a long-term comparative cohort study". *Hum. Reprod.*, 2013, 28, 2966.
- [9] Orbo A., Vereide A., Arnes M., Pettersen I., Straume B.: "Levonorgestrel-impregnated intrauterine device as treatment for endometrial hyperplasia: a national multicentre randomised trial". *BJOG*, 2014, 121, 477.

Corresponding Author:

KYONG SHIL IM, M.D.

Department of Anesthesiology and Pain Medicine
Uijeongbu St Mary's Hospital, College of Medicine
The Catholic University of Korea
271 Cheonbo-ro, Uijeongbu-si
Gyeonggi-do 480-717 (Republic of Korea)
e-mail: idonga@catholic.ac.kr