

Eliminating tumor cell entrapment from the natural history of ovarian cancer, a narrative summary

Paul H. Sugarbaker^{1,*}

¹Washington Cancer Institute, Program in Peritoneal Surface Malignancy, Washington, DC 20007, USA

*Correspondence: Paul.Sugarbaker@outlook.com (Paul H. Sugarbaker)

DOI: [10.31083/j.ejgo4204096](https://doi.org/10.31083/j.ejgo4204096)

This is an open access article under the CC BY 4.0 license (<https://creativecommons.org/licenses/by/4.0/>).

Submitted: 29 March 2021 Revised: 27 April 2021 Accepted: 29 April 2021 Published: 15 August 2021

Objective: The surgery performed on patients with abdominal or pelvic malignancy has a profound effect on the natural history of that disease process. In this manuscript we examine the impact of hysterectomy performed in patients with ovarian cancer. **Methods:** Two assessment tools were reviewed to quantitate the changes induced by hysterectomy on the patterns of recurrence. The prior surgical score (PSS) correlates the survival of patients with the extent of surgery that was performed prior to cytoreductive surgery (CRS). Also, an assessment of anatomic sites of disease documented at the time of CRS for recurrent ovarian cancer determined the extent of tumor cell entrapment (TCE) at sites of surgical trauma. **Results:** Patients with recurrence of ovarian malignancy who had a CRS plus hyperthermic intraperitoneal chemotherapy (HIPEC) showed a statistically significant reduced survival if they had a high PSS. The data from TCE assessment showed that the sites of surgical trauma that occurred with hysterectomy performed for treatment of the primary ovarian cancer was associated with disease within the abdominal incision, laparoscopy port sites, and the resection site for hysterectomy. **Conclusions:** Hysterectomy performed in patients with stage 3 ovarian malignancy who have large numbers of free cancer cells within the abdominal and pelvic space had a profound effect upon the natural history of this malignancy as determined by PSS and an assessment of anatomic sites of TCE. HIPEC was suggested as a treatment to reduce the reimplantation of cancer cells at sites of surgical trauma following hysterectomy.

Keywords

Cytoreductive surgery; Hysterectomy; Cisplatin; Paclitaxel; HIPEC; EPIC; Prior surgical score; Peritoneal metastases; Regional chemotherapy

1. Introduction

Ovarian cancer is the seventh most common cancer in the world and the leading cause of death from gynecologic malignancy in the United States and Europe [1]. The highest incidence of disease is in Caucasian women in the United States and Northern part of Europe [2]. In 90% of patients the histologic type is epithelial ovarian cancer. The most aggressive epithelial ovarian cancer is the serous carcinoma present in 70% of patients. In a great majority of patients (80%), patients have peritoneal metastases at the time of first diagnosis [3]. The initial management of most patients concerns the treatment of the peritoneal dissemination.

In order to knowledgeable plan a treatment for ovarian cancer the oncologist must understand the natural history of this disease. A brief summary of the progression of a FIGO (The International Federation of Gynecology and Obstetrics) stage 3 ovarian cancer is as follows: After cancer cells from the Fallopian tube leave the fimbriated end of the Fallopian tube they implant on the surface of the ovary. Those transformed cells that fail to stick to the surface of the ovary may find other places within the abdomen or pelvis to progress [4]. This focus of cancer on the surface of the ovary can now progress with its blood supply coming from the ovarian parenchyma. As the cancer implant progresses an ovarian mass forms. The epithelial cells from this mass are free to metastasize to the parietal and visceral peritoneal surfaces [5, 6]. The distribution of ovarian cancer cells initially follows the flow of peritoneal fluid up the right paracolic sulcus to the right retrohepatic space and undersurface of the right hemidiaphragm [7]. The flow of fluid is largely in a clockwise direction. Cells free in the peritoneal space are phagocytized by the immune cells in the greater and lesser omentum. Cells from the cancerous ovary also frequently implant on the opposite ovary. By gravity, cancer cells drop into the pelvis and progress on parietal pelvic peritoneum and visceral peritoneum of the rectosigmoid colon [8].

Unfortunately, it is late in the natural history of ovarian cancer when symptoms of abdominal pain, abdominal fullness from ascites, constipation, and urinary frequency from bladder compression are first reported by the patient. Because the symptoms are non-specific, they are often ignored for several months prior to seeking medical attention. In a great majority of ovarian cancer patients, it is late in the natural history of the disease that the gynecologic surgeon is asked to perform a resection in order to initiate potentially curative treatments. The surgery is almost without exception hysterectomy and bilateral salpingo-oophorectomy. This surgery does establish the disease process and provide valuable staging information. However, a major question seldom asked in women with ovarian cancer, "Does the hysterectomy have a positive or negative effect on the outcome of the complete treatment strategy?" The surgery has become an intrinsic part of the natural history of ovarian cancer.

1.1 What is tumor cell entrapment (TCE)?

Cancer cells can find access to the peritoneal spaces prior to or at the time of an ovarian cancer resection. If the abdomen and pelvis is not known to be contaminated by cancer cells, great care must be taken to prevent spillage with the trauma of cancer resection. Cancers at the extreme ends of the abdominal and pelvic cavity, for example gastric cancer and rectal cancer, are at great risk for this type of neoplastic contamination of the peritoneal spaces by the trauma of surgery [9]. Likewise, for the unusual ovarian cancer diagnosed prior to peritoneal seeding, great care must be taken to prevent the spillage of malignant cells. For the great majority of ovarian cancer patients, the abdominal and pelvic spaces are teeming with cancer cells and implants are already established on peritoneal surfaces as peritoneal metastases. For the great majority of ovarian cancers, the problem with surgery is not so much spillage as it is entrapment. What happens to the peritoneal metastases as a result of hysterectomy and bilateral salpingo-oophorectomy?

The extensive surfaces within the peritoneal space (and also within the bloodstream) can be categorized as metastatically efficient or inefficient. There are definitely preferential sites for cancer cells to adhere, become vascularized and grow into visible nodules of metastatic cancer. It is well documented that sites of surgical trauma are highly metastatically efficient [10]. The traumatized anatomic site presents a “sticky surface” for the free cancer cell floating within the peritoneal fluid or within vascular channels. Accumulation of cancer cells at surgically traumatized cancer sites is tumor cell entrapment (TCE) [11].

Fares *et al.* [12] reviewed the principles of hematogenous metastases. Free floating cancer cells within the bloodstream or within the coelomic spaces must settle at a particular anatomic site and then colonize. There are specific requirements of the cancer cell and the microenvironment in which the adherence occurs for the metastatic process to be successful.

In a series of reports on intraperitoneal immunotherapy in the experimental animal, Eggermont and coworkers found that a wounded site was a favored site for tumor progression. Tumor growth was always greatest within sites of surgical trauma. These investigators concluded that there was an enhanced local-region tumor progression as a result of a laparotomy [13]. More recently, Ceelen and coworkers have studied the microenvironment of the sites for cancer cell adherence and then progression to a vascularized implant [14].

1.2 How has tumor cell entrapment (TCE) been demonstrated in ovarian cancer?

It has been assumed the hysterectomy and bilateral salpingo-oophorectomy plus partial greater omentectomy is always a beneficial treatment of FIGO stage III ovarian cancer patients. It provides a firm diagnosis and provides valuable staging information. However, as part of the natural history of the disease and its continued progression within the abdomen and pelvis, is this intervention consistently of benefit

for long-term survival? The prior surgical score (PSS) gives us valuable information concerning the effects of surgery on the natural history of an abdominal or pelvic cancer [15]. The PSS is an assessment of the extent of dissection and resection that has occurred in the past. It is quantitated within 9 abdominal-pelvic regions (Fig. 1). A PSS of 0 indicates that prior interventions were limited to percutaneous biopsy or laparoscopy. A PSS of 1 indicates a single region was dissected, as in an oophorectomy or a limited exploratory laparotomy. A PSS of 2 indicates that 2–5 regions have been dissected, as in a hysterectomy and bilateral salpingo-oophorectomy and partial greater omentectomy. A PSS of 3 indicates over 5 of the 9 regions were dissected. A PSS of 3 indicates a prior cytoreductive or debulking procedure.

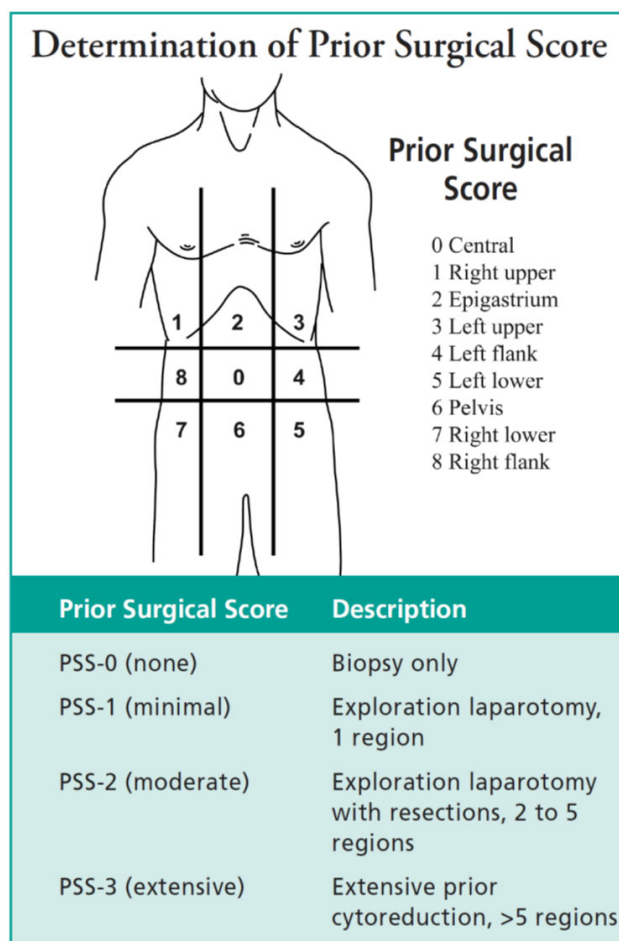


Fig. 1. Abdominopelvic regions used to determine the prior surgical score (PSS). Two transverse planes and two sagittal planes are used to divide the abdomen into 9 abdominopelvic regions (AR-0 through AR-8). The upper transverse plane is located at the lowest aspect of the costal margin. The lower transverse plane is placed at the anterior superior iliac spine. The sagittal planes divide the abdomen into three equal sectors. These lines define 9 regions, which are numbered in a clockwise direction with 0 at the umbilicus and 1 defining the space beneath the right hemidiaphragm (From reference [15] with permission).

Look and coworkers determined the impact of PSS on the survival of patients undergoing reoperative surgery for ovarian cancer [16]. These data regarding PSS were recorded on 28 patients having a cytoreductive surgery for recurrent ovarian cancer. Ten patients had a PSS of 0 or 1 and 18 had a score of 2 or 3. The survival was markedly reduced in patients having the high PSS ($p < 0.001$). These data suggested that something about the natural history of ovarian cancer had changed as a result of the extensive prior surgery. The extensive prior surgery made a favorable result with a reoperation much less likely (Fig. 2, Ref. [16]).

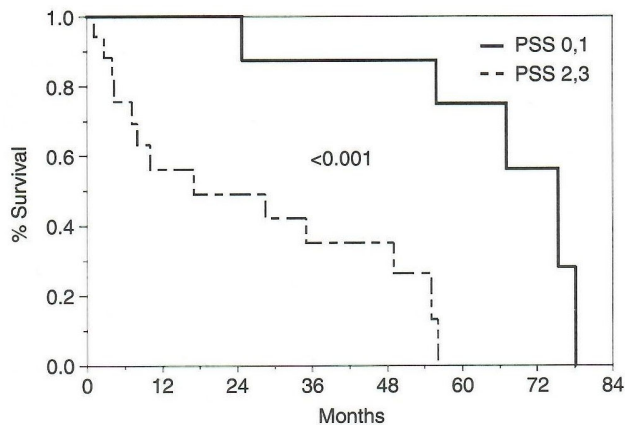


Fig. 2. Survival of 28 patients having cytoreductive surgery and hyperthermic intraperitoneal chemotherapy for recurrent ovarian cancer by prior surgical score (From reference [16] with permission).

In order to further investigate the impact of hysterectomy on the patterns of spread of ovarian cancer, we prospectively catalogued the anatomic sites of ovarian cancer at the time of cytoreduction for recurrent disease [17]. There were 20 patients all of whom had a hysterectomy and bilateral salpingo-oophorectomy. Most also had a partial greater omentectomy and limited para-aortic and pelvic lymph node dissection. Disease encountered at the time of reoperative surgery was prospectively scored in 23 different anatomic sites. As might be expected, the most common site for recurrent/progressive ovarian cancer was the undersurface of the right hemidiaphragm (70%). Next most common site was residual disease in the greater omentum, usually around the spleen and supplied by the short gastric vessels (65%). The abdominal incision or laparoscopy port sites were involved in 55%. The remainder of the high incidence sites of recurrent disease were within the hysterectomy site and in the abdominopelvic regions 5, 6 and 7. The rectosigmoid colon was seeded in 65% of patients, bladder, mid-right ureter, and apex of vagina in 50%, left pelvic sidewall in 40%, right pelvic sidewall in 35%, distal left ureter in 50% and distal right ureter in 35% (Table 1, Ref. [17]). In these patients having surgery for recurrent ovarian cancer, the abdominopelvic regions 5, 6 and 7 should be cleared of ovarian cancer at the time of hysterectomy.

Table 1. Sites of ovarian cancer progression in 20 patients following hysterectomy for primary disease at the time of reoperation for recurrent disease (From reference [17] with permission).

Anatomic site	Number	(%)
Undersurface right hemidiaphragm	14	70
Greater omentum	13	65
Abdominal incision/laparoscopy port site	11	55*
Rectosigmoid colon	13	65
Visceral surface of bladder	10	50*
Mid-right ureter	10	50
Apex of vagina	10	50*
Left pelvic sidewall	8	40*
Right pelvic sidewall	7	35*
Distal left ureter	10	50*
Distal right ureter	7	35*

*indicates tumor cell entrapment.

tomy. Yet they were layered by recurrent cancer in a large number of patients. What is the explanation for these observations of enhanced cancer progression in the pelvis?

The best explanation for this extensive disease in areas previously dissected free of cancer is TCE. Free intraperitoneal cancer cells at the time of surgery or shortly thereafter settle by pull of gravity into the surgically traumatized pelvic tissues. They become entrapped within blood, fibrin exudate and the irregular tissue surfaces. They become established implants at these crucial anatomic sites (abdominal and pelvic regions 5, 6 and 7). These are the anatomic sites in and around vital structures such as the rectosigmoid colon, bladder and distal ureters that may cause severe disruption of gastrointestinal or urinary tract function and rapid demise of the patient. These are also the anatomic sites that cause great difficulty in attempting a complete cytoreduction as illustrated by the data of Look *et al.* [16]. The metastatic efficiency of surgically traumatized tissue explains the TCE phenomenon.

1.3 Prevention of tumor cell entrapment (TCE)

These data and the concepts they generate have implications for the surgical management of ovarian cancer. The routine surgical intervention for stage III ovarian cancer may not always require hysterectomy and bilateral salpingo-oophorectomy. This resection results in a large number of cancer cells to be trapped at the hysterectomy site by TCE. Of course, the Fallopian tubes, cancerous ovary and contralateral tube and ovary should be resected. Also, the greater omentum can be debulked if this results in a significant reduction in tumor mass and therefore a reduction in recurrence of malignant ascites. A limited bilateral salpingo-oophorectomy is greatly facilitated by modern mechanical hemostatic devices. Salpingo-oophorectomy alone will result in a PSS of 1 and minimal TCE. In summary, if a large extent of ovarian cancer remains in the upper abdomen, the same extent of disease should be tolerated in abdominal and pelvic spaces 5, 6 and 7 and hysterectomy may not be indicated.

Of course, there are many clinical situations in which hysterectomy is indicated. If there is a large accumulation of tumor in the pelvis and this mass of disease will prevent a complete cytoreduction, then hysterectomy is necessary. However, it should only be removed if the abdomen including right and left subphrenic spaces and omental bursa are cleared of ovarian cancer by visual inspection. Hysterectomy is expected to be of benefit if it is part of a complete cytoreduction. If the debulking leaves residual disease within the abdomen, hysterectomy may not be of benefit and by TCE will cause harm.

1.4 Complete cytoreduction is an indication for hysterectomy and for HIPEC

When a complete cytoreduction is performed the number of free cancer cells to implant by TCE will be greatly reduced but not absent. To further reduce the number of free intraperitoneal cancer cells hyperthermic intraperitoneal chemotherapy (HIPEC) is indicated. The benefit to the patient of having HIPEC has been demonstrated at the time of interval resection in a randomized controlled trial by Van Driel *et al.* [18]. Its utility with cytoreductive surgery for recurrent ovarian cancer was demonstrated in a randomized controlled trial by Spiliotis [19]. It is my opinion that the survival advantage shown decisively by these two trials was related to a reduction in TCE by HIPEC. If the HIPEC were totally effective one would expect these randomized trials to show a more robust survival benefit. A more reliable HIPEC to eradicate TCE after hysterectomy is needed.

1.5 Occult ovarian cancer on the uterus as a rationale for hysterectomy

A second clinical situation in which the number of free ovarian cancer cells are greatly reduced, even absent, occurs with a complete or near complete response to neoadjuvant chemotherapy. This is expected in approximately 50% of patients treated with neoadjuvant chemotherapy who then have interval cytoreductive surgery. The surgeon can often recognize anatomic sites that were initially grossly involved by cancer but at surgery have no visible evidence of disease. Cryostat sections are rarely definitive regarding the presence versus absence of microscopic disease. The dilemma that faces that surgeon concerns which anatomic sites have experienced a complete and durable response and which sites have had a near complete response and will recur. Currently, there is no easy answer to this dilemma. However, the same principles that guide the surgeon to preserve the uterus with an incomplete debulking versus hysterectomy to achieve a complete cytoreduction should operate. If removal of residual tumor from the undersurface of the diaphragm, from the gastrohepatic ligament and from visceral peritoneum is thought necessary, then hysterectomy, pelvic peritonectomy and rectosigmoidectomy should occur. If the chemically cytoreduced tissues beneath the hemidiaphragm and within the abdomen do not receive further surgery, then the uterus need not be resected.

In some patients the response to chemotherapy is thought

to be complete at all site throughout the abdomen and pelvis except for a large persistent ovarian cancer invading the uterus. With disease controlled at other sites the hysterectomy and oophorectomy need to be performed in these patients with persistent disease at the primary cancer site.

The surgeon's dilemma of possible occult disease on the uterus was directly studied by Chitrathara and colleagues in the manuscript entitled, "Is hysterectomy needed in ovarian cancer?" They present 128 ovarian cancer patients who had hysterectomy [20]. Fifty-four percent of patients were given neoadjuvant chemotherapy and 46% had upfront surgery. The extent of visible involvement of the uterus was correlated with careful microscopic examination of the resected specimen. The uterus was involved by visual inspection in 19 patients and by microscopic evaluation in 20. They conclude that in patients with neoadjuvant chemotherapy or patients with upfront surgery, an absence of gross uterine involvement reliably predicts the absence of microscopic disease.

1.6 Synchronous endometrioid and ovarian cancer

Invasive endometrial cancer and ovarian cancer coexist in approximately 10% of women with a diagnosis of ovarian cancer [21]. These two sites for cancer may represent metastatic disease from either the uterus or the ovary but recent studies suggest two distinct primary sites [22]. These tumors occur in the perimenopausal age and usually are of a large size. They rarely show a pattern of transcoelomic spread along peritoneal surfaces as is seen with serous cancer. The Zaino *et al.* [21] data showed an excellent prognosis with 85% of patients free of disease at 5 years and 80% surviving at 10 years. Endometriosis is present in the ipsilateral or contralateral ovary in 20% of patients.

The coexistence of a cancer within the uterus in patients with ovarian cancer has been provided as a rationale for hysterectomy in all patients. However, the different natural history of the endometrioid cancer should be recognized [22]. Rarely does this histopathologic type of cancer present with gross unresectable disease beneath the hemidiaphragms and in the abdomen. Gross disease present after the surgeon's best efforts at cytoreduction rarely will exist. If it does, the tumor within the uterus is of no greater risk for adverse outcome than gross residual disease in the upper abdomen.

Bunting *et al.* [23] specifically addressed this potential danger of synchronous endometrial ovarian and uterine malignancy in a manuscript examining the requirement for routine hysterectomy for ovarian cancer. In 451 patients with ovarian cancer, final histopathology showed synchronous endometrial cancer in 15 patients (5%). All these patients had no macroscopic serosal involvement with ovarian cancer so were candidates for uterine preservation. All but 3 patients had an abnormal transvaginal ultrasound. They suggest that in patients with endometrioid histopathology, pelvic ultrasound is necessary. If any doubts regarding preservation of the uterus exists, an endometrial curettage is indicated at the time of surgery.

1.7 Failure to recognize the importance of tumor cell entrapment (TCE) in the past

One may ask, “How come the possible harm from hysterectomy in the absence of complete cytoreductive surgery (CRS) has not been recognized by prior clinical oncologists?” Why have these data that show the enhanced progression of disease recurrence within the pelvis not been previously available? One explanation is the incomplete dissection that is generally performed in a reoperative surgical procedure for ovarian cancer. For fear of damage to the bladder and ureters, the pelvic dissection may only be superficial. Only if one’s goal is complete removal of all disease from the abdomen and from the pelvis, is a complete dissection of the pelvis indicated. When a complete CRS is performed for recurrent ovarian cancer, this data becomes available. Also, much of the prior data comes from laparoscopic second-look or small abdominal incisions performed for a second-look. If on laparoscopy or a mini-laparotomy disease is visualized, the information that disease has recurred has been achieved. Therefore, a dissection to determine all possible sites of recurrent disease would not be performed. Also, other groups have not used the PSS in order to suggest the possible harmful effects of hysterectomy. Only when data is gathered from all the prior surgical records can the PSS be determined. Unfortunately, PSS is not generally a part of the preoperative assessment of a patient who is to undergo surgery for recurrent ovarian malignancy.

2. Conclusions

Hysterectomy and bilateral salpingo-oophorectomy is the standard of care for women with FIGO stage 3 ovarian cancer. However, our data from the PSS and TCE gathered at the time of reoperative surgery shows possible adverse effects of this resection as a result of enhanced disease progression surrounding vital structures within the pelvis. Free abdominal and pelvic cancer cells present in these patients may accumulate by TCE at the hysterectomy site. This pelvic tumor progression may result in adverse outcomes with urinary and gastrointestinal function. If hysterectomy and bilateral salpingo-oophorectomy is indicated, the ideal HIPEC will diminish or possibly completely prevent TCE at the hysterectomy resection site.

Author contributions

PHS designed and performed the research, made the editorial changes and read and approved the final manuscript.

Ethics approval and consent to participate

Not applicable.

Acknowledgment

I would like to express my gratitude to Renaldo Savady, MD who provided secretarial and electronic support during the writing of this manuscript.

Funding

This research received no external funding.

Conflict of interest

The author declares no conflict of interest.

References

- [1] Momenimovahed Z, Tiznobaik A, Taheri S, Salehiniya H. Ovarian cancer in the world: epidemiology and risk factors. *International Journal of Women’s Health*. 2019; 11: 287–299.
- [2] Holschneider CH, Berek JS. Ovarian cancer: epidemiology, biology, and prognostic factors. *Seminars in Surgical Oncology*. 2000; 19: 3–10.
- [3] Torre LA, Trabert B, DeSantis CE, Miller KD, Samimi G, Runowicz CD, *et al*. Ovarian cancer statistics, 2018. *CA: A Cancer Journal for Clinicians*. 2018; 68: 284–296.
- [4] Kuhn E, Kurman RJ, Vang R, Sehdev AS, Han G, Soslow R, *et al*. TP53 mutations in serous tubal intraepithelial carcinoma and concurrent pelvic high-grade serous carcinoma-evidence supporting the clonal relationship of the two lesions. *Journal of Pathology*. 2012; 226: 421–426.
- [5] Sehouli J, Senyuva F, Fotopoulou C, Neumann U, Denkert C, Werner L, *et al*. Intra-abdominal tumor dissemination pattern and surgical outcome in 214 patients with primary ovarian cancer. *Journal of Surgical Oncology*. 2009; 99: 424–427.
- [6] Lengyel E. Ovarian cancer development and metastasis. *American Journal of Pathology*. 2010; 177: 1053–1064.
- [7] Sugarbaker PH. Peritoneum and peritoneal cavity. In Standring S (ed.) *Gray’s Anatomy* (pp. 1098–1110). 41st edn. Chennai, India: Churchill Livingstone/Elsevier. 2015.
- [8] Carmignani CP, Sugarbaker TA, Bromley CM, Sugarbaker PH. Intraperitoneal cancer dissemination: mechanisms of the patterns of spread. *Cancer Metastasis Reviews*. 2003; 22: 465–472.
- [9] Goldstein P, Cabanas J, da Silva R, Sugarbaker PH. Management of peritoneal surface malignancy, a review. *Cancer Therapy* 2005; 3: 299–320.
- [10] Weiss L. Some effects of mechanical trauma on the development of primary cancers and their metastases. *Journal of Forensic Sciences*. 1990; 35: 614–627.
- [11] Sethna KS, Sugarbaker PH. New prospects for the control of peritoneal surface dissemination of gastric cancer using perioperative intraperitoneal chemotherapy. *Cancer Therapy*. 2004; 2: 79–84.
- [12] Fares J, Fares MY, Khachfe HH, Salhab HA, Fares Y. Molecular principles of metastasis: a hallmark of cancer revisited. *Signal Transduction and Targeted Therapy*. 2020; 5: 28.
- [13] Eggermont AM, Steller EP, Marquet RL, Jeekel J, Sugarbaker PH. Local regional promotion of tumor growth after abdominal surgery is dominant over immunotherapy with interleukin-2 and lymphokine activated killer cells. *Cancer Detection and Prevention*. 1988; 12: 421–429.
- [14] Ceelen W, Pattyn P, Mareel M. Surgery, wound healing, and metastasis: recent insights and clinical implications. *Critical Reviews in Oncology/Hematology*. 2014; 89: 16–26.
- [15] Jacquet P, Sugarbaker PH. Current methodologies for clinical assessment of patients with peritoneal carcinomatosis. *Journal of Experimental & Clinical Cancer Research*. 1996; 15: 49–58.
- [16] Look M, Chang D, Sugarbaker PH. Long-term results of cytoreductive surgery for advanced and recurrent epithelial ovarian cancers and papillary serous carcinoma of the peritoneum. *International Journal of Gynecological Cancer*. 2004; 14: 35–41.
- [17] Sugarbaker PH. Patterns of recurrence in women with ovarian cancer having hysterectomy for treatment of primary disease. (Submitted)
- [18] van Driel WJ, Koole SN, Sikorska K, Schagen van Leeuwen JH, Schreuder HWR, Hermans RHM, *et al*. Hyperthermic Intraperitoneal Chemotherapy in Ovarian Cancer. *New England Journal of Medicine*. 2018; 378: 230–240.

- [19] Spiliotis J, Halkia E, Lianos E, Kalantzi N, Grivas A, Efstathiou E, *et al.* Cytoreductive Surgery and HIPEC in Recurrent Epithelial Ovarian Cancer: a Prospective Randomized Phase III Study. *Annals of Surgical Oncology*. 2015; 22: 1570–1575.
- [20] Chitrathara K, Sheikh ZA, Vijaykumar DK, Kuriakose S, Anupama R, Nandeesh M. Is hysterectomy needed in ovarian cancer? *Indian Journal of Cancer*. 2011; 48: 471–476.
- [21] Zaino R, Whitney C, Brady MF, DeGeest K, Burger RA, Buller RE. Simultaneously detected endometrial and ovarian carcinomas—a prospective clinicopathologic study of 74 cases: a gynecologic oncology group study. *Gynecologic Oncology*. 2001; 83: 355–362.
- [22] Dizon DS, Birrer MJ. Making a Difference: Distinguishing Two Primaries from Metastasis in Synchronous Tumors of the Ovary and Uterus. *Journal of the National Cancer Institute*. 2016; 108: djv442.
- [23] Bunting MW, Jaaback KS, McNally OM. Routine Hysterectomy in the Surgical Management of Ovarian Cancer: a Retrospective Case Series, Physician Opinion Survey, and Review of the Literature. *International Journal of Gynecologic Cancer*. 2011; 21: 1579–1584.