

# The issue of false positive lymph nodes on [<sup>18</sup>F] FDG-PET/CT for cervical carcinoma and consequences for treatment

Polo Cornelisz Vermolen<sup>1</sup>, Nienke E. van Trommel<sup>1,†</sup>, Wouter V. Vogel<sup>2</sup>, Judit A. Adam<sup>3</sup>, Jacobus van der Velden<sup>4,†</sup>, Constantijne H. Mom<sup>4,\*,†</sup>

<sup>1</sup>Center for Gynaecological Oncology Amsterdam, Antoni van Leeuwenhoek Hospital, 1066 CX Amsterdam, the Netherlands

<sup>2</sup>Department of Nuclear Medicine and Department of Radiotherapy, Antoni van Leeuwenhoek Hospital, 1066 CX Amsterdam, Netherlands

<sup>3</sup>Department of Radiology and Nuclear Medicine, Amsterdam University Medical Center, 1105 AZ Amsterdam, Netherlands

<sup>4</sup>Center for Gynaecological Oncology Amsterdam, Amsterdam University Medical Center, 1105 AZ Amsterdam, Netherlands

\*Correspondence: [c.mom@amsterdamumc.nl](mailto:c.mom@amsterdamumc.nl) (Constantijne H. Mom)

† These authors contributed equally.

DOI:10.31083/j.ejgo4205142

This is an open access article under the CC BY 4.0 license (<https://creativecommons.org/licenses/by/4.0/>).

Submitted: 14 April 2021 Revised: 7 May 2021 Accepted: 17 May 2021 Published: 15 October 2021

**Objective:** Since 2018 imaging and histopathology are incorporated in the International Federation of Gynecology and Obstetrics (FIGO) staging system of cervical cancer. The aim of this study was to assess the positive predictive value (PPV) and negative predictive value (NPV) of 2-[<sup>18</sup>F] fluoro-2-deoxy-D-glucose [<sup>18</sup>F] FDG-PET/CT ([<sup>18</sup>F] FDG-PET/CT) for lymph node involvement in patients with cervical cancer and to review the literature. **Methods:** First, PPV and NPV were calculated in a retrospective study including 98 patients with stage  $\geq$ IB1 cervical cancer that underwent a [<sup>18</sup>F] FDG-PET/CT before surgery. Second, the literature was reviewed on PPV and NPV of PET/CT in cervical cancer. Twenty-one studies were included and analyzed using the Spearman's rank correlation coefficient. **Results:** In the retrospective study 63 patients (64%) were treated with a radical hysterectomy and complete pelvic lymph node dissection, and 35 patients (36%) underwent a lymph node debulking followed by chemoradiation. The PPV was 79% (inconclusive PET/CT interpreted as suspicious) or 89% (inconclusive PET/CT interpreted as non-suspicious) and the NPV was 81% or 80% respectively. The PPV in the subgroup of 63 patients treated with pelvic node dissection was 56% or 70% respectively. The NPV was 81% for both strategies. Literature results showed a positive correlation ( $R = 0.354$ ) between the percentage of patients with positive nodes and the PPV of PET/CT. **Conclusion:** [<sup>18</sup>F] FDG-PET/CT overestimates the incidence of lymph node metastases, especially in early stage cervical cancer. This may cause a shift of the treatment regime from surgery to radiotherapy. Therefore, histopathological confirmation of [<sup>18</sup>F] FDG-PET/CT-positive nodes is essential to guide therapy decisions.

## Keywords

Cervical cancer; FIGO staging system; [<sup>18</sup>F] FDG-PET/CT; Positive predictive value; Lymph node metastases; Surgery; Radiotherapy

## 1. Introduction

Cervical cancer is a common gynecologic malignancy. In women, it is the fourth most common cancer and the fourth most common cause of cancer death worldwide with an estimated 570,000 cases and 311,000 deaths in 2018. Due to the

implementation of screening programs and the human papilloma virus vaccination in developed countries, the incidence and mortality are declining, but in resource-poor nations the incidence remains high [1, 2].

Until 2018, carcinoma of the uterine cervix was clinically staged, based on the recommendations of the International Federation of Gynecology and Obstetrics (FIGO) as published in 2009 [3]. In 2018 the FIGO staging for cervical cancer was revised. Imaging techniques and pathological findings are now incorporated in the staging system with annotations 'r' and 'p' [4]. The incorporation of imaging in the staging reflects the increasing importance of these techniques in the pre-therapeutic work-up of cervical cancer [5, 6]. The involvement of lymph nodes is the strongest independent prognostic factor in women with cervical cancer [7, 8]. Many studies have demonstrated the value of 2-[<sup>18</sup>F] fluoro-2-deoxy-D-glucose [<sup>18</sup>F] FDG-PET/CT to define prognostic subgroups, especially for patients with suspicious pelvic and para-aortic lymph nodes [9, 10].

The primary intent of a good staging system, as defined by the authors of the FIGO 2018 staging, is to determine the anatomical extent of disease and predict survival outcomes. Furthermore, it may facilitate the comparison of patients and their outcomes between centers [4]. For this purpose, imaging techniques are mainly evaluated by their sensitivity and specificity to detect tumor locations. However, the use of imaging to define prognostic subgroups must not be confused with using imaging to define individual treatment. For that purpose, it is essential to know the accuracy of the [<sup>18</sup>F] FDG-PET/CT scan for lymph node metastases and especially the positive predictive value (PPV) and negative predictive value (NPV) of the [<sup>18</sup>F] FDG-PET/CT scan.

The aim of this study was to define the PPV and NPV of [<sup>18</sup>F] FDG-PET/CT for lymph node involvement in patients with cervical cancer that underwent either a complete

pelvic lymph node dissection or a lymph node debulking as histopathologic confirmation. Subsequently the literature on this subject was reviewed, focusing on the PPV and NPV of [<sup>18</sup>F] FDG-PET/CT imaging in cervical cancer in populations with various frequencies of positive lymph nodes.

## 2. Patients and methods

### 2.1 Retrospective study

Consecutive patients with cervical cancer that underwent a pre-treatment [<sup>18</sup>F] FDG-PET/CT scan and subsequently a surgical lymph node assessment (lymph node dissection or lymph node debulking) were retrospectively included. All patients were treated between the 1 January 2010 and the 31 December 2018 in the Center of Gynecologic Oncology Amsterdam (CGOA), a tertiary referral center for gynecological cancer, comprising the Amsterdam University Medical Center (UMC) and the Antoni van Leeuwenhoek/Netherlands Cancer Institute (AvL/NKI). Ethical approval for the study was obtained from the Institutional Review Board (IRB) of the Antoni van Leeuwenhoek/Netherlands Cancer Institute (reference number IRBd21-130). Written informed consent was waived by the IRB, because according to Dutch law, this is not obligated in case anonymized patient data are used, keeping in mind the rules of good clinical practice.

All diagnoses were histologically confirmed and only patients with squamous, adenosquamous or adenocarcinoma were included in this study. Staging was done by gynecological examination by an experienced gynecologic oncologist together with a radiotherapist according to the guidelines of the FIGO 2009 system [3]. An MRI was done in all patients. In addition, a [<sup>18</sup>F] FDG-PET/CT scan was performed in patients with a FIGO 2009 stage IB2 or higher and in patients with bulky or suspicious nodes on the pre-therapeutic MRI.

[<sup>18</sup>F] FDG-PET/CT scans were performed according to Dutch (Nedpas) and international (EARL) standards. Patients, with target blood glucose level <10 mmol/L after fasting, were injected with 180–300 MBq [<sup>18</sup>F] FDG. Scans were performed after an incubation period of 60 (±5) minutes. In the AvL/NKI scanning was done from the skull base to upper thighs with 2 minutes per bed position on a hybrid PET/CT scanner (Gemini TF, Gemini TF Big Bore or Vereos, Philips Healthcare, the Netherlands). Images were reconstructed to 4 mm slices and 4 × 4 mm pixels. Low-dose CT was acquired (120–140 kV, target energy 40 mAs with automatic dose modulation) for attenuation correction and anatomical correlation, with images reconstructed to 2 mm slices and 1.17 × 1.17 mm pixels. In the Amsterdam UMC up to October 2017 the Gemini TF (Philips Healthcare) was used. First, a diagnostic CT scan was performed from the thigh to the skull base (120 kV, 150 mAs, 16 × 1.5 collimation, 0.8013 pitch) during administration of 2 mL/kg i.v. contrast agent with 2 mL/s flow and a 50 s delay (portal phase) and oral contrast. Then, the PET acquisition followed, with a scan time of 2 minutes per bed position and reconstructed to 5 mm slices and 4 × 4 mm pixels. After October 2017 the Siemens

Biograph mCT TrueV Flow (Siemens Healthcare, Erlangen, Germany) scanner was used. First, a diagnostic CT scan was performed from the thigh to the skull base (with automatic dose modulation in both energy and current with 120 kV/160 mAs reference values, 128 × 0.6 collimation, 0.9 pitch) during administration of an i.v. contrast agent with 3 mL/s flow and a 65 s delay (portal phase) and oral contrast or water. Then, the PET acquisition followed, with a flow time of 1.5 mm/sec and reconstructed to 5 mm slices and 4 × 4 mm pixels.

A node was considered suspicious if it had a short axis >1 cm on CT and was [<sup>18</sup>F] FDG-positive (evidently more than the blood pool activity of the adjacent vessel) and non-suspicious if it had a short axis <1 cm and did not show any [<sup>18</sup>F] FDG-uptake. A node was considered inconclusive if it was not enlarged and showed slightly elevated [<sup>18</sup>F] FDG-uptake (compared to blood pool activity of the adjacent vessel) or was enlarged without any [<sup>18</sup>F] FDG-uptake.

Patients with FIGO 2009 stage IB1 and IB2 <6 cm were treated with a radical hysterectomy and pelvic lymph node dissection. At our center FIGO stage IB2 tumors <6 cm are treated with a radical hysterectomy Querleu type C [11]. Patients with higher stage cervical cancer (IB2 >6 cm and IIB-IVA) were treated with a combination of radiotherapy and chemotherapy. These patients received a lymph node debulking by laparotomy prior to chemoradiation, when there were bulky nodes on Magnetic Resonance Imaging (MRI). A bulky node was defined as a lymph node suspicious for a metastasis with a diameter of at least 2 cm on MRI. Thus, tissue for nodal assessment was obtained either during lymph node dissection and radical hysterectomy or during lymph node debulking in patients with bulky nodes on MRI.

Patient based sensitivity, specificity, PPV and NPV of [<sup>18</sup>F] FDG-PET/CT for the presence of pelvic and para aortic lymph node metastases were calculated. Results of the [<sup>18</sup>F] FDG-PET/CT scan were retrieved from the original report. These results were discussed in a multidisciplinary tumor board and classified as suspicious, non-suspicious or inconclusive. We calculated the sensitivity, specificity, PPV and NPV twice. In the first analysis we added the inconclusive results to the group with suspicious nodes. In the second analysis we considered the inconclusive PET results as non-suspicious. We analyzed both the complete group (patients who had a lymph node dissection and those who had a lymph node debulking) and, separately, patients that underwent pelvic lymph node dissection. Results from the histopathologic report were the gold standard.

### 2.2 Literature search

A literature search was performed including recent studies evaluating the sensitivity and specificity of an [<sup>18</sup>F] FDG-PET/CT scan for histologically confirmed lymph nodes. The search was performed in the databases PubMed, Web of Science and Embase using the following terms: 'positron emission tomography computed tomography' OR 'PET CT' AND 'cervical/cervix' AND 'neoplasm/cancer/carcinoma/tumor'

**Table 1. Characteristics of 98 patients with cervical cancer and a [<sup>18</sup>F] FDG-PET/CT scan before surgical/pathological assessment of the pelvic lymph nodes.**

	Number of patients	%
FIGO 2009 stage		
• IB1	12	12%
• IB2	48	49%
• IIA	9	9%
• IIB	14	15%
• IIIA	2	2%
• IIIB	7	7%
• IVA	5	5%
• IVB	1	1%
Treatment		
• Radical hysterectomy and complete pelvic lymphadenectomy	63	64%
• Lymph node debulking and chemoradiation	35	36%
Pathological assessment of lymph nodes		
• No metastases (negative)	42	43%
• Metastases (positive)	56	57%
Histological type of tumor		
• Squamous	68	67%
• Adenocarcinoma	26	27%
• Adenosquamous	4	6%

AND 'stage' OR 'staging' OR 'lymph node' AND 'sensitivity' OR 'specificity' OR 'accuracy' OR 'positive/negative predictive value'. Both retrospective and prospective studies were included when published data directly showed the PPV or when the PPV could be calculated from original numbers. Only studies in which the number of inclusions was based on per patient data with a minimum of 50 patients were included (in contrast to per lymph node or lymph node region). Reviews, meta-analyses and case reports were excluded, as well as studies in which nodes were scored as being positive based on results other than histopathology. The literature was reviewed and analyzed using the Spearman's rank correlation coefficient, showing the degree of association between the frequency of positive nodes and the PPV.

### 3. Results

#### 3.1 Retrospective study

A total of 98 patients were included. A summary of the baseline characteristics is shown in Table 1. Following the FIGO 2009 classification a majority of patients (72%) had early stage cervix carcinoma (FIGO IB1–IIA). Twenty-six patients (27%) had locally advanced cervical cancer (FIGO IIB–IVA) and one patient (1%) had metastatic disease (FIGO IVB). Two thirds of the patients were treated with a radical hysterectomy and complete pelvic lymph node dissection, whereas one third received a lymph node debulking (97 patients a pelvic lymph node debulking only and one patient pelvic and para-aortic), followed by chemoradiation. The majority of patients had a squamous cell carcinoma (67%), followed by adenocarcinoma (27%) and adenosquamous carcinoma (6%).

The [<sup>18</sup>F] FDG-PET/CT scan showed suspicious lymph nodes in 53 patients, non-suspicious nodes in 36 patients,

and nodes classified as inconclusive in 9 patients. After histopathological assessment, 56 patients (57%) had proven positive nodes. All patients with inconclusive nodes on [<sup>18</sup>F] FDG-PET/CT had pathologically negative nodes. This resulted in a false positive ratio in clinically early stage cervical cancer (IB1–IIA) of 19% (13/69) and 3% (1/29) in advanced stage cervical cancer (IIB–IVB). Table 2 shows the sensitivity, specificity, PPV and NPV of the complete group. The PPV is 79% when inconclusive [<sup>18</sup>F] FDG-PET/CT results are considered suspicious or 89% when these are considered non-suspicious. The NPV is 81% or 80%, depending on this interpretation difference.

If patients who had a nodal debulking were excluded (N = 35), the remaining 63 patients treated with radical hysterectomy and pelvic node dissection had a prevalence of 35% histopathologic proven positive nodes Table 3. The PPV is 56%–70% depending on the consideration of inconclusive [<sup>18</sup>F] FDG-PET/CT results as suspicious or non-suspicious. The NPV is 81% in both cases.

#### 3.2 Literature

The study selection process is schematically shown in Fig. 1. By following our search strategy, a total of twenty-one studies were considered eligible for this review. The extracted data and baseline characteristics from the included articles are outlined in Table 4 (Ref. [12–34]).

The 21 studies showed a positive correlation ( $R = 0.354$ ) between the percentage of patients with positive nodes and the PPV of the [<sup>18</sup>F] FDG-PET/CT (Fig. 2). The PPV increases in study populations with a high percentage of patients with positive lymph nodes. The PPV ranged from 18% [22] to 100% [21].

**Table 2. Predictive values of [<sup>18</sup>F] FDG-PET/CT scan for positive pelvic lymph nodes in 98 patients who had a complete pelvic node dissection or pelvic node debulking.**

[ <sup>18</sup> F] FDG-PET/CT	Total group (95% CI), N = 98	Inconclusive = non-suspicious
Sensitivity	88% (75%–94%)	84% (71%–92%)
Specificity	69% (53%–82%)	86% (71%–94%)
PPV	79% (66%–88%)	89% (76%–95%)
NPV	81% (63%–91%)	80% (65%–90%)

Inconclusive [<sup>18</sup>F] FDG-PET/CT results were considered suspicious in the total group. The second column shows the predictive values in the group where inconclusive [<sup>18</sup>F] FDG-PET/CT results (N = 9) were considered non-suspicious.

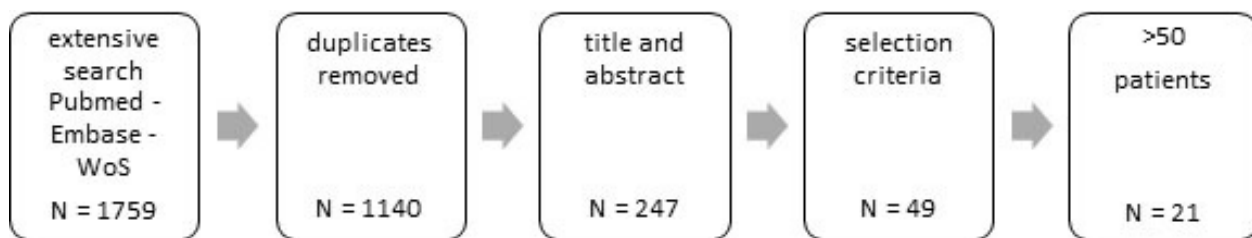
PPV, positive predictive value; NPV, negative predictive value; CI, Confidence Interval.

**Table 3. Predictive values of [<sup>18</sup>F] FDG-PET/CT scan for pelvic lymph nodes in patients who had a complete pelvic node dissection.**

[ <sup>18</sup> F] FDG-PET/CT	Total group (95% CI), N = 63	Inconclusive = non-suspicious
Sensitivity	68% (45%–85%)	64% (41%–82%)
Specificity	71% (54%–83%)	85% (70%–94%)
PPV	56% (36%–74%)	70% (46%–87%)
NPV	81% (63%–91%)	81% (66%–91%)

Inconclusive [<sup>18</sup>F] FDG-PET/CT results were considered suspicious in the total group. The second column shows the predictive values in the group where inconclusive [<sup>18</sup>F] FDG-PET/CT results (N = 9) were considered non-suspicious.

PPV, positive predictive value; NPV, negative predictive value; CI, Confidence Interval.



**Fig. 1. Study selection.** N, number of studies.

#### 4. Discussion

Our retrospective study shows a PPV of 79% and NPV of 81% for [<sup>18</sup>F] FDG-PET/CT scan in staging for cervical cancer, if inconclusive cases are counted as suspicious. If inconclusive results on the [<sup>18</sup>F] FDG-PET/CT are considered non-suspicious, the PPV is 89% and NPV 80%. In the subgroup with clinically early stage disease that underwent a radical hysterectomy and pelvic lymph node dissection the prevalence of positive nodes is lower. The PPV of [<sup>18</sup>F] FDG-PET/CT in this subgroup drops to 56%, due to a relatively high false positive ratio of 19% in early stage cervical cancer. Our literature review supports these findings by showing a positive correlation on the prevalence of positive nodes and PPV.

Although a recent meta-analysis shows a moderate sensitivity (72%) and high specificity (96%) of a [<sup>18</sup>F] FDG-PET/CT scan in the diagnosis of lymph node metastasis in cervical cancer [9], the positive predictive value is also of importance. In the subgroup of patients with early stage disease and therefore with a lower prevalence of positive nodes,

the PPV is low due to a relatively high false positive ratio. Depending on the prevalence of positive lymph nodes, [<sup>18</sup>F] FDG-PET/CT scan has a high likelihood of overestimating the presence of lymph node metastases.

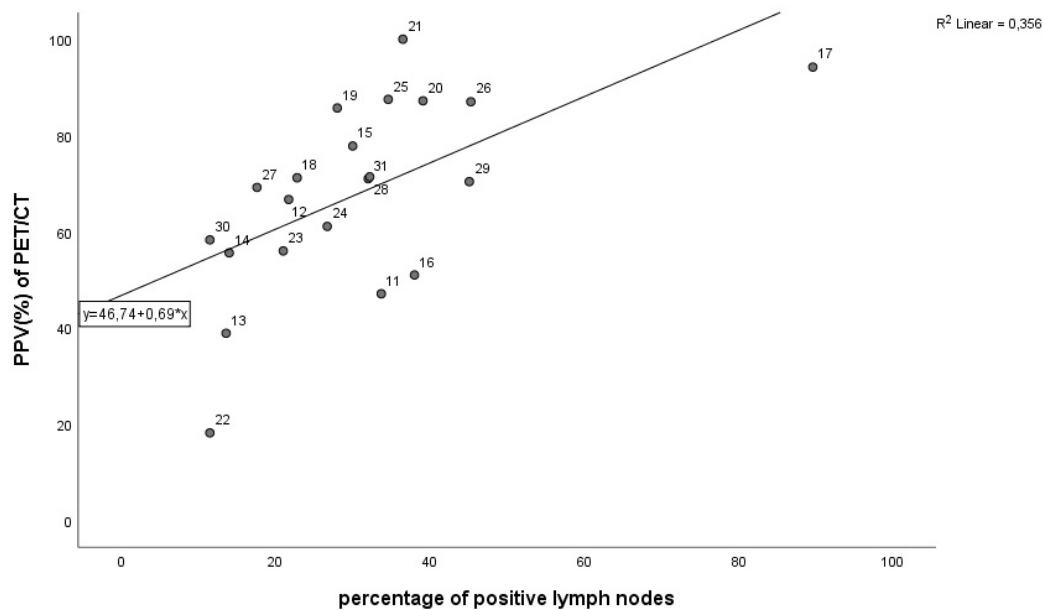
In clinically early stage cervical cancer, this may have great implications. In the new FIGO staging system of 2018 results of imaging are incorporated, and therefore false positive nodes on [<sup>18</sup>F] FDG-PET/CT may result in incorrect upstaging to stage IIIC. In our retrospective study we calculated a PPV of 56% to 70% in early stage disease. This means that in 30% to 44% of clinically early stage patients with suspicious nodes on [<sup>18</sup>F] FDG-PET/CT, this would result in erroneous upstaging to stage IIIC. To avoid inaccurate attribution of a higher stage and to guide treatment decisions, histopathological proof of metastatic disease in the suspicious nodes on [<sup>18</sup>F] FDG-PET/CT should be obtained [33].

The problem of a high rate of false positive lymph nodes in early stage cervical cancer, particularly relates to treatment preferences. If we feel that primary surgery, in some cases followed by adjuvant (chemo) radiotherapy, is to be pre-

**Table 4. Collated literature data on the predictive value of [<sup>18</sup>F] FDG-PET/CT scan for pelvic and/or para aortic lymph node metastases.**

Study	Cohort	N	Metastatic location	FIGO2009 stage	TP	FP	FN	TN	Sens (%)	Spec (%)	PPV (%)	NPV (%)	Patients with positive nodes (%)
Chung H 2010 [12]	Retro	83	Pelvis	IB-II	8	9	20	46	29	84	47	70	34
Crivellaro C 2012 [13]	Pro	69	Pelvis	IB1-IIA	4	2	11	52	27	96	67	83	22
Dong Y 2014 [14]	Retro	59	Pelvis, Pao	IA-IIA	7	11	1	40	88	78	39	98	14
Gee M 2018 [15]	Pro	153	Pelvis, Pao	IB2-IVA	10	8	11	124	48	94	56	92	14
Goyal B 2010 [16]	Pro	80	Pelvis, Pao	IB-IIB	14	4	10	52	58	93	78	84	30
Kim S 2009 [17]	Pro	79	Pelvis, Pao	IB-IVA	14	14	16	35	47	71	51	69	38
Leblanc E 2011 [18]	Retro	125	Pelvis, Pao	IB2-IVA	98	6	14	7	88	54	94	33	90
Li K 2019 [19]	Retro	394	Pelvis	IA1-IIA2	52	21	38	283	58	93	71	88	23
Lin W 2003 [20]	Pro	50	Pelvis, Pao	IIB-IVA	12	2	2	34	86	94	86	94	28
Lv K 2014 [21]	Retro	87	Pelvis, Pao	IA-IIB	34	5	0	48	100	91	87	100	39
Ma S 2003 [22]	Pro	104	Pelvis, Pao	IB-IVB	38	0	0	66	100	100	100	100	37
Margulies A 2013 [23]	Retro	61	Pelvis	IB2-IVA	4	18	3	36	57	67	18	92	12
Nogami Y 2015 [24]	Retro	70	Pelvis, Pao	IA-IIB	5	4	10	51	33	93	56	84	21
Papadia A 2017 [25]	Retro	60	Pelvis, Pao	IA-IIA	11	7	5	37	69	84	61	88	27
Perez T 2013 [26]	Pro	52	Pao	>IB1	14	2	4	32	78	94	88	89	35
Sarabhai T 2018 [27]	Pro	53	Pelvis, Pao	IB-IVA	20	3	4	26	83	90	87	87	45
Signorelli M 2011 [28]	Pro	159	Pelvis, Pao	IB1-IIA	9	4	19	127	32	97	69	87	18
Wright J 2005 [29]	Retro	59	Pelvis	IA2-IIA	10	4	9	36	53	91	71	80	32
Xu X 2016 [30]	Retro	51	Pelvis, Pao	IB-IVA	19	8	4	20	83	71	70	83	45
Yang Z 2016 [31]	Retro	113	Pelvis, Pao	IB1-IIA2	7	5	6	95	54	95	58	94	12
Ramirez PT 2011 [32]	Pro	60	Pao	IB2-IVA	5	2	9	44	36	96	71	83	23

Retro-/Pro, retro-/prospective; N, number of included patients; Pelvis, pelvic lymph node metastasis; Pao, para aortic lymph node metastasis; TP, true positive; FP, false positive; FN, false negative; TN, true negative; Sens, sensitivity; Spec, specificity; PPV, positive predictive value; NPV, negative predictive value.



**Fig. 2. The correlation between the percentage of positive lymph nodes (x-axis) in the evaluated cohort and the reported PPV of the [<sup>18</sup>F] FDG-PET/CT scan (y-axis) in the literature as summarized in Table 4 (p = 0.006) (Value labels correspond to reference number).**

ferred over primary chemoradiation, a high false positive rate may pose a serious problem. If treatment decisions are solely based on imaging, part of patients with clinically early stage cervical cancer, but upstaged in FIGO 2018 based on imaging alone, will be overtreated because of a high false positive

rate. Treatment may then change from radical hysterectomy to chemoradiation.

The literature is not clear about the treatment of choice in early stage cervical cancer because of the absence of level I evidence. A recent review concluded that on this subject no



statement can be made due to the lack of randomized controlled trials in FIGO 2009 stage IB2 cervical cancer on this subject [34]. The only randomized study comparing surgery and primary radiotherapy in FIGO 1992 stage IB1 and IB2 shows no difference of survival in the treatment options [35]. Because this study dates from 1997, it must be noted that radiotherapy techniques have developed since and chemotherapy has been added to the radiotherapy [36].

There may be a slight advantage for surgery according to data of a randomized controlled trial in advanced cervical cancer. In this prospective trial, patients with locally advanced cervical cancer where either staged with a lymph node dissection in conjunction with pre-operative imaging (MRI or CT abdomen and CT or PET-CT chest) or the same imaging alone. Surgical staging resulted in upstaging in 33% of patients. Although overall survival did not differ between both arms, patients had a better cancer specific survival and disease free survival if staging of lymph nodes was performed surgically compared to patients who had suspicious lymph nodes on imaging which were left in situ [37].

Focusing on secondary outcomes as pelvic toxicity, treatment with chemoradiation has a higher risk of bladder and rectal problems [38]. Furthermore, the damage of internal genitals caused by high dose radiation may lead to loss of ovarian function and vaginal fibrosis resulting in postmenopausal and negative sexual symptoms. This can have a serious negative impact on the quality of life, especially in younger patients [39].

On the other hand, advocates of primary chemoradiation in this context, argue that these patients with suspicion of lymph node metastases on imaging have a fair chance of ending up having “triple therapy”. In that case, patients with lymph node metastases will be treated by both a radical hysterectomy, and adjuvant (chemo) radiotherapy. This will result in unnecessary extra morbidity. A relatively high false positive test result for [<sup>18</sup>F] FDG-PET/CT is of less importance in this scenario.

The addition of (chemo) radiotherapy to a radical hysterectomy will undoubtedly result in extra morbidity compared to surgery alone [40]. However, compared with the alternative, primary chemoradiation, it does not result in higher morbidity [40]. A recent retrospective study even showed that women after primary (chemo) radiotherapy reported more physical, social and sexual symptoms compared with a group of patients who had primary surgery followed by adjuvant radiotherapy in selected cases [41].

A remaining question about [<sup>18</sup>F] FDG-PET/CT in cervical cancer is whether it has any impact on the prognosis of patients. There is one randomized controlled trial on the clinical value of a [<sup>18</sup>F] FDG-PET/CT scan in cervical cancer. This study could not demonstrate a better outcome in patients where a [<sup>18</sup>F] FDG-PET/CT was used in clinical decision making versus no [<sup>18</sup>F] FDG-PET/CT. However, this study was underpowered due to poor accrual, and therefore no hard conclusions could be drawn [33].

One of the strengths of this study is that we have included 98 patients which is a larger number than most of the studies included in the collated literature overview (Table 4) and that all patients were evaluated and treated according to a uniform protocol within the Center for Gynecologic Oncology Amsterdam. Next to that, a histopathologic confirmation of the nodal status was given for all patients who underwent a [<sup>18</sup>F] FDG-PET/CT scan. One of the drawbacks is that data collection was performed retrospectively. Of notice, in the study period we did not perform sentinel lymph node procedures only in our center. If a sentinel lymph node procedure was performed, this was always done in conjunction with a full pelvic lymphadenectomy, since we decided to wait for prospectively collected data on safety and efficacy of this procedure.

## 5. Conclusions

This study shows that [<sup>18</sup>F] FDG-PET/CT has a significant likelihood to overestimate the incidence of lymph node metastases, especially in early stage cervical cancer where the frequency of histologically confirmed positive lymph nodes is relatively low. This finding was supported by a review of the existing literature. We need to be aware that this issue may lead to an unnecessary shift from radical surgery to primary chemoradiation.

Therefore, we suggest that [<sup>18</sup>F] FDG-PET/CT should not be routinely used for nodal staging in early stage cervical cancer. If it is used, histopathological confirmation of lymph nodes suspicious for metastases on [<sup>18</sup>F] FDG-PET/CT is essential to guide therapy decisions, especially in early stage disease.

## Author contributions

PCV: analysis, writing and editing. NT: conceptualization, methodology, writing, reviewing and editing. WV: methodology and reviewing. JA: methodology and reviewing. JV: conceptualization, methodology, analysis, writing, reviewing and editing. CM: conceptualization, methodology, analysis, writing, reviewing and editing. All authors contributed to editorial changes in the manuscript. All authors read and approved the final manuscript.

## Ethics approval and consent to participate

Ethical approval for the study was obtained from the Institutional Review Board (IRB) of the Antoni van Leeuwenhoek/Netherlands Cancer Institute (reference number IRBd21-130). Written informed consent was waived by the IRB, because according to Dutch law, this is not obligated in case anonymized patient data are used, keeping in mind the rules of good clinical practice.

## Acknowledgment

Not applicable.

## Funding

This research received no external funding.

## Conflict of interest

The authors declare no conflict of interest.

## References

- [1] Bray F, Ferlay J, Soerjomataram I, Siegel RL, Torre LA, Jemal A. Global cancer statistics 2018: GLOBOCAN estimates of incidence and mortality worldwide for 36 cancers in 185 countries. *CA: A Cancer Journal for Clinicians*. 2018; 68: 394–424.
- [2] Bhatla N, Aoki D, Sharma DN, Sankaranarayanan R. Cancer of the cervix uteri. *International Journal of Gynecology & Obstetrics*. 2018; 143: 22–36.
- [3] Pecorelli S, Zigliani L, Odicino F. Revised FIGO staging for carcinoma of the cervix. *International Journal of Gynecology & Obstetrics*. 2009; 105: 107–108.
- [4] Bhatla N, Berek JS, Cuello Fredes M, Denny LA, Grenman S, Karunaratne K, *et al*. Revised FIGO staging for carcinoma of the cervix uteri. *International Journal of Gynecology & Obstetrics*. 2019; 145: 129–135.
- [5] Sala E, Wakely S, Senior E, Lomas D. MRI of malignant neoplasms of the uterine corpus and cervix. *American Journal of Roentgenology*. 2007; 188: 1577–1587.
- [6] Jolly S, Uppal S, Bhatla N, Johnston C, Maturen K. Improving global outcomes in cervical cancer: the time has come for international federation of gynecology and obstetrics staging to formally incorporate advanced imaging. *Journal of Global Oncology*. 2018; 4: 1–6.
- [7] Fleming ND, Frumovitz M, Schmeler KM, dos Reis R, Munsell MF, Eifel PJ, *et al*. Significance of lymph node ratio in defining risk category in node-positive early stage cervical cancer. *Gynecologic Oncology*. 2015; 136: 48–53.
- [8] Singh AK, Grigsby PW, Dehdashti F, Herzog TJ, Siegel BA. FDG-PET lymph node staging and survival of patients with FIGO stage IIIb cervical carcinoma. *International Journal of Radiation Oncology, Biology, Physics*. 2003; 56: 489–493.
- [9] Ruan J, Zhang Y, Ren H. Meta-analysis of PET/CT detect lymph nodes metastases of cervical cancer. *Open Medicine*. 2018; 13: 436–442.
- [10] Liu B, Gao S, Li S. A comprehensive comparison of CT, MRI, positron emission tomography or positron emission Tomography/CT, and diffusion weighted imaging-MRI for detecting the lymph nodes metastases in patients with cervical cancer: a meta-analysis based on 67 studies. *Gynecologic and Obstetric Investigation*. 2017; 82: 209–222.
- [11] Derks M, Biewenga P, Van der Velden J, Kenter GG, Stalpers LJA, Buist MR. Results of radical surgery in women with stage IB2/IIA2 cervical cancer. *Acta Obstetrica et Gynecologica Scandinavica*. 2016; 95: 166–172.
- [12] Chung HH, Kang KW, Cho JY, Kim JW, Park N, Song Y, *et al*. Role of magnetic resonance imaging and positron emission tomography/computed tomography in preoperative lymph node detection of uterine cervical cancer. *American Journal of Obstetrics and Gynecology*. 2010; 203: 156.e1–156.e5.
- [13] Crivellaro C, Signorelli M, Guerra L, De Ponti E, Buda A, Dolci C, *et al*. 18F-FDG PET/CT can predict nodal metastases but not recurrence in early stage uterine cervical cancer. *Gynecologic Oncology*. 2012; 127: 131–135.
- [14] Dong Y, Wang X, Wang Y, Liu Y, Zhang J, Qian W, *et al*. Validity of 18F-fluorodeoxyglucose positron emission tomography/computed tomography for pretreatment evaluation of patients with cervical carcinoma. *International Journal of Gynecological Cancer*. 2014; 24: 1642–1647.
- [15] Gee MS, Atri M, Bandos AI, Mannel RS, Gold MA, Lee SI. Identification of distant metastatic disease in uterine cervical and endometrial cancers with FDG PET/CT: analysis from the ACRIN 6671/GOG 0233 multicenter trial. *Radiology*. 2018; 287: 176–184.
- [16] Goyal BK, Singh H, Kapur K, Duggal BS, Jacob MJ. Value of PET-CT in avoiding multimodality therapy in operable cervical cancer. *International Journal of Gynecological Cancer*. 2010; 20: 1041–1045.
- [17] Kim S, Choi HJ, Park S, Lee H, Seo S, Yoo CW, *et al*. Additional value of MR/PET fusion compared with PET/CT in the detection of lymph node metastases in cervical cancer patients. *European Journal of Cancer*. 2009; 45: 2103–2109.
- [18] Leblanc E, Gauthier H, Querleu D, Ferron G, Zerdoud S, Morice P, *et al*. Accuracy of 18-fluoro-2-deoxy-D-glucose positron emission tomography in the pretherapeutic detection of occult para-aortic node involvement in patients with a locally advanced cervical carcinoma. *Annals of Surgical Oncology*. 2011; 18: 2302–2309.
- [19] Li K, Sun H, Guo Q. Combinative evaluation of primary tumor and lymph nodes in predicting pelvic lymphatic metastasis in early-stage cervical cancer: a multiparametric PET-CT study. *European Journal of Radiology*. 2019; 113: 153–157.
- [20] Lin WC, Hung YC, Yeh LS, Kao CH, Yen RF, Shen YY. Usefulness of (18) F-fluorodeoxyglucose positron emission tomography to detect para-aortic lymph nodal metastasis in advanced cervical cancer with negative computed tomography findings. *Gynecologic Oncology*. 2003; 89: 73–76.
- [21] Lv K, Guo H, Lu Y, Wu Z, Zhang K, Han J. Role of 18F-FDG PET/CT in detecting pelvic lymph-node metastases in patients with early-stage uterine cervical cancer: comparison with MRI findings. *Nuclear Medicine Communications*. 2014; 35: 1204–1211.
- [22] Ma SY, See LC, Lai CH, Chou HH, Tsai CS, Ng KK, *et al*. Delayed (18) F-FDG PET for detection of paraaortic lymph node metastases in cervical cancer patients. *Journal of Nuclear Medicine*. 2003; 44: 1775–1783.
- [23] Margulies A, Peres A, Barranger E, Perreti I, Brouland J, Toubet E, *et al*. Selection of patients with advanced-stage cervical cancer for para-aortic lymphadenectomy in the era of PET/CT. *Anticancer Research*. 2013; 33: 283–286.
- [24] Nogami Y, Banno K, Irie H, Iida M, Kisu I, Masugi Y, *et al*. The efficacy of preoperative positron emission tomography-computed tomography (PET-CT) for detection of lymph node metastasis in cervical and endometrial cancer: clinical and pathological factors influencing it. *Japanese Journal of Clinical Oncology*. 2015; 45: 26–34.
- [25] Papadia A, Gasparri ML, Genoud S, Bernd K, Mueller MD. The combination of preoperative PET/CT and sentinel lymph node biopsy in the surgical management of early-stage cervical cancer. *Journal of Cancer Research and Clinical Oncology*. 2017; 143: 2275–2281.
- [26] Perez-Medina T, Pereira A, Mucientes J, García-Espantaleón M, Jiménez JS, Calles L, *et al*. Prospective evaluation of 18-fluoro-2-deoxy-D-glucose positron emission tomography for the discrimination of paraaortic nodal spread in patients with locally advanced cervical carcinoma. *International Journal of Gynecological Cancer*. 2013; 23: 170–175.
- [27] Sarabhai T, Schaarschmidt BM, Wetter A, Kirchner J, Aktas B, Forsting M, *et al*. Comparison of 18F-FDG PET/MRI and MRI for pre-therapeutic tumor staging of patients with primary cancer of the uterine cervix. *European Journal of Nuclear Medicine and Molecular Imaging*. 2018; 45: 67–76.
- [28] Signorelli M, Fruscio R, Guerra L, Crivellaro C, Betti M, Chiappa V, *et al*. Preoperative staging of cervical cancer: is FDG PET-CT really effective in patients with ib1 stage? *International Journal of Gynecological Cancer*. 2011; 123: 236–240.
- [29] Wright JD, Dehdashti F, Herzog TJ, Mutch DG, Huettner PC, Rader JS, *et al*. Preoperative lymph node staging of early-stage cervical carcinoma by [<sup>18</sup>F]-fluoro-2-deoxy-D-glucose-positron emission tomography. *Cancer*. 2005; 104: 2484–2491.

- [30] Xu X, Li Z, Qiu X, Wei Z. Diagnosis performance of positron emission tomography-computed tomography among cervical cancer patients. *Journal of X-Ray Science and Technology*. 2016; 24: 531–536.
- [31] Yang Z, Xu W, Ma Y, Liu K, Li Y, Wang D. (18) F-FDG PET/CT can correct the clinical stages and predict pathological parameters before operation in cervical cancer. *European Journal of Radiology*. 2016; 85: 877–884.
- [32] Ramirez PT, Jhingran A, Macapinlac HA, Euscher ED, Munsell MF, Coleman RL, *et al*. Laparoscopic extraperitoneal para-aortic lymphadenectomy in locally advanced cervical cancer. *Cancer*. 2011; 117: 1928–1934.
- [33] Elit LM, Fyles AW, Gu C, Pond GR, D'Souza D, Samant R, *et al*. Effect of positron emission tomography imaging in women with locally advanced cervical cancer. *Journal of the American Medical Association Network Open*. 2018; 1: e182081.
- [34] Nama V, Angelopoulos G, Twigg J, Murdoch JB, Bailey J, Lawrie TA. Type II or type III radical hysterectomy compared to chemoradiotherapy as a primary intervention for stage IB2 cervical cancer. *Cochrane database of systematic reviews*. 2018;10: Cd011478.
- [35] Landoni F, Maneo A, Colombo A, Placa F, Milani R, Perego P, *et al*. Randomised study of radical surgery versus radiotherapy for stage IB–IIA cervical cancer. *Lancet*. 1997; 350: 535–540.
- [36] Vordermark D. Radiotherapy of Cervical Cancer. *Oncology Research and Treatment*. 2016; 39: 516–520.
- [37] Marnitz-Schulze S, Tsunoda A, Martus P, Vieira M, Affonso R, Nunes J, *et al*. 24 uterus-11 study: a randomized clinical trial on surgical staging versus ct-staging prior to primary chemoradiation in patients with FIGO2009 stages IIB–IVA cervical cancer. *International Journal of Gynecological Cancer*. 2019; 30: 1855–1861.
- [38] Zou W, Han Y, Zhang Y, Hu C, Feng Y, Zhang H, *et al*. Neoadjuvant chemotherapy plus surgery versus concurrent chemoradiotherapy in stage IB2–IIB cervical cancer: a systematic review and meta-analysis. *PLoS ONE*. 2019; 14: e0225264.
- [39] Yang S, Gao Y, Sun J, Xia B, Liu T, Zhang H, *et al*. Neoadjuvant chemotherapy followed by radical surgery as an alternative treatment to concurrent chemoradiotherapy for young premenopausal patients with FIGO stage IIB squamous cervical carcinoma. *Tumour Biology*. 2015; 36: 4349–4356.
- [40] Hazewinkel MH, Sprangers MAG, van der Velden J, van der Vaart CH, Stalpers LJA, Burger MPM, *et al*. Long-term cervical cancer survivors suffer from pelvic floor symptoms: a cross-sectional matched cohort study. *Gynecologic Oncology*. 2010; 117: 281–286.
- [41] Derks M, van Lonkhuijzen LRCW, Bakker RM, Stiggelbout AM, de Kroon CD, Westerveld H, *et al*. Long-term morbidity and quality of life in cervical cancer survivors: a multicenter comparison between surgery and radiotherapy as primary treatment. *International Journal of Gynecologic Cancer*. 2017; 27: 350–356.