

Single-site robotic-assisted hysterectomy and sentinel lymph node mapping for low-risk endometrial cancer: surgical technique and preliminary outcomes

Felix Chan^{1,*}, Cherynne Yui Mun Johansson²

¹Westmead Private Hospital and Macquarie University Hospital, 3 Technology Place, Macquarie University, NSW, 2109 New South Wales, Australia

²Minimally Invasive Gynaecological Surgery Unit, Liverpool Hospital, Elizabeth Street, Liverpool, NSW, 2170 New South Wales, Australia

*Correspondence: felix.chan@mq.edu.au (Felix Chan)

DOI:10.31083/j.ejgo4205145

This is an open access article under the CC BY 4.0 license (<https://creativecommons.org/licenses/by/4.0/>).

Submitted: 4 April 2021 Revised: 26 May 2021 Accepted: 11 June 2021 Published: 15 October 2021

The staging of endometrial cancer has changed from clinical to surgical over the years. Lymph node disease is recognised as an important prognostic factor as well as an aid to tailoring adjuvant therapy. The development of sentinel lymph node mapping algorithms shows promise in diagnostic accuracy and reducing the morbidity associated with comprehensive lymphadenectomy. In select patients, it is feasible to perform sentinel lymph node mapping using minimally invasive surgical techniques. We present a series of single-site robotic-assisted laparoscopic hysterectomy and sentinel lymph node mapping for low-risk endometrial cancer focusing on the surgical technique required and perioperative outcomes.

Keywords

Endometrial cancer; Single-site hysterectomy; Laparoendoscopic single-site surgery; Robotic single-site surgery; Sentinel node mapping

1. Introduction

Over time, endometrial cancer (EC) staging has changed from clinical to surgical-pathological [1]. Surgical staging provides more accurate information regarding the extent of disease and allows the tailoring of appropriate adjuvant therapy. The recommended surgical procedure for EC is an extra-fascial total hysterectomy with bilateral salpingo-oophorectomy. Clinical controversy exists regarding the role of nodal staging, in particular, which patients require lymphadenectomy (LND) and what determines an adequate lymph node dissection [2]. Large randomised trials have found that LND has no effect on survival for women with apparent early-stage EC [3, 4]. Furthermore, lymphadenectomy is often associated with morbidity such as injury to blood vessels and nerves, lymphoedema and lymphocyst formation, venous thromboembolism, and, as a full lymphadenectomy increases operative time, increased surgical and anaesthetic risks [5]. Concerns over the acceptability of this increased morbidity in patients with low risk EC has prompted the development of other approaches to nodal staging [6–8]. Leading the paradigm shift in EC surgical staging is the concept of sentinel lymph node (SLN) mapping. Numerous studies have demonstrated the accuracy of SLN

for EC staging [9–14]. In addition, employing an SLN mapping algorithm does not compromise short term oncologic outcomes [15]. The acceptability of this approach is reflected by the inclusion of an SLN algorithm in the 2014 National Comprehensive Cancer Network (NCCN) guidelines for the management of endometrial cancer [16].

The majority of studies involving SLN mapping reported in the literature have used multi-port laparoscopic or robotic-assisted techniques. The robotic surgical system offers 3D high-definition views, wristed instruments with increased range of motion, improved ergonomics and surgical precision, which enable surgeons to overcome the technical challenges of traditional laparoscopy [17, 18]. Furthermore, the development of laparoendoscopic single-site surgery (LESS) enables the surgeon to perform almost scarless surgery. LESS has been demonstrated to be feasible and safe for gynaecologic surgery [19–22] but is limited by technical disadvantages such as instrument collision, loss of instrument triangulation, ergonomic challenges, and need for advanced laparoscopic skills [21, 22]. Such limitations have prevented this approach from becoming a standard surgical technique and prompted the development of surgical systems which incorporate LESS with robotic surgery in order to overcome these technical difficulties [23–26].

To our knowledge, there are no current studies describing the technique of robotic assisted LESS incorporating SLN mapping in low risk EC. The objectives of this report are to present our preliminary experience via a case series of single-site robotic-assisted hysterectomy and SLN mapping using the da Vinci Xi platform, to describe the surgical technique and to analyse the perioperative outcomes of this technique.

2. Materials and methods

After approval by the Institutional Review Board, we performed a retrospective review of the medical records of patients who were surgically treated for EC via a single-site robotic-assisted laparoscopic technique utilising the da Vinci Xi robotic system (Intuitive Surgical Inc, Sunnyvale,

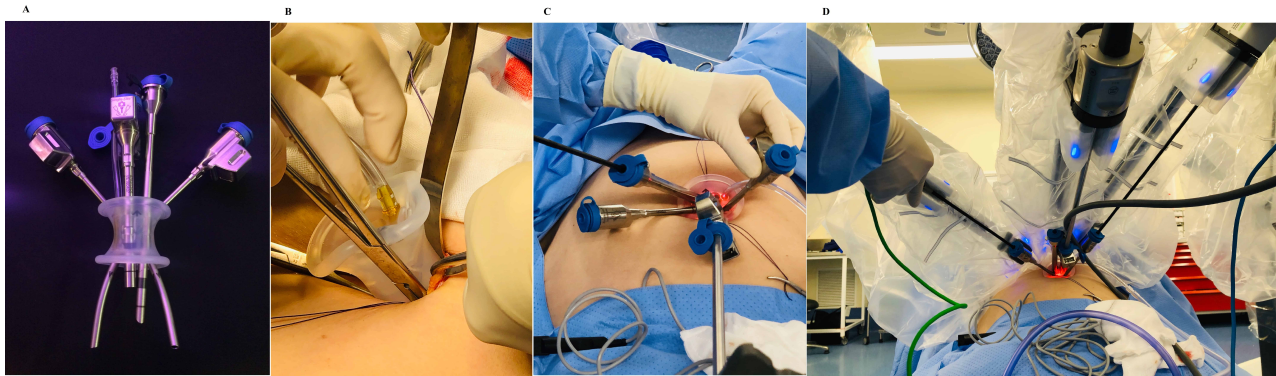


Fig. 1. Single site equipment and port placement. (A) Multi-channel Single Site Port. (B) Insertion of Gel Port. (C) Insertion of cannula under direct vision. (D) Single Site Xi port dock.

CA, USA) at Westmead Private Hospital (Westmead, New South Wales, Australia) from 1st December 2019 to 30th November 2020. All cases were performed by surgeon FC, who had performed 150 cases of single-site robotic-assisted hysterectomies prior to this series. Patients selected for this surgical approach met the following criteria: a pre-operative histological diagnosis of complex atypical hyperplasia of the endometrium or Grade 1–2 endometrioid adenocarcinoma on uterine curettage, uterine size less than 10 weeks, and BMI ≤ 35 . Data retrieved from the hospital medical records included age, body mass index, weight, previous surgeries, International Federation of Gynaecology and Obstetrics (FIGO) stage, American Society of Anesthesiologists (ASA) classification, surgical data (date, docking time, console time, time taken to close vaginal vault, intraoperative complications, blood loss, total operative time), 30-day complication rate, and pathologic information (histology, grade, myometrial invasion, pelvic node count and metastasis).

SLN mapping was performed in all cases via injection of 1.5 mLs each of 1.5 mg/mL (dilution in sterile water) Indocyanine Green (ICG) to the cervix at 3 and 9 o'clock positions. Cervical injection is easy, convenient and has been reported to have the highest bilateral detection rate [8]. For cases which fail to map with ICG, systematic lymphadenectomy would be performed. SLN specimens were submitted to ultra-staging by expert pathologists, a process involving deeper serial sections and immunohistochemical stains to increase the detection of tumour cells.

Adverse events were classified according to the Clavien-Dindo system [27]. Intraoperative morbidity was evaluated through blood loss and visceral injuries (urinary, vascular, neurologic and intestinal). Postoperative complications included infection, readmission and reoperation rates.

2.1 Single site robotic system and instruments

The da Vinci Single-Site[®] port is a multi-channel single port (Fig. 1A) which was developed to be used through a single fascial incision (Fig. 1B) and accommodates two curved instrument cannulae and a straight laparoscopic cannula which allows the use of a standard robotic 3-dimensional

8 mm (da Vinci X/Xi) or 8.5 mm (da Vinci Si) high-definition laparoscope. In addition, the da Vinci Single-Site[®] port can accommodate a 5 mm or 10 mm reusable laparoscopic accessory port (Fig. 1C,D). The curved cannulae transmit interchangeable semi-rigid instruments that cross each other within the Single-Site[®] port so that the instrument that enters on the right becomes the left-sided operative instrument and vice versa. This reversal of instrument positions is counteracted by the da Vinci surgical system automatically reassigning the instruments after docking so that the left hand of the surgeon controls the right arm of the robot and the visualised instrument on the left, and the right hand controls the visualised instrument on the right.

Unlike the conventional da Vinci Xi EndoWrist[®] instruments, the single-site robotic instruments are not wristed with the exception of the needle driver.

Moreover, single-site instruments are 5 mm in diameter in contrast to 8 mm EndoWrist[®] instruments and the entire length of single-site instruments are semi-rigid, allowing them to be inserted through the curved cannulae. The fourth generation da Vinci Xi platform incorporates improved bipolar cautery and wristed needle drivers to enhance tissue coagulation and suturing respectively.

2.2 Standardised surgical technique

A single vertical intra-umbilical incision of up to 25 mm in length is made and a modified Hasson technique used to enter the abdominal cavity. Stay sutures are placed at both angles of the rectus sheath layer to minimize the risk of port dislocation and facilitate closure at the end of the procedure. After lubricating the single-site port with water, the port is grasped using Kelly forceps just above the lower rim and inserted into the abdominal cavity through the umbilical incision. S-retractors may be used to ease the inner rim of the single-site port into the abdominal cavity (Fig. 1B). The abdomen is then insufflated and the patient is placed in a steep Trendelenburg position. The camera port is inserted and the robotic laparoscope is introduced into the abdominal cavity. Two curved cannulae, 250 mm or 300 mm long, are introduced under vision. The length of the cannulae used is

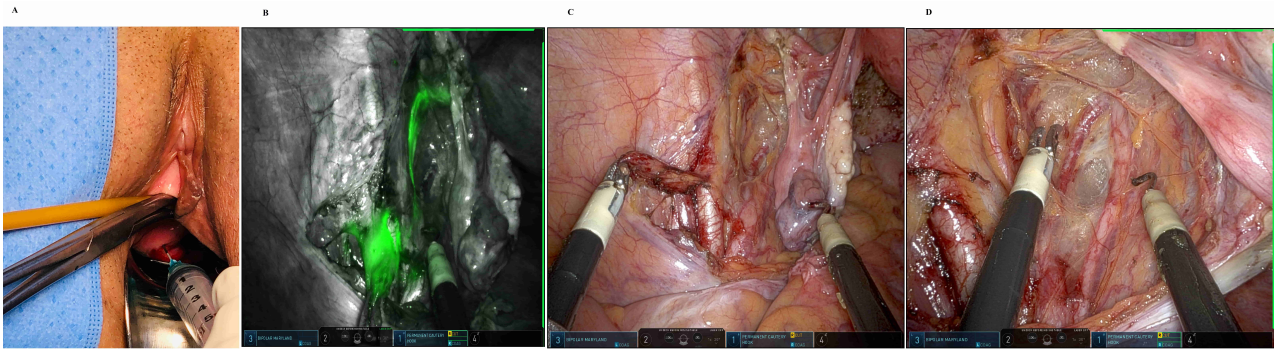


Fig. 2. Technique of Sentinel Node Mapping. (A) Injection of ICG to cervix. (B) Left common iliac Sentinel Lymph Node. (C) Removal of Sentinel Lymph Node. (D) Exposure of pelvic anatomy.

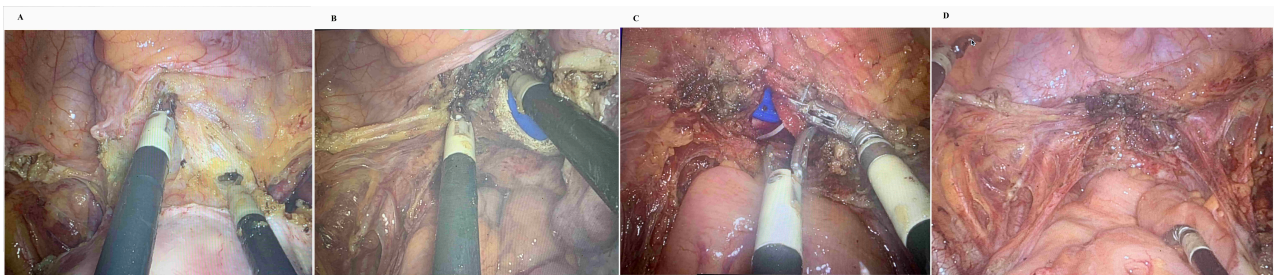


Fig. 3. Steps for hysterectomy. (A) Development of bladder flap. (B) Colpotomy using monopolar instrument. (C) Intracorporeal full thickness closure of vaginal vault. (D) Postoperative view.

chosen according to uterine size and the desired distance between the uterus and the tip of the cannulae. The da Vinci Xi robot is then docked with a lateral technique approaching from the patient's right leg (Fig. 1D). The monopolar hook and grasping forceps with bipolar capacity were then inserted through robotic arms 1 and 3 respectively, with the laparoscope docked to arm 2 (Fig. 1D).

A urinary catheter is inserted to keep the bladder empty throughout the operation and removed at the completion of the procedure. The cervix is dilated and ICG is injected as previously described (Fig. 2A). A uterine manipulator with colpotomy tube is inserted to facilitate manipulation, bladder dissection, colpotomy and retrieval of specimen. The surgeon then unscrubs to sit at the robotic surgeon console and instrument orientation is confirmed. Peritoneal fluid is collected for cytological examination.

Using our standardized surgical technique, the operation is divided into two parts: (1) SLN mapping and (2) hysterectomy and bilateral salpingo-oophorectomy. After entering the pelvic sidewall at the level of the pelvic brim, the ureters and the pelvic sidewall structures are identified. The paravesical and pararectal spaces are dissected and the sentinel drainage pathways emanating from the parametria are identified using the integrated Firefly® fluorescence capability of the da Vinci Xi robot (Fig. 2B). The most proximal lymph nodes in the sentinel pathway are the SLN (Fig. 2C), and these are mobilised away from the external iliac vessels and underlying tissues. Retraction of the external iliac vein may be needed during the dissection (Fig. 2D). The SLN specimen is

placed in the cut-off finger of a surgical glove for contained retrieval through the assistant port or transvaginally after the uterus is extracted.

As the structures of the pelvic sidewall are already dissected during SLN removal, we proceed with the extra-fascial hysterectomy. The infundibulo-pelvic ligaments and round ligaments are treated with bipolar coagulation and transected. The bladder flap is developed using the monopolar instrument (Fig. 3A). The uterine vessels are skeletonised, sealed and transected. The bladder is further dissected to a level below the colpotomy cup and circumferential colpotomy then performed with the monopolar hook (Fig. 3B). To reduce smoke during the procedure, a suction instrument can be utilized via the accessory port or a Veress needle can be inserted in the abdomen below the umbilical incision to de-sufflate the smoke. The uterus, cervix, ovaries and fallopian tubes are removed through the vagina. A wristed needle driver is then exchanged with the monopolar hook in arm 1 for vaginal cuff closure, which is performed robotically. The vaginal cuff is closed in a vertical fashion using a 2/0 V-LoCTM 15 cm suture on a 3/8 19 mm cutting needle (Medtronic, Minneapolis, MN, USA) with plication of the uterosacral ligaments (Fig. 3C). The size of the needle allows it to be introduced via the accessory port. The port and needle driver can be 'burped down' towards the vaginal vault under direct vision to enhance the driving of the needle holder. Haemostasis is checked and the pelvis is irrigated with warm water (Fig. 3D).

Table 1. Patient characteristics.

Patient	Age (years)	BMI	Number of previous intra-abdominal surgery	Pathology	FIGO stage	SLN (n)
1	69	20.4	0	G1 M1	1B	3
2	65	33.0	1	G1 M0	1A	2
3	64	27.4	2	G1 M0	1A	2
4	59	27.6	1	G2 M1	1B	3
5	54	35.0	2	G1 M1	1B	2
6	48	25.0	1	G1 M0	1A	2
7	62	31.5	1	G1 M0	1A	2
8	48	22.5	0	G1 M0	1A	3

BMI, body mass index (kg/m^2); SLN, sentinel lymph nodes.

Table 2. Operative characteristics.

Patient	Docking time (mins)	EBL (mL)	Operative time (mins)	Cuff closure time (mins)	Uterine weight (g)
1	3	5	90	5	69
2	5	10	85	6	121
3	4	20	103	8	39
4	6	25	95	10	76
5	5	50	102	5	85
6	7	25	115	6	123
7	4	20	105	7	152
8	5	10	85	6	78

EBL, estimated blood loss.

After undocking the robot, the Single-Site® port is easily removed from the umbilical incision and the fascial defect is closed using interrupted 0 polydioxanone or 0 polyglactin sutures. The umbilical skin is cleaned with antiseptic solution prior to skin closure with subcuticular 3-0 or 4-0 poliglecaprone. Speculum vaginal examination is performed to ensure haemostasis at the vault and to exclude any lacerations which may have occurred during manipulation and tissue extraction.

3. Results

A total of 8 cases with a mean age of $51.8 \text{ years} \pm 7.89 \text{ years}$ (range 48–69) and body mass index of $27.8 \text{ kg}/\text{m}^2 \pm 5.12 \text{ kg}/\text{m}^2$ (range 20.4–35) were included in our report. The clinical characteristics of these patients are summarised in Table 1. With respect to co-morbidities, one patient suffered from asthma, one had Parkinson's disease, two had thyroid disease and two had moderate to severe endometriosis diagnosed at the time of surgery. Five patients had had previous intra-abdominal surgeries including Caesarean section, cholecystectomy, appendectomy and excision of pelvic endometriosis. The indications for surgery were atypical endometrial hyperplasia with suspected invasion and Grade 1–2 endometrioid adenocarcinoma of the endometrium.

Table 2 presents the operative details for our patients. Uterine weight was $92 \text{ g} \pm 36.3 \text{ g}$ (range 39–152 g). The average estimated blood loss was $20 \text{ mLs} \pm 13.9 \text{ mLs}$ (range 5–50). Total operative time, defined as skin incision to skin closure time, was $97.5 \text{ minutes} \pm 10.6 \text{ minutes}$ (range 85–115). The mean docking time was only $4.88 \text{ minutes} \pm 1.25 \text{ minutes}$ (range 3–7) and the mean console time was 74.25

minutes $\pm 14.5 \text{ minutes}$ (range 56–100). Time required for vaginal closure was $6.63 \text{ minutes} \pm 1.69 \text{ minutes}$ (range 5–10). There were no conversions to laparoscopy or laparotomy.

Histopathology of surgical specimens confirmed Grade 1–2 endometrioid adenocarcinoma in all patients; two patients who were diagnosed with atypical endometrial hyperplasia pre-operatively were found to have Grade 1 EC. Sentinel lymph nodes were identified in all cases on both sides of the pelvis. None of the nodes collected showed metastatic disease.

All patients were discharged in less than 23 hours. There were no intraoperative complications. There was only one case of postoperative Clavien–Dindo Class I complication of diffuse redness of the umbilicus seven days after surgery and this resolved with oral antibiotic therapy. There were no emergency room visits during the 6 week postoperative period and no readmissions.

4. Discussion

Incorporation of the da Vinci Single-Site® platform into recent surgical practice has enabled the performance of gynaecologic LESS with promising results [25, 26]. It provides all the advantages of conventional LESS, including less postoperative pain, improved cosmesis, reduced length of stay and greater patient satisfaction when compared with multiport laparoscopy [19, 20, 22]. In addition, it overcomes some of the technical challenges of conventional LESS. Ergonomic difficulties and the requirement for advanced laparoscopic skills are overcome by the automatic reassignment of the single-site instruments when they are connected to the

robotic system, instrument triangulation at the surgical site is somewhat restored by the curved rigid cannulae through which the semi-rigid instruments are passed [25, 28], and the three-dimensional optical system of the da Vinci robot counteracts the loss of depth perception associated with conventional laparoscopy [23, 24].

The da Vinci Single-Site® system is not without limitations. Despite the design with the instruments crossing each other to the opposite side providing extra room, there is still limited space as well as restricted range of motion. To reduce spatial limitation, the length of cannulae can be chosen to achieve the desired distance from the uterus to the tips of the cannulae [22, 25, 28]. Moreover, the lack of wristed instruments prevents perfect triangulation and increases the difficulty of intracorporeal suturing [26].

With the development of the fourth generation da Vinci system, docking becomes faster and easier. The cannulae can be moved closer to or further from the vaginal vault. Together with the development of the wristed single-site needle driver, difficulties associated with vaginal vault closure can be overcome.

For select patients undergoing minimally invasive hysterectomy and SLN mapping for low grade EC, our preliminary data indicate that the robotic single-site approach is associated with similar perioperative outcomes as those reported in the literature. Mourkazel *et al.* [29] reported a retrospective series comparing 14 patients who underwent single-site robotic hysterectomy and SLN mapping with 13 patients who underwent multi-port hysterectomy and SLN mapping for low-risk EC. Their findings were of comparable perioperative outcomes for both groups with the single-site technique being more cost-effective. In the current report, the mean console time was 74.5 vs 136 minutes, the operative time 97.5 vs 175 minutes and the estimated blood loss was 20 mL vs 50 mL when compared with the findings of Mourkazel *et al* [29]. All patients were discharged within 23 hours of surgery and no intraoperative or significant 30 day complications were encountered in either study. Our results confirm a similar benefit with this innovative lymphatic assessment approach on the single-site robotic platform.

These findings corroborate previously published feasibility and safety data evaluating the robotic single-site platform for surgical management of EC [30]. Corrado *et al.* [30] performed a multi-institution study on robotic LESS in endometrial cancer, reporting a mean docking time of 11 minutes, mean console time of 80 minutes, average total operative time of 122 minutes and average estimate blood loss of 50 mLs. There were no conversions to laparoscopy or laparotomy and no intraoperative complications occurred. There was an 8% early postoperative complication rate. Comparing these results with the current report (mean docking time of 4.88 minutes, mean console time of 74.25 minutes, average total operative time of 97.5 minutes and mean estimated blood loss of 20 mL), robotic LESS with SLN mapping is a feasible and reproducible technique.

The NCCN recognises SLN mapping as a potential lymphatic assessment strategy for patients with apparent uterine-confined EC [31]. SLN mapping needs to have high detection rates, high sensitivity and low false negative values to be acceptable as a staging procedure and current data appear quite promising. A prospective, multi-centre cohort study (SENTI-ENDO) found a SLN detection rate of 76–77% and a detection rate per woman of 89% [9]. The sensitivity of SLN in this study was 100% per procedure but reduced to 84% per woman due to some patients failing to map. In a meta-analysis, Kang *et al.* [32] assessed SLN studies using a variety of dye injection techniques and reported a similar detection rate of 78% (95% confidence interval [CI] = 73%–84%) per procedure, with the hysteroscopic-guided sub-endometrial injection route being associated with a lower detection rate than pericervical injection. They found a sensitivity per woman of 93% with the majority of studies using ultra-staging. The multi-centre FIRES study reported a sensitivity for SLN mapping of 97.2% and a negative predictive value of 99.7%, findings which were consistent with prior smaller series and retrospective analyses with respect to accuracy [14]. SLN mapping rates may vary across institutions, but a successful bilateral mapping rate between 80–90% is often considered acceptable [33]. In the present series, we found a bilateral SLN detection rate of 100%. Although our sample size is too small to allow firm conclusions, our results suggest the feasibility of combining SLN mapping with robotic single-site hysterectomy.

SLN mapping in EC is achievable, has reasonable test performance, and lends itself to minimally invasive surgical techniques [34]. However, it should be noted that surgeon experience, using a SLN algorithm [13, 35] and adopting ultra-staging techniques on pathologic specimens are key components of successful SLN mapping [33].

5. Conclusions

The present study demonstrates that SLN mapping using a single-site robotic-assisted surgical technique can be considered for patients with low-risk endometrial cancer. Our preliminary results are promising, with minimal surgical morbidity, no conversions to laparoscopy or open surgery and 100% bilateral detection rate for SLN mapping. The long-term oncological outcomes of our patients will be studied over time as we continue to develop our experience with prospective cases. Randomised controlled trials comparing SLN mapping with the current standard which is dependent on tumour-related risk factors with or without full lymphadenectomy, are required to establish SLN mapping as a standard of care in low-risk EC. Similarly, future studies examining single-site versus multi-port robotic techniques to perform SLN mapping will further assist in determining its role in the surgical management of EC.

Author contributions

FC performed all surgical cases, reviewed the literature, co-wrote the manuscript and assisted with revision of manuscript. CYMJ was primary bedside assistant for some of the cases, performed literature review, co-wrote the manuscript and wrote the resubmission.

Ethics approval and consent to participate

Ethics approval (and waiver of consent) were granted by the Westmead Private Hospital IRB (approval number: WMP IRB 19-106).

Acknowledgment

The authors would like to thank David Lee for his surgical assistance in some of the cases and the reviewers for their feedback and opinions.

Funding

This study received no external funding.

Conflict of interest

The authors declare no conflict of interest.

References

- [1] Shepherd JH. Revised FIGO staging for gynaecological cancer. *BJOG: An International Journal of Obstetrics and Gynaecology*. 1989; 96: 889–892.
- [2] Lewin SN. Revised FIGO staging system for endometrial cancer. *Clinical Obstetrics and Gynecology*. 2011; 54: 215–218.
- [3] Panici PB, Basile S, Maneschi F, Lissoni AA, Signorelli M, Scambia G, *et al*. Systematic pelvic lymphadenectomy versus no lymphadenectomy in early-stage endometrial carcinoma: randomized clinical trial. *Journal of the National Cancer Institute*. 2008; 100: 1707–1716.
- [4] Kitchener H, Swart AMC, Qian Q, Amos C, Parmar MKB. Efficacy of systematic pelvic lymphadenectomy in endometrial cancer (MRC ASTEC trial): a randomised study. *Lancet*. 2009; 373: 125–136.
- [5] Frost JA, Webster KE, Bryant A, Morrison J. Lymphadenectomy for the management of endometrial cancer. *Cochrane Database of Systematic Reviews*. 2017; 10: CD007585.
- [6] Sala P, Morotti M, Menada MV, Cannavino E, Maffeo I, Abete L, *et al*. Intraoperative Frozen Section Risk Assessment Accurately Tailors the Surgical Staging in Patients Affected by Early-Stage Endometrial Cancer: the Application of 2 Different Risk Algorithms. *International Journal of Gynecologic Cancer*. 2014; 24: 1021–1026.
- [7] Mariani A, Dowdy SC, Cliby WA, Gostout BS, Jones MB, Wilson TO, *et al*. Prospective assessment of lymphatic dissemination in endometrial cancer: a paradigm shift in surgical staging. *Gynecologic Oncology*. 2008; 109: 11–18.
- [8] Bodurtha Smith AJ, Fader AN, Tanner EJ. Sentinel lymph node assessment in endometrial cancer: a systematic review and meta-analysis. *American Journal of Obstetrics and Gynecology*. 2017; 216: 459–476.e10.
- [9] Ballester M, Dubernard G, Lécure F, Heitz D, Mathevet P, Marret H, *et al*. Detection rate and diagnostic accuracy of sentinel-node biopsy in early stage endometrial cancer: a prospective multicenter study (SENTI-ENDO). *Lancet Oncology*. 2011; 12: 469–476.
- [10] How J, Lau S, Press J, Ferenczy A, Pelmus M, Stern J, *et al*. Accuracy of sentinel lymph node detection following intra-operative cervical injection for endometrial cancer: a prospective study. *Gynecologic Oncology*. 2012; 127: 332–337.
- [11] Jewell EL, Huang JJ, Abu-Rustum NR, Gardner GJ, Brown CL, Sonoda Y, *et al*. Detection of sentinel lymph nodes in minimally invasive surgery using indocyanine green and near-infrared fluorescence imaging for uterine and cervical malignancies. *Gynecologic Oncology*. 2014; 133: 274–277.
- [12] Sinno AK, Fader AN, Roche KL, Giuntoli RL, Tanner EJ. A comparison of colorimetric versus fluorometric sentinel lymph node mapping during robotic surgery for endometrial cancer. *Gynecologic Oncology*. 2014; 134: 281–286.
- [13] Barlin JN, Khoury-Collado F, Kim CH, Leitao MM, Chi DS, Sonoda Y, *et al*. The importance of applying a sentinel lymph node mapping algorithm in endometrial cancer staging: beyond removal of blue nodes. *Gynecologic Oncology*. 2012; 125: 531–535.
- [14] Rossi EC, Kowalski LD, Scalici J, Cantrell L, Schuler K, Hanna RK, *et al*. A comparison of sentinel lymph node biopsy to lymphadenectomy for endometrial cancer staging (FIRES trial): a multicentre, prospective, cohort study. *Lancet Oncology*. 2017; 18: 384–392.
- [15] Zahl Eriksson AG, Ducie J, Ali N, McGree ME, Weaver AL, Bogani G, *et al*. Comparison of a sentinel lymph node and a selective lymphadenopathy algorithm in patients with endometrioid adenocarcinoma and limited myometrial invasion. *Gynecologic Oncology*. 2016; 140: 394–399.
- [16] Seamon LG, Fowler JM, Cohn DE. Lymphadenectomy for endometrial cancer: the controversy. *Gynecologic Oncology*. 2010; 117: 6–8.
- [17] Escobar PF, Frumovitz M, Soliman PT, Frasure HE, Fader AN, Schmeler KM, *et al*. Comparison of Single-Port Laparoscopy, Standard Laparoscopy, and Robotic Surgery in Patients with Endometrial Cancer. *Annals of Surgical Oncology*. 2012; 19: 1583–1588.
- [18] Boggess JF, Gegrih PA, Cantrell L, Shafer A, Ridgway M, Skinner EN, *et al*. A comparison study of three surgical methods for hysterectomy with staging for endometrial cancer: robotic assistance, laparoscopy, laparotomy. *American Journal of Obstetrics and Gynecology*. 2008; 199: 360–369.
- [19] Jung YW, Kim YT, Lee DW, Hwang YI, Nam EJ, Kim JH, *et al*. The feasibility of scarless single-port transumbilical total laparoscopic hysterectomy: initial clinical experience. *Surgical Endoscopy*. 2010; 24: 1686–1692.
- [20] Yim GW, Jung YW, Paek J, Lee SH, Kwon HY, Nam EJ, *et al*. Trans-umbilical single port access versus conventional total laparoscopic hysterectomy: surgical outcome. *American Journal of Obstetrics and Gynecology*. 2010; 203: 26.e1–e6.
- [21] Kim Y, Park B, Ro D, Kim T. Single-port laparoscopic myomectomy using a new single-port transumbilical morcellation system: initial clinical study. *Journal of Minimally Invasive Gynecology*. 2010; 17: 587–592.
- [22] Sendag F, Akdemir A, Zeybek B, Ozdemir A, Gunusen I, Oztekin MK. Single-site robotic total hysterectomy: standardization of technique and surgical outcomes. *Journal of Minimally Invasive Gynecology*. 2014; 21: 689–694.
- [23] Nam EJ, Kim SW, Lee M, Yim GW, Paek JH, Lee SH, *et al*. Robotic single-port transumbilical total hysterectomy: a pilot study. *Journal of Gynecologic Oncology*. 2011; 22: 120–126.
- [24] Escobar PF, Fader AN, Paraiso MF, Kaouk JH, Falcone T. Robotic assisted laparoscopic single site surgery in gynaecology: initial report and technique. *Journal of Minimally Invasive Gynecology*. 2009; 16: 589–591.
- [25] Sendag F, Akdemir A, Oztekin MK. Robotic single-incision transumbilical total hysterectomy using a single-site robotic platform: initial report and technique. *Journal of Minimally Invasive Gynecology*. 2014; 21: 147–151.
- [26] Vizza E, Corrado G, Mancini E, Baiocco E, Patrizi L, Fabrizi L, *et al*. Robotic single-site hysterectomy in low risk endometrial cancer: a pilot study. *Annals of Surgical Oncology*. 2013; 20: 2759–2764.
- [27] Dindo D, Demartines N, Clavien P. Classification of surgical complications: a new proposal with evaluation in a cohort of 6336 patients and results of a survey. *Annals of Surgery*. 2004; 240: 205–213.

- [28] Escobar PF, Knight J, Rao S, Weinberg L. Da Vinci® single-site platform: anthropometrical, docking and suturing considerations for hysterectomy in the cadaver model. *International Journal of Medical Robotics*. 2012; 8: 191–195.
- [29] Moukarzel LA, Sinno AK, Fader AN, Tanner EJ. Comparing single-site and multiport robotic hysterectomy with sentinel lymph node mapping for endometrial cancer: surgical outcomes and cost analysis. *Journal of Minimally Invasive Gynecology*. 2017; 24: 977–983.
- [30] Corrado G, Mereu L, Bogliolo S, Cela V, Freschi L, Carlin R, *et al*. Robotic single site staging in endometrial cancer: a multi-institution study. *European Journal of Surgical Oncology*. 2016; 42: 1506–1511.
- [31] Koh WJ, Abu-Rustum NR, Bean S, Bradley K, Campos SM, Cho KR, *et al*. NCCN Clinical Practice Guidelines in Oncology: Uterine Neoplasms, Version 1.2018. *Journal of the National Comprehensive Cancer Network*. 2018; 16: 2.
- [32] Kang S, Yoo HJ, Hwang JH, Lim M, Seo S, Park S. Sentinel lymph node biopsy in endometrial cancer: meta-analysis of 26 studies. *Gynecologic Oncology*. 2011; 123: 522–527.
- [33] Abu-Rustum NR. Sentinel lymph node mapping for endometrial cancer: modern approach to surgical staging. *Journal of the National Comprehensive Cancer Network*. 2014; 12: 288–297.
- [34] Kitchener HC. Sentinel-node biopsy in endometrial cancer: a win-win scenario? *Lancet Oncology*. 2011; 12: 413–414.
- [35] Holloway RW, Abu-Rustum NR, Backes FJ, Boggess JF, Gotlieb WH, Jeffrey Lowery W, *et al*. Sentinel lymph node mapping and staging in endometrial cancer: a Society of Gynecologic Oncology literature review with consensus recommendations. *Gynecologic Oncology*. 2017; 146: 405–415.