

# Correlation of diaphragm surgical findings with preoperative CT scans in ovarian cancer

A. Pereira<sup>1</sup>, J. F. Magrina<sup>2</sup>, P. M. Magtibay<sup>2</sup>, N. I. Bassiouni<sup>2</sup>, T. Cuesta-Guardiola<sup>2</sup>, P. Magtibay III<sup>2</sup>,  
H. E. Kosiorek<sup>3</sup>; T. Perez-Medina<sup>1</sup>

<sup>1</sup>Department of Gynecology Oncology (A.P.; T.P.-M.) Puerta de Hierro University Hospital Madrid. Autonoma University of Madrid (Spain)

<sup>2</sup>Division of Gynecologic Surgery (J.F.M.; N.I.B.; T.C.-G.; P.M.III; P.M.M.) Mayo Clinic, Arizona

<sup>3</sup>Division of Health Sciences Research (H.E.K.), Mayo Clinic Arizona, Scottsdale, Arizona (USA)

## Summary

**Objective:** Correlation of diaphragm surgical findings in ovarian cancer patients with and without diaphragm metastases with pre-operative CT diaphragm findings to assess sensitivity and specificity for diaphragm disease. **Material and Methods:** A retrospective study of 120 ovarian cancer patients (60 with and 60 without diaphragm metastases at surgery), FIGO Stage IIIC or IV, undergoing cytoreductive surgery at Mayo Clinic, Arizona, between January 2000 and October 2014. All patients had preoperative imaging with CT scan of abdomen and pelvis including the lower lung fields. CTs were not reviewed retrospectively. **Results:** Among 60 patients with diaphragm metastases, preoperative CTs were positive for diaphragm disease in 17 patients, with a sensitivity rate of 28% (CI 95%: 0.17-0.41). All 60 patients with no diaphragm metastases had negative CTs, with a specificity of 100% (CI 95%: 94.0%-100%). When analyzed by lesion size, CTs were negative in 66.7-80% of patients with diaphragm lesions ranging from 1-15 mm. There was a trend towards increased detection rate with increasing size of lesions, but it did not reach significance ( $p = 0.529$ ). CT detection rate for single metastatic lesion was 18.2% (6/33) and for multiple lesions it was 25.9% (7/27). There was no difference for CT identification of right, left, or bilateral metastases ( $p = 0.399$ ). The sensitivity and specificity of CT for pleural effusion was 100% (CI 95%: 72.2%-100%) and 88% (CI 95%: 76.2%- 94.4%), respectively. The area under the receiver operating characteristic (ROC) curve was 0.680 (CI 95%: 55.3%-72.2%) for CT detection of diaphragm metastases and 0.957 (CI 95%: 79.9%-95.3%) for pleural effusions. **Conclusion:** CT has a low sensitivity and a high specificity for the prediction of diaphragm metastases in ovarian cancer. The size, location, and number of diaphragm lesions do not significantly improve CT detection rate.

**Key words:** Ovarian cancer; Diaphragm; CT scan.

## Introduction

Diaphragm disease is found in at least 50% of advanced stage ovarian cancer patients, more often in the right hemidiaphragm [1, 2]. Although complete resection of diaphragm disease, as it is for other sites of abdominal disease, has been shown to improve survival [3-5], the presence of diaphragm metastases is a commonly reported reason for suboptimal debulking [6-9]. Actually, in a survey of full members of the Society of Gynecological Oncologists, 76.3% indicated bulky diaphragm disease was a factor precluding optimal debulking, and only 24% of members performed diaphragm resections [10].

Accurate preoperative determination of diaphragm metastases would be helpful for more accurate blocking of the operating room time and planning of the operation, as well as informed consent. A specific surgeon versed in diaphragm resection could be requested ahead.

Present CT images are not sensitive enough for the detection of diaphragm metastases [8, 9] and the gynecologic oncologist is commonly faced with unexpected diaphragm

disease requiring resection. Proper training in diaphragm resection should therefore be part of gynecological oncologists operating patients with ovarian cancer. Also, there are a limited number of studies correlating surgical findings with CT images specifically for diaphragm metastases [8, 9].

The objective of this study was to correlate surgical findings with pre-operative CT images in ovarian cancer patients, with and without diaphragm metastases, to assess the sensitivity and specificity of CT with the intent to facilitate surgical planning for diaphragm resection.

## Materials and Methods

Retrospective case-control study of 120 patients (60 with and 60 without diaphragm metastases) with EOC, FIGO Stage IIIC or IV, who underwent cytoreductive surgery at Mayo Clinic, Arizona, between January 2000 and October 2014. The Mayo Clinic Institutional Review Board approved the study.

All patients had preoperative imaging with CT scan of abdomen and pelvis, including the lower lung fields, interpreted by members of the Department of Radiology specialized in CT imaging.

Revised manuscript accepted for publication December 20, 2018

Table 1. — Demographics, FIGO staging, tumor type, and grade in patients with and without diaphragm metastases.

	Patients with diaphragm metastases	Patients without diaphragm metastases	<i>p</i>
Age (years) Mean, range (min-max)	63.8 (42.0-78.0)	64.3 (45.0-78.0)	NS
BMI, Mean +/- SD	25.9+/-8.83	24.2+/-9.86	NS
FIGO Stage			
IIC	48 (80.0%)	48 (80.0%)	NS
IV	12 (20.0%)	12 (20.0%)	
Tumor grade			
I	1 (1.7%)	0 (0%)	NS
II	5 (8.3%)	4 (6.6%)	
III	54 (90.0%)	56 (93.4%)	
Histological types			
Serous	45 (75.0%)	44 (73.3%)	NS
Clear cell	4 (6.7%)	4 (6.7%)	
Endometrioid	3 (5.0%)	1 (1.7%)	
Mucinous	2 (3.3%)	2 (3.3%)	
Undifferentiated	1 (1.7%)	0 (0.0%)	
Other	5 (8.3%)	9 (15.0%)	

%: percentage; SD: standard deviation; BMI: body mass index; *p*: statistical significance; NS: non significant.

Table 2. — Decision matrix: correlation of diaphragm surgical findings with CT.

Diaphragm metastases at surgery			
CT findings	Yes, n (%)	No, n (%)	Total
Positive	TP: 17 (28.3%)	FP: 0 (0.0%)	17
Negative	FN: 43 (71.7%)	TN: 60 (100%)	103
Total	60	60	120
Basic measures of performance of diagnostic tests			
Sensitivity	Specificity	PPV	NPV
95 percent confidence interval			
28.3 (18.5-40.8)	100 (94.0-100)	100 (81.6-100)	58.3 (48.6-67.3)
Accuracy			
64.2			

*n*: number of patients; %: percentage; TP: true positive; FP: false positive; FN: false negative; TN: true negative.

Default slice thickness on the CT scanners was 3.75 mm during the years of study.

Data collected included age, BMI, tumor type and grade, FIGO Stage, pre-operative CT diaphragm results, diaphragm findings at surgery, and pathology reports. Surgical findings such as lesion size, number of lesions, peritoneal or full thickness involvement, and absence of disease were correlated with pre-operative CT scan findings.

The data was summarized using standard statistical analysis. Associations were evaluated using chi-square test and Fisher's exact test. *P* values less than 0.05 were considered statistically significant. Comparisons between the study patients vs. controls with no diaphragm disease at surgery was conducted using the non-parametric Wilcoxon rank sum test to compare for population mean shift between two groups for continuous variables, and the Pearson Chi-squared to test for proportion differences for categorical variables. The significance level was at 0.05.

Basic measures of performance of diagnostic tests: sensitivity (positivity in disease) is defined as the number of true positive decisions/the number of actually positive cases, while specificity (negative in health) is the number of true negative decisions/the number of actually negative cases. The positive predictive value (PPV) is defined as the probability of disease for positive test results, and the negative predictive value (NPV) as the probability of being healthy for negative test result. Sensitivity and specificity, the PPV and NPV, and false positive and negative rates (FPR; FNR) was calculated.

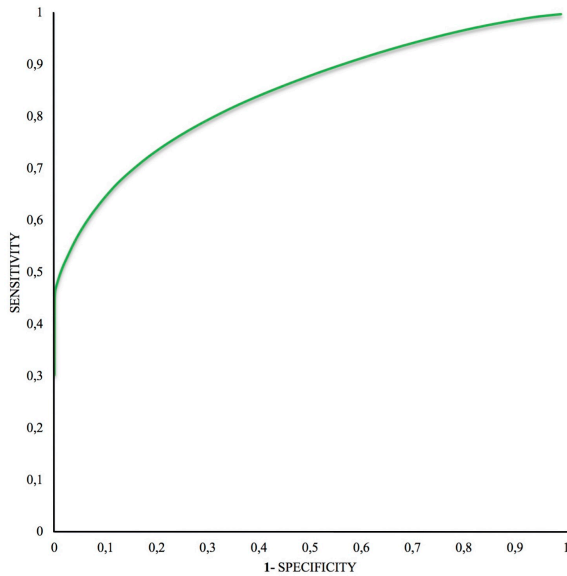
A receiver operating characteristic (ROC) curve and the area under the ROC curve (AUC) was used to evaluate the perfor-

mance of diagnostic test. In a ROC curve the true positive rate (sensitivity) is plotted in function of the FPR (1-specificity) for different cut-off points of a parameter. AUC can take on any value between 0 and 1, the better result for a diagnostic test was considered the closet AUC to 1, while the lower limit for the AUC is 0.5. Statistical Analyses were performed using the statistical software packages SAS Studio version 9.3, and R version 3.1.2.

## Results

A total of 120 patients underwent cytoreductive surgery for primary EOC. Sixty of them underwent resection of diaphragm metastases and the remaining 60 had no diaphragm disease. There were no differences relative to age, BMI, FIGO stage, tumor type or tumor grade (Table 1). The correlation of diaphragm surgical findings with CT scans is shown in Table 2. Preoperative CT images were positive for diaphragm disease in 17/60 patients with diaphragm metastases, for an overall sensitivity of 28.3% (CI 95%: 18.5%-40.8%). All 60 patients without diaphragm disease at surgery had negative CTs for a specificity of 100% (CI 95%: 94.0%-100%). The PPV, NPV, and accuracy are shown in Table 2. The ROC curve is drawn in Figure 1 (AUC=0.680, CI 95%: 55.3%-72.2%).

The correlation of the location of diaphragm metastases



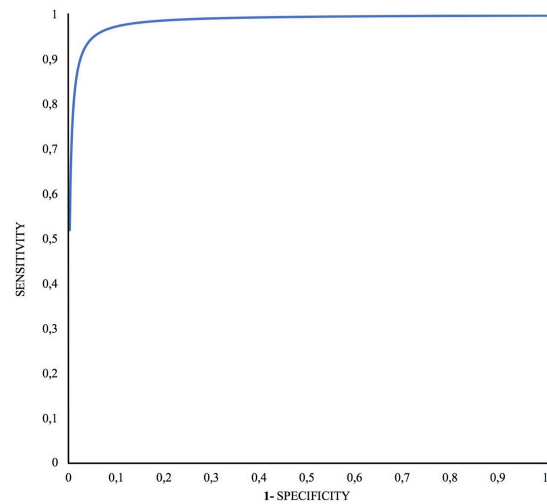
Area under the receiver operating characteristic curve: 0.680 (CI 95%: 55.3%-72.2%)

Figure 1. — ROC curve for CT diaphragm evaluation. ROC: receiver operating characteristic; CI: confidence interval.

at surgery with CT is shown in Table 3. At surgery, the right diaphragm was involved in 80% (48/60) of patients, followed by bilateral involvement in eight (13.3%), and left diaphragm in four (6.7%) patients. CT was interpreted as negative in four (50%) of eight patients with bilateral involvement, in all four (100%) patients with left disease, and in 35 (72.9%) of 48 patients with right metastases. CT correctly identified diaphragm disease in 50% (4/8) of patients with bilateral metastases, in ten (20.8%) of 48 patients with right side disease and in none (0%) of four patients with left lesions. There was no statistically significant difference for CT identification of right, left, or bilateral disease ( $p = 0.399$ ).

The correlation of CT findings with the size of diaphragm metastases is shown in Table 3. CT was interpreted as negative in 66.7%-80% of patients with diaphragm lesions ranging from 1-15 mm. There was a trend towards increase detection rate of diaphragm disease by CT with increasing size of lesions but it did not reach significance ( $p = 0.529$ ). Single and multiple lesions were noted in 33 (55%) and 27 (45%) of patients, respectively. CT detection rate for single metastatic lesions was 18.2% (6/33) and for multiple lesions was 25.9% (7/27).

Findings of pleural effusion at surgery were correlated with preoperative CT images. The sensitivity and specificity of CT for pleural effusion was 100% (CI 95%: 72.2%-100%) and 88% (CI 95%: 76.2%-94.4%), respectively. The PPV, NPV, and accuracy are shown in Table 4. The ROC curve is drawn in Figure 2 (AUC=0.957, CI 95%: 79.9%-95.3%).



Area under the receiver operating characteristic curve: 0.957 (CI 95%: 79.9%-95.3%)

Figure 2. — ROC curve for CT pleural effusions evaluation. ROC: receiver operating characteristic; CI: confidence interval.

## Discussion

This study is different from others [6, 8, 9] analyzing CT findings of the entire abdomen in a single group of patients with ovarian cancer to determine sensitivity and specificity for optimal or suboptimal resectability. This study was directed to (1) correlate only the diaphragm surgical findings with preoperative CT diaphragm results, (2) the authors included two groups of patients, one with and one without diaphragm metastases, (3) CT images were not re-interpreted retrospectively as to reproduce daily clinical practice, and (4) the main purpose was to assist in surgical planning instead of assessing for resectability or lack thereof. Given that diaphragm metastases are a common reason for incomplete debulking among gynecologic oncologists [10], accurate preoperative detection would be highly beneficial to increase the rate of optimal or complete debulkings.

Previous studies found a CT sensitivity and specificity for diaphragm disease ranging from 48-58% and 87-100%, respectively [8, 9]. Glaser *et al.* found a sensitivity of 48% (15/31) and specificity of 100% (15/15), while Meyer *et al.* [9] reported 54% sensitivity (7/13) and 87% specificity (13/15).

Studies have found the combination of diaphragm metastases with other CT findings highly predictable of the surgical effort. In combination with ascites are predictors of incomplete debulking (specificity 80%; PPV 76.9%) [7]; in association with ascites and deep peritoneal thickening are also predictors of suboptimal debulking (sensitivity

Table 3. — Correlation of location of diaphragm metastases at surgery with CT and between the size of diaphragm metastases at surgery with CT.

Location of diaphragm metastases at surgery						
CT findings	Bilateral	Left	Right	<i>p</i>		
Positive	1 (12.5%)	0 (0.0%)	3 (6.2%)	NS		
Negative	4 (50.0%)	4 (100%)	35 (72.9%)			
Both	3 (37.5%)	0 (0.0%)	10 (20.8%)			
Size of metastatic implants						
CT findings	1-5 mm	5-10 mm	10-15 mm	15-20 mm	>20 mm	<i>p</i>
Positive	7 (28.0%)	6 (33.3%)	2 (20.0%)	1 (50.0%)	1 (100.0%)	NS
Negative	18 (72.0%)	12 (66.7%)	8 (80.0%)	1 (50.0%)	0 (0.0%)	

*p*: statistical significance; NS: non significant.

Table 4. — Decision matrix: correlation of pleural effusion at CT with surgery in patients with diaphragm metastases.

Pleural effusions at surgery				
CT findings	Yes, n (%)	No, n (%)	Total	
Positive	TP: 10 (100%)	FP: 6 (12.0%)	16	
Negative	FN: 0 (0.0%)	TN: 44 (88%)	44	
Total	10	50	60	
Basic measures of performance of diagnostic tests				
Sensitivity	Specificity	PPV	NPV	Accuracy
95 percent confidence interval				
100 (72.2-100)	88 (76.2-94.4)	62.5 (38.6-81.5)	100 (92-100)	90

*n*: number of patients; %: percentage; TP: true positive; FP: false positive; FN: false negative; TN: true negative.

44% and specificity 95%) [6], and in combination with omental cake are highly predictive for tumor dissemination and thus a high likelihood of extensive surgery [8].

In this study CT images were not re-examined retrospectively to reproduce daily clinical practice, at a difference from other studies where they were re-reviewed but without knowledge of operative findings [6-9]. The present authors determined CT sensitivity in patients with known diaphragm disease, while specificity was analyzed in patients with surgically negative diaphragms. CT sensitivity was very low 28% (CI 95%: 18.5%-40.8%) while specificity was very high 100%. Also, the AUC are close to the lower limit for a diagnostic test. This may be due to the lack of re-interpretation of the CT scans, the non-bulky disease of many diaphragmatic lesions, or the "sandwich" effect of lesions adherent to both diaphragm and liver. The location (right, left, or both diaphragms), number (single or multiple), and size of the metastatic lesions did not impact on sensitivity. In contrast, CT was found to be highly sensitive for the detection of pleural effusion among the 60 patients with diaphragm metastases, 100% (CI 95%: 72.2%-100%), while specificity was 88%, and the AUC are close to 1 indicating the best result for a diagnostic test. Glasser *et al.* reported a similar specificity 87% (13/15) but a lower sensitivity of 65% (20/31).

MDCT is multidetector CT is the technique of choice for evaluating the presence of peritoneal metastases, with increased accuracy over single CT [11, 12]. Although FDG-PET/CT has a similar accuracy as CT in the preoperative evaluation of patients suspected of EOC, it is preferred for

monitoring the therapeutic response and disease recurrence after initial documentation of disease [12]. PET-CT has been demonstrated to be useful for the diagnosis of node metastases, but is limited for the detection of peritoneal implants less than 10 mm, therefore not recommended for pre-operative work up [13].

Whole-body diffusion-weighted MRI (WB-DWI/MRI) has also been proposed as a preoperative diagnostic tool for resectability [13]. Among its advantages are good inter-observer agreement and improved detection of peritoneal metastases and retroperitoneal nodal disease when compared to CT.

Potential limitations of this study, in addition to its retrospective nature, must be acknowledged when interpreting results. The diameter, not the thickness of the lesions, was used in the analysis, which may lower sensitivity and, therefore, superficial implants may remain undetected. In patients with multiple metastases, the overall size of the resected lesions was accounted for instead of the single largest lesion.

In conclusion, preoperative CT has a low sensitivity and high specificity for the detection of diaphragm metastases in EOC. The size, location, and number of diaphragm lesions do not influence CT detection rate.

## References

- [1] Fanfani F., Fagotti A., Gallota V., Ercoli A., Pacelli F., Constantini B., *et al.*: "Upper abdominal surgery in advanced and recurrent ovarian cancer: Role of diaphragmatic surgery. *Gynecol Oncol.* 2010 Mar;116:497-501.
- [2] Nougaret S., Addley H.C., Colombo P.E., Fujii S., Al Sharif S.S.,

- Tirumani S.H., Jardon K., Sala E., Reinhold C.: "Ovarian carcinomatosis: how the radiologist can help plan the surgical approach". *Radiographics*, 2012, 32, 1775.
- [3] Aletti G.D., Dowdy S.C., Gostout B.S., Jones M.B., Stanhope C.R., Wilson T.O., et al.: "Aggressive surgical effort and improved survival in advanced-stage ovarian cancer". *Obstet. Gynecol.*, 2006, 107, 77.
- [4] Tsolakidis D., Amant F., Van Gorp T., Leunen K., Neven P., Vergote I.: "Diaphragmatic surgery during primary debulking in 89 patients with stage IIIB-IV epithelial ovarian cancer". *Gynecol. Oncol.*, 2010, 116, 489.
- [5] Eisenhauer E.L., Abu-Rustum N.R., Sonoda Y., Levine D.A., Poynor E.A., Aghajanian C., et al.: "The addition of extensive upper abdominal surgery to achieve optimal cytoreduction improves survival in patients with stages IIIC-IV epithelial ovarian cancer". *Gynecol. Oncol.*, 2006, 103, 1083.
- [6] Dowdy S.C., Mullany S.A., Brand K.R., Huppert B.J., Cliby W.A.: "The utility of computed tomography scans in predicting suboptimal cytoreductive surgery in women with advanced ovarian carcinoma". *Cancer*, 2004, 101, 346.
- [7] Jung D.C., Kang S., Kang M.J., Park S.Y., Kim H.B.: "Multidetector CT predictors of incomplete resection in primary cytoreduction of patients with advanced ovarian cancer". *Eur. Radiol.*, 2010, 20, 100.
- [8] Glaser G., Torres M., Kim B., Aletti G., Weaver A., Mariani A., et al.: "The use of CT findings to predict extent of tumor at primary surgery for ovarian cancer". *Gynecol. Oncol.*, 2013, 130, 280.
- [9] Meyer J.I., Kennedy A.W., Friedman R., Ayoub A., Zepp R.C.: "Ovarian Carcinoma: value of CT in predicting success of debulking surgery". *Am. J. Roentgenol.*, 1995, 165, 875.
- [10] Eisenkop S., Spirtos N.: "What are the current surgical objectives, strategies, and technical capabilities of gynecologic oncologists treating advanced epithelial ovarian cancer". *Gynecol. Oncol.*, 2008, 108, 287.
- [11] Pannu H.K., Bristow R.E., Montz F.J., Fishman E.K.: "Multidetector CT of peritoneal carcinomatosis from ovarian cancer". *Radiographics*, 2003, 23, 687.
- [12] Funicelli L., Travaini L.L., Landoni F., Trifiro G., Bonello L., Bellomi M.: "Peritoneal carcinomatosis from ovarian cancer: the role of CT and [<sup>18</sup>F]FDG-PET/CT". *Abdom. Imaging*, 2010, 35, 701.
- [13] Kyriazi S., Kaye S.B., deSouza N.M.: "Imaging ovarian cancer and peritoneal metastases—current and emerging techniques". *Nat. Rev. Clin. Oncol.*, 2010, 7, 381.

## Corresponding Author:

A. PEREIRA, M.D.,  
Puerta de Hierro University Hospital Madrid, Spain  
Autonoma University of Madrid, Spain  
C/ Manuel de Falla, 1  
28222 Majadahonda, Madrid (Spain)  
e-mail: apereiras@sego.es