EJGO European Journal of Gynaecological Oncology

Original Research

Clinical analysis of intramural papilloma treated with mammotome atherectomy guided by ductoscope

H. Wu[1], S. Yu[1], Y. Zhang[1], Y. Yang[1]

[1]*People's Hospital of Ningxia, Yinchuan, Ningxia (China)*

Summary

This article reports a study on 36 cases of papilloma in lactiferous ducts that were treated with mammotome minimal invasive atherectomy during the year 2015 and the three-year post-surgery follow-up assessments. It compared the pros and cons of procedures with mammotome atherectomy and those with traditional methylene blue staining and localization wire guiding and showed that mammotome atherectomy has a marked advantage according to accuracy, degree of trauma, as well as in keeping the breast integrity and shape. Another advantage of mammotome atherectomy is that its sequelae is insignificant, since almost no cyst will be formed after the procedure. Its shortcoming lies in blood-stopping mechanism.

Key words: Lactiferous ductoscope; Papilloma; Mammotome atherectomy.

Introduction

Papillomata in lactiferous duct are often found with parous women, particularly those between 40- and 50-years -old, and 75% cases are found in I-II level ducts and in the ampullas close to the nipples. Usually they are benign and their malignant rate is 10% [1]. Their main clinical feature is painless nipple discharge, which can be hematic, yellowish-serous or colorless aqueous. They are mainly treated with open surgical procedures. The traditional surgical method was to inject methylene blue via nipple discharging opening and to follow the directions of the needle head or the methylene blue colored spot to remove the quadrant or segmental breast tissue. Since the application of ductoscopy, the method has been upgraded to using ductoscope to insert a localization wire into papilloma-located duct and, at the outer edge of areola toward which the guide wire goes, resect the lesioned duct as well as the local breast tissue. From January 2015 to December 2015 Ningxia People's Hospital performed 36 mammotome atherectomy surgeries. Guided by ductoscope, the incisions began at the location where the tumor existed in the duct and reached the outer edge of the breast to the center. The following is the report in detail.

Materials and Methods

General data: All patients were female, aged 35-67, and their median age was 41. The authors selected from their outpatients that were diagnosed, by using ductoscope, with space-occupying lesions in the lactiferous ducts, and the samples were all single breast, single-hole nipple discharge, single-duct, and single-tumor, or multiple tumor at same location in the duct. Conventional B-ultrasound found 28 cases of mammary duct ectasia and eight cases of possible papillomata. Conventional molybdenum target check of the 36 patients did not find signs of malignancy such as sand-like microcalcification or mustered glands, but 21 BI-RADS III and 15 BI-RADS II were found. Then the 21 BI-RADS III patients were examined with MRI; the reports being that there were 18 cases of duct expansion with space-occupying lesion inside the ducts, and three cases of simple duct expansion. Among the 36 cases 18 were single-breast and single-hole with bloody nipple discharge, 15 cases were single-breast and single-hole yellowish serous nipple discharging, and three were single-breast single-hole watery nipple discharging. As for the locations of the tumors, five were in the main ducts, 21 were inside duct I, and ten were inside duct II. There were 33 cases of single-duct single-tumor; and there were three cases of two tumors in two adjacent ducts that were in the same location. As for the shapes, seven cases were strawberry-shaped, 21 cherry-shaped, and 8 cases were mulberry-shaped.

After routine sterilization, FVY-780 ductoscope was inserted from the discharging duct to conduct a gradual check. When the tumors were found, 32 out of 36 were smooth in the surface and the texture were soft; the texture of the remaining four were medium, and all the tumors could move back and forth in the ducts at a small scale. The walls of the lactiferous ducts where the tumors were found were smooth, elastic, had reasonable dilatation, and there were no sign of bloody discharge from the upper ducts [2]. When the scope-guided diagnosis was completed, the ductoscope was removed and the discharging opening(s) were marked, before discussing with the patients, signing the informed consents, and making appointments for outpatient surgery. On the day of the procedure, routine sterilization was performed before ductoscope was inserted through the marked discharging opening. The ductoscope carried a localization shell, which was fixed after the scope was taken out. Then 1-2 ml of air was injected into the duct, and the incision spot was determined by moving the B ultrasound probe from outer edge of

Published: 15 February 2020

Eur. J. Gynaecol. Oncol. - ISSN: 0392-2936
XLI , n. 1, 2020
doi: 10.31083/j.ejgo.2020.01.5035

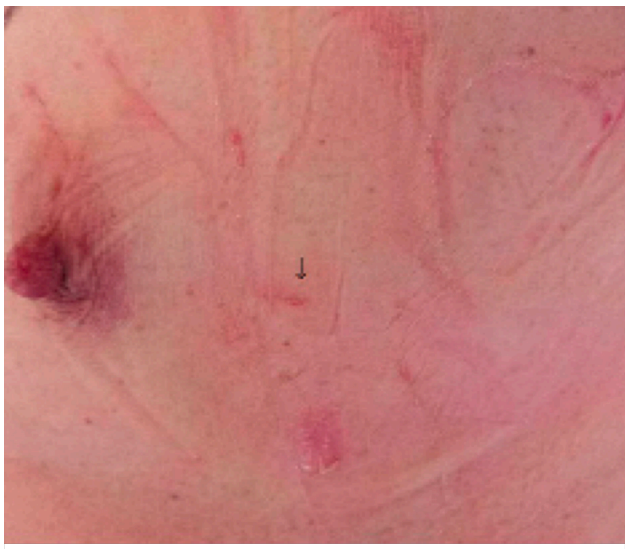

Figure 1. — Incision scar (pointed by the arrow) is almost invisible with mammotome minimal invasive atherectomy.

the breast to find the localization shell and the hyperecho area of the air. When local anesthesia was done with lidocaine injection, a 2-mm incision (Figure 1) was cut with a no. 11 scalpel and mammotome rotary scalpel was introduced and guided by B ultrasound, and aligned well in the same level line with the localizer. Then the localization shell was removed and the rotary scalpel was turned on to cut 4-7 times in the upper, lower, left, and right directions to remove the focal zone that was indicated by the B ultrasound before removing the mammotome. When the ductoscope was once again introduced into the marked opening, the tumor(s) as well as the duct where the tumor located were found to have been removed. The incision was closed with pressed elastic gauze bandage when bleeding was visualized and the removed tissue was sent for pathological examination. The bandage was removed three days later. If no blood was found by B-ultrasound in the surgical area, a follow up would be scheduled in three months, otherwise a B-ultrasound-guided suction would be applied immediately. If the bleeding was more than 5 ml, then after the suction hemocoagulase was injected or needle drainage was indwelled and close follow-ups were scheduled.

Results

Among the 36 cases, 31 were reported to be papillomata and five were adenosis with ductal ectasia. Six were found to have an active epithelium hyperplasia. The following are the results of a comparison between the present study and 28 cases of partial excision with localization wire implantation in this hospital and 30 cases of segmental resection or lobectomy with injected methylene blue that were carried out in another local top-three hospitals.

By using Chi-square the authors performed a differential analysis of the three groups of cysts to assess whether they would cause sequelae. Conclusions can be drawn from the above results. There was a 0 grid where the expected frequency was less than 5, the minimum expected frequency was 10.43, and n = 94 > 40, c^2=25.391, the degree of freedom was $df = 2$, $p = 0.000 < 0.005$, with α level = 0.05 to reject H0, and there were significant differences. It therefore indicates that minimal invasive atherectomy has the best effect while wire localization has the worst effect, as it causes the most sequelae in sack formation.

With the aforementioned results and with a difference of bleeding complications in the three groups, conclusions can be made that there were three grids with an expected frequency less than 5, the minimum expected frequency was 2.38, and n = 94 > 40, c^2=2.346, degree of freedom df = 2, $p = 0.338 > 0.005$, with a level = 0.05 to accept H0, and there was no evident difference. Therefore, three types of treatments have no obvious difference regarding bleeding complications.

Up until the time this research article was submitted, that is, over three years, only two cases of those who had been treated with the minimal invasive atherectomy were found during the follow-ups to have sequelae such as tiny cysts within. During the follow-ups the duct scope was smoothly thrusted into the same locations where the treatments had been done.

Discussion

Given the fact that although papillomata in milk ducts are benign, there is a 6-8% malignant rate; hence surgical resection is inevitable [3], and the selection of surgical methods is very important.

Traditional methylene blue staining surgery has a certain degree of blindness, especially when the tumors are large enough to block the milk ducts which forces the methylene blue injected into normal bordering ducts, which leads to

Table 1. — *Comparison between methylene blue staining, wire localization and minimally invasive atherectomy.*

	Accuracy	Traumaticity	Cyst formation sequelae	Bleeding complication	Appearance of breast	Length of incision	Revision with ductoscope
30 excision with dye	Blind	Removed quadrant or segment	16 (53.33%)	2 (6.67%)	Lack of quadrants appears as large area collapse	3-4cm	Scope could not go in
28 wire localization	Regional position	Removed gland lobules to which duct belongs	17 (60.71%)	1 (3.57%)	Local dents	2-3cm	Scope could not go in
36 minimal invasive atherectomy	Accurate	Removed lesion-infected duct(s)	2 (8.42%)	5 (13.89%)	Intact	2mm	Scope could easily go in

Figure 2. — Incision scar left by traditional surgical treatment applied in the areola area affects breast integrity and aesthetics.

not only unnecessary removal of adjacent normal or dilated ducts, but also to a possibility of 9% of tumors being missed [4].

Although wire localization is performed directly under the scope, yet owing to the body of the scope and the diameter of the localization shell, only single-hooked localization needle can be placed and, when retreating the scope, a loose and mobile breast may be encountered. Activities before the procedure, disinfecting at the time of surgery and tearing off adhesive tapes that were used for positioning, etc., all make it simple to slide and shift the positioning needle. Likewise, the positioned needle implantation uses a rotary cutter that gradually moves around the positioning pin to cut the tumor and the milk duct, the adherent gland, and the interstitial tissue. It is also simple to cause the positioning guide wire to shift or slip off and thereby miss the tumor or mistakenly cut the normal breast tube. Breast ductoscopy guided mammotome atherectomy is real-time positioning, which does not allow for shifting, especially under the guidance of B-ultrasound, the scalpel directly reaches the duct where the positioning shell locates to remove the tumor. Compared to methylene blue and guidewire, it is accurate and direct.

In as much as methylene blue staining is for quadrant and sectional tissue resection, the amount of tissue removed is large and its trauma is naturally extensive. Localization wire-guided resection is a local resection of the tumor-residing duct and the glandular lobe(s) to which it belonged to; the amount of tissue resected is therefore smaller compared to that of methylene blue staining method. The ductscope-guided minimally invasive atherectomy removes only the diseased milk duct and a small amount of tissue, hence compared to methylene blue staining and positioning guidewire, the trauma is naturally smaller (Table 1).

Mammotome atherectomy incision is performed around the mammary gland, at the distal branch of the milk duct, and it resects only the diseased milk duct; it has less damage to the adjacent normal ducts and therefore it has small probability of cyst formation. On the contrary, methylene blue staining and guidewire localization select incisions in the areola area and it is simple to cut off the main duct(s) [5] and increases the chance of cyst formation in the lower ducts that are subordinated to the main duct(s).

Intraductal papilloma is featured with (potential) regeneration in other ducts [6], and when methylene blue staining and guidewire localization are performed in the areola area, the main duct is cut off; therefore when tumor is regenerated in the branch duct that belong to the main duct located in the same location, the ductoscope cannot be inserted because of the rupture of the main duct, leading to the fact that regenerative lesions can no longer be diagnosed and localized by breast ductoscopy. On the contrary, mammotome atherectomy is made at the peripheral area of the breast, and both cut and resection are level III-IV or in distal milk ducts; therefore the main duct is not damaged and it does not affect the re-diagnosis and localization of the lesions in the branch duct.

Methylene blue staining and guidewire localization are open surgery. The trauma area is large, blood loss is in a large amount, the physical and psychological impact on the patient is great, and the probability of infection in the corresponding cavity is likely to increase. However, these two are open surgery and angiography and can be eye-directed to stop bleeding. Compared to mammotome atherectomy, the intraluminal bleeding is low, only 1%. Mammotome atherectomy, on the other hand, locally uses elastic bandage to stop bleeding, which, when encountered with large blood vessels in the affected area and when there is a deviation in the pressurized center of gravity, the probability of bleeding is larger than in the aforementioned two methods; as found in this group, it was 13.89%. Nevertheless three days after the procedure, as well as at later times, the authors followed up with B-ultrasound and remediated by such measures as suction, drainage, and injection of hemagglutinin.

Since methylene blue staining and guidewire positioning are used to remove the quadrant or segment, it is simple to cause deficiency in the breast quadrant or a large area collapse and local depression. In addition, the incision scar is large and obvious, affecting breast integrity and its aesthetic appearance (Figure 2). Mammotome atherectomy, on the other hand, is a minimally invasive resection of the diseased breast duct and a small amount of tissue, thereby the incision is only 2-3 mm with good skin texture. There are almost no marks left in the patient after three months, therefor breast integrity and aesthetics remain intact.

From the data of this group, the authors found the limitations of mammotome atherectomy lies in that it can only remove lesions that are seen by the milk ductoscope 1.5–5 cm from the nipple, and the diagnosis under the microscope

tends to deal with benign single tumor or multiple tumors in adjacent ducts in the same location. The learning curve will continue in order to draw lessons from patients who have undergone mammotome atherectomy and step-by-step, we will improve both surgical skills and patient satisfaction.

In summary, mammotome atherectomy has certain limitations, but compared to traditional methylene blue staining and localization wire-guiding, it is minimally invasive, precise, fast, less painful, and has less sequelae. The value of its clinical application exists in that it does not affect the follow-up re-diagnosis and localization with breast ductoscopy and it keeps the breast(s) intact and aesthetically pleasing.

References

[1] Dong Yan, Sun Lingling, Zhao Man, Yue Ling: "A comparative study of MRI of intraductal papilloma of the breast with fiberoptic ductoscopy and ultrasound". *Modern Oncology,* 2013, *21*, 1938.
[2] Shen Zhenzhou, Shao Zhimin (eds). *In: Breast Tumor*. 1st ed. Shanghai: Shanghai Scientific & Technical Publishers, 2005.
[3] Mang Jian-bo, Mai Hui-qing, Zhou Dong-xian, Zhang Ya-yuan: "Treatment under the guidance of ductoscopy for intraductal papilloma". *Proceeding of Clinical Medicine*, 2010, *19*, 986.
[4] Shen K.W., Wu J., Lu J.S., Han Q.X., Shen Z.Z., Nguyen M., *et al.*: "Fiberoptic ductoscopy for patients with nipple discharge". *Cancer*, 2000, *89*, 1512.
[5] Geng Hong-tao, Zhao Guang-cai, Feng Jia: "Breast intraductal papilloma resection under breast fiberoptic duct". *China Practical Medicine*, 2010, *5*, 45.
[6] Xu Liangzhong: *Breast Pathology*. Shanghai: Shanghai Medical University Press, 1999.

Corresponding Author:
HONGLI WU, M.D.
Department of Breast Surgery,
People's Hospital of Ningxia 301 N
Zhengyuan Street Jinfeng District,
Yinchuan Ningxia, 750002 (China)
e-mail: wuhong_li2015@163.com