

SIRT1 is overexpressed in endometrial adenocarcinoma: a tissue microarray analysis

Jaudah Al-Maghrabi^{1,2}, Haneen Al-Maghrabi²

¹Department of Pathology, Faculty of Medicine, King Abdulaziz University, Jeddah 21589, Saudi Arabia

²Department of Pathology, King Faisal Specialist Hospital and Research centre, Jeddah 21499, Saudi Arabia

Summary

Silent mating type information regulation 2 homolog-1 (SIRT1) is a member of sirtuin family. Its role in endometrial carcinoma (EC) is controversial and unclear. This study aims to define the SIRT1 immunoeexpression pattern in endometrial carcinoma (EC), its relationship with clinicopathological features, and its prognostic significance. A tissue microarray was constructed and contained 71 endometrial carcinomas, 28 endometrial hyperplasia, and 30 normal endometrial tissues. An immunostaining study was completed using anti-SIRT rabbit polyclonal antibody. SIRT1 immunoeexpression was scored and analysed. Positive immunostaining was found in 29 of the 71 (40.8%) endometrial carcinomas and in 7 of the 58 (12.1%) nonneoplastic endometrial tissues. SIRT1 immunoeexpression findings were not related to age, histological type, tumor size, myometrial invasion, lymphovascular invasion, surgical resection margin, lymph node metastasis, FIGO staging, local recurrence or survival. In endometrial carcinoma, SIRT1 immunoeexpression is expressed at greater levels in malignant endometrial tissue than in hyperplastic and normal endometrial tissues. However, no relationship was found between SIRT1 expression and other clinicopathological parameters. More studies are needed to explore the role of SIRT1 in ECs.

Key words: Endometrium; Tissue microarray; Immunohistochemistry; SIRT1.

Introduction

Endometrial carcinoma (EC) is a common neoplasm worldwide [1]. In Saudi Arabia, EC ranked 5th among females malignancies [2]. Pathologically, the commonest histopathological type of endometrial carcinoma is endometrioid carcinoma which account for 70% [3]. The 5-year overall survival in patients without metastasis ranges between 74 to 91%, while it reaches to as low as 20% in cases with metastasis [4]. Investigations of the molecular biomarkers that could be involved in EC pathogenesis is important because the most common cause of death in EC patient is the presence of chemotherapy resistant metastasis [5].

Silent mating type information regulation 2 homolog1 (SIRT1) is a key member of sirtuin family [6]. SIRT1 plays an important role in tumorigenesis in some cancers [6, 7]. SIRT1 was classified as a tumor promotor or tumor suppressor based on the oncogenic pathway of different malignancies [8]. Overexpression of SIRT1 was detected in many human solid neoplasms, such as non-small cell lung cancer [9-11], oesophageal squamous cell carcinoma [12, 13], prostate cancer [14, 15], hepatocellular cancer [16, 17], gastric cancer [18, 19], ovarian cancer [20, 21], breast cancer [22], urinary bladder cancer [23], and pancreatic cancer [24]. SIRT1 inhibitors claimed to be a promising anti-cancer in certain neoplasm, so, it is interesting to know the role of SIRT1 in ECA.

Currently there is little known about SIRT1 expression in

EC with limited conclusions. This study aims to determine the clinical relevance of SIRT1 expression in EC.

Materials and Methods

Patients

The study included paraffin embedded tumor blocks from 71 patients diagnosed with endometrial carcinoma in the period from 2003–2012. Also, paraffin blocks from non-neoplastic endometria of 58 patients in the period from 1995–1998 were included (20 proliferative endometria, ten secretory endometria, 28 endometrial hyperplasias without atypia). The paraffin blocks were collected from the Department of Pathology at King Abdulaziz University, Jeddah, Saudi Arabia. The clinicopathological data are summarized in Table 1. Tumor stages were reviewed and reclassified according to the cancer staging atlas of the American Joint Committee on Cancer [25]. For statistical purpose, FIGO stages were classified into limited to uterine corpus (FIGO Stage I and II) and beyond the uterine corpus (FIGO III and IV). Also, grade was reclassified as low (grade I) and high (grades II and III) (Table 1). Histopathological typing included 66 endometrioid type and five serous types. All serous carcinomas were included among the high-grade tumors. The study was performed in accordance with the Unit of the Biomedical Ethics, Research Committee of Faculty of Medicine, King Abdulaziz University, Saudi Arabia (Reference No. 1127-13), and declaration of Helsinki.

Table 1. — Clinicopathological features of endometrial tumours (n = 71).

Parameter	Number (%)	
Age	< 60 years	49 (69%)
	> 60 years	22 (31%)
Histological type	Endometrioid	66 (93%)
	Serous	5 (7%)
FIGO tumour grade	Grade 1	44 (62%)
	Grade 2	16 (22.5%)
	Grade 3	11 (15.5%)
Tumour size	< 2 cm	35 (49.3%)
	> 2 cm	36 (50.7%)
Myometrial invasion	< 50%	57 (80.3%)
	> 50%	14 (19.7%)
Lymphovascular	Absent	68 (95.8%)
	Present	3 (4.2%)
Surgical resection margin	Free	67 (94.4%)
	Involved	4 (5.6%)
Lymph node metastasis	Absent	33 (46.5%)
	Present	4 (5.6%)
	Not Sampled	34 (47.9%)
FIGO Staging	I	51 (71.8%)
	II	7 (9.9%)
	III	7 (9.9%)
	IV	6 (8.5%)
Local Recurrence	Absent	60 (84.5%)
	Present	11 (15.5%)

International Federation of Gynaecology and Obstetrics

Tissue Microarray

The tissue microarray was constructed as previously described [26, 27]. Pathology slides (haematoxylin and eosin-stained) of endometrial carcinoma, endometrial hyperplasia and normal endometrial tissue. Areas that showed extensive necrosis, poor cellular preservation, crush artefacts, dominant stromal tissue, or autolytic changes were avoided. Donor paraffin blocks that matched the chosen sections were utilized to get two cores (1.5 mm in diameter each) of the selected tissue and then transferred to recipient blocks via a tissue microarray machine (TMA Master 1.14 SP3 from 3D Histech Ltd., Budapest, Hungary). Unstained 4- μ m-thick sections were cut from the TMA blocks and utilized for immunohistochemistry studies.

Immunohistochemistry

Immunocytochemistry was performed by utilizing an anti-SIRT rabbit polyclonal antibody (H-300: sc-15404 from Santa Cruz Biotechnology Inc.). An automated immunostainer (Ventana Bench Mark XT, Ventana Inc., Tucson, AZ) was used to perform the immunohistochemistry procedure. The antibody was used as per manufacturing company instruction. The positive control was a colon cancer tissue that is known to be SIRT1-positive. Negative controls were processed without adding the primary antibody.

Evaluation of SIRT1 Immunostaining

Evaluation of SIRT1 immunostaining was performed semi-quantitatively as previously described with modification [23]. Positive cells for SIRT1 were divided as follows: (0) < 5%, (1) 5–25%, (2) 26–50%, and (3) 50–100%. We quantified the nuclear immunostaining intensity as follows: 3 (strong brown staining), 2 (intermediate staining), 1 (weak staining), and 0 (no staining). A 7-point scoring system was used to categorize SIRT1 expression according to a combination of intensity and extent. Tissue with strong or intermediate staining intensity (intensity score, 2–3) in at least 5% (percentage of staining score 1–3) of targeted cells was regarded as “SIRT1-positive”, which included point scores 2–7. Tissue with no or weak staining (intensity score, 0–1) and less than 5% (percentage of staining score 0%) of targeted cells were regarded as “SIRT1-negative”, which include point score 0–1.

Statistical analysis

The Chi-square test and Fisher’s exact test were used to test differences between two groups of variables. The overall survival (OS) and disease-free survival (DFS) values were measured by the Kaplan-Meier method with the log-rank (Mantel-Cox) comparison test. DFS was calculated as the time from diagnosis to the appearance of recurrent disease (or date of the last seen disease-free appearance). Statistical analyses were performed using the Statistical Package for the Social Science (SPSS®) software packages version 20 (SPSS Inc., Chicago, IL, USA). A *p*-value < 0.05 was considered significant.

Results

Immunostaining of SIRT1 was indicated by brown color in endometrial epithelial tissue (Figure 1). Positive SIRT1 immunostaining was seen in 29 out of 71 (40.8%) of endometrial carcinoma, while SIRT1 immunostaining was only seen in 7 out of 58 (12.1%) of nonneoplastic endometrial tissue (Table 2). The occurrence of positive immunostaining in endometrial carcinoma was statistically more in EC than in nonneoplastic tissue (*p* < 0.05). Positive immunostaining for SIRT1 showed no relation with age, histological type, histological grade, tumor size, myometrial invasion, lymphovascular invasion, surgical resection margin, lymph node metastasis, FIGO staging, or local recurrence. There is was also no association between SIRT-1 immunostaining and overall survival (Log rank 0.015, *p* = 0.902) (Figure 2) or disease-free survival (Log Rank 0.432, *p* = 0.511) (Figure 3). The SIRT1 positive cases in the nonneoplastic tissue included 2 hyperplastic and 5 proliferative endometrial tissue. No expression was identified in the secretory normal endometrial tissue.

Discussion

SIRT1 is a NAD-dependent class III histone deacetylase. The possible dual function of SIRT1 as a tumor promoter or as a tumor suppressor in different cancers is prob-

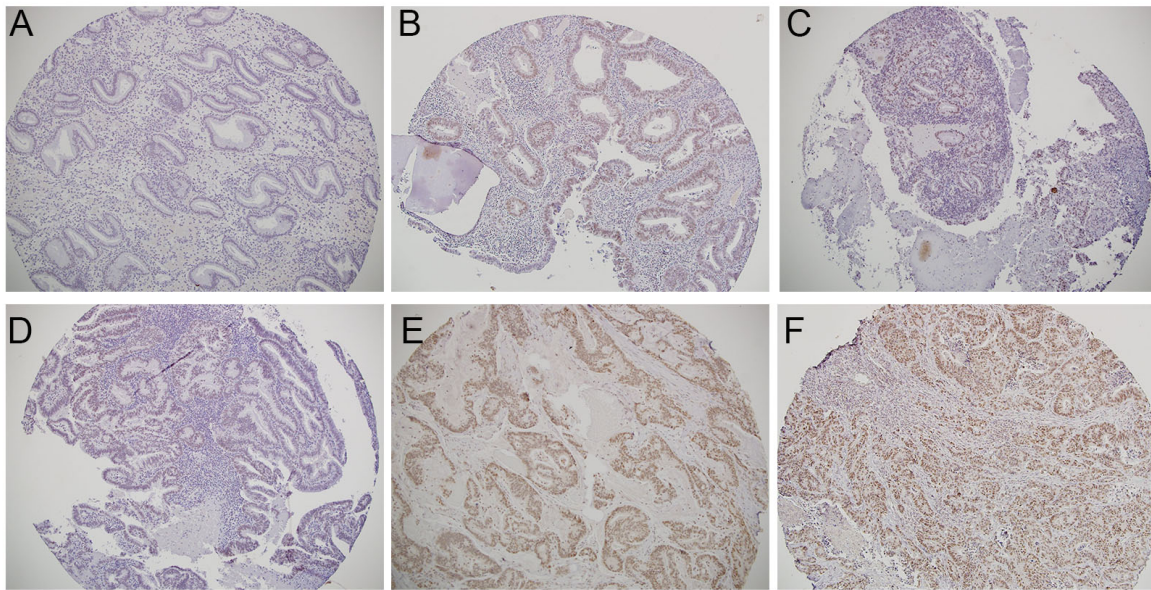


Figure 1. — Immunostaining of SIRT1 in normal endometrial tissue, endometrial hyperplasia and endometrial carcinoma. A. Normal secretory endometrium with negative immunostaining for SIRT1 (100X); B. Normal proliferative endometrium with positive immunostaining for SIRT1 (100X); C. Hyperplastic endometrial tissue with positive immunostaining for SIRT1, (100X); D. Endometrial carcinoma with positive staining for SIRT1, weak intensity (100X); E. Endometrial carcinoma with positive staining for SIRT1, intermediate intensity (100X); F. Endometrial carcinoma with strong staining for SIRT1, strong intensity (100X).

Table 2. — Categories of SIRT1 immunostaining in primary tumours and non-neoplastic endometrium.

	Primary tumour (n = 71)	Non-neoplastic endometrium (n = 58)	p value
Negative immunostaining	42 (59.2%)	51 (87.9%)	p-value is 0.00028
Positive immunostaining	29 (40.8%)	7 (12.1%)	

One sample non-parametric chi-square test

ably due to different oncogenic pathways that involve several downstream and upstream regulatory factors [28-31]. SIRT1 is known to be associated with poor prognosis, advanced stages and shorter patient survival in many human cancers and can function as a promising marker for prognosis. This association has been demonstrated in lung carcinoma [9-11], esophageal squamous cell carcinoma [12, 13], gastric cancer [19, 32], ovarian cancer [21], hepatocellular carcinoma [17], breast carcinoma [33] and urinary bladder cancer [23]. Additional studies have revealed that SIRT1 may be a tumor suppressor and its levels were found to be significantly lower in patients with cancer than in normal tissue, such as oral squamous cell carcinoma [34] and renal cell carcinoma [35]. These results, however, are controversial in colorectal carcinoma [36-38].

In a meta-analysis study, Wang *et al.* reviewed 37 studies, including (in total) 7,369 cases of solid tumors, and concluded that SIRT1 was expressed in 48.6% of the patients and SIRT1 expression was found to be significantly associated with overall survival and poor prognosis [39]. Currently, limited data has been published regarding SIRT1 expression in EC and the available results are contradictory. The results of this investigation revealed that the occur-

rence of SIRT1 positive staining is more frequent in neoplastic endometrial tissue, compared to non-neoplastic tissues. However, there was no association with overall and disease-free survival. This result is in contrast with Asaka *et al.*, who demonstrated that SIRT1 overexpression is significantly associated with shorter survival and aggressive behaviour in patients with EC and that SIRT1 is involved in an enhancement of the chemotherapy resistance in cancer cell lines [40]. Bartosch *et al.* found that SIRT1 and SIRT7 were overexpressed and underexpressed in ECs, compared to non-neoplastic tissue, respectively [31]. Bartosch *et al.* did not find a significant association between SIRT1 expression and histopathological type, grade, vascular space invasion or stage of EC [31]. Asaka *et al.* [40] demonstrated that SIRT1 expression is associated with higher tumor grade and vascular space invasion. In this report, they evaluated cytoplasmic, rather than nuclear staining. Lin *et al.* demonstrated that SIRT1 promotes EC growth and suggested that tumor growth can be attenuated by targeting SIRT1 in EC [41].

Few authors evaluated SIRT1 cytoplasmic staining, although most of these studies (including this investigation) evaluated nuclear staining, which is considered more accu-

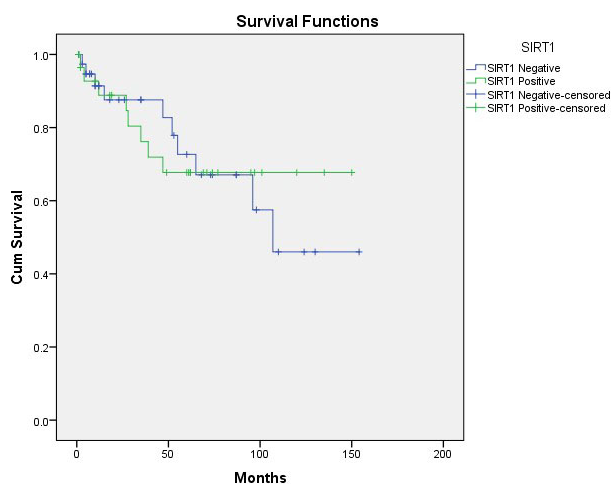


Figure 2. — Overall survival curve (Kaplan Meier) in relation to SIRT1 immunopositivity in EC patients. There is no association between SIRT-1 immunostaining and OS (Log rank 0.015, $p = 0.902$).

rate for evaluating the role of SIRT1 as a histone-modifying enzyme.

Our data is not supportive of association between SIRT1 immunopositivity and survival or other clinicopathological parameters in EC. The importance of SIRT1 immunopositivity may vary according to the cancer type. Further studies with larger tumor samples may help in exploration of this area. Bartosch *et al.* [31] commented on the conflicting results across studies regarding the role of SIRT1 in ECA and suggested that some of the conflict is due to using different non-neoplastic endometrial tissue that may include secretory, proliferative, inactive, atrophic epithelium or non-specified, which may affect the SIRT1 expression in these tissue [40, 41]. In the current study, different phases of normal endometrium were used, including proliferative and secretory endometrium. Positive SIRT1 staining was seen in proliferative (but not secretory) normal endometrial tissue.

The role of SIRT1 in tumorigenesis is complex, and the mechanism of SIRT1 function may be conducted through p53, FoxO1, NF- κ B and other signalling pathways [39]. Many studies have shown that the possible regulatory mechanism of SIRT1 as a cancer gene is associated with the tumor protein p53, and interacts with different substrates, including ER and Beta-catenin. All of these substrates are known key players in EC [42-47]. Sirtuins has different enzymatic activities and acts in different directions with cross-talk and feedback regulation between them. This unique role of SIRT1 in human cancer remains controversial and the variable results may reflect different SIRT1 roles in different organs or different ethnic groups. However, the different expression patterns could also be due to several factors, including its subcellular location, diverse downstream substrates, microenvironment or the signalling pathway af-

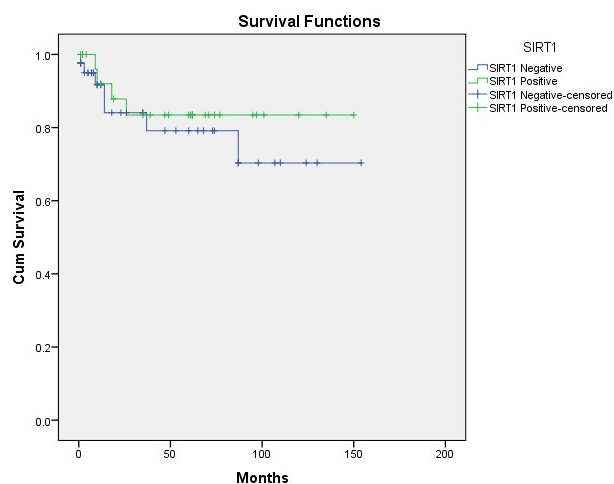


Figure 3. — Disease-free survival curve (Kaplan Meier) in relation to SIRT1 immunopositivity in EC patients. There is no association between SIRT-1 immunostaining and DFS (Log Rank 0.432, $p = 0.511$).

ected [39, 43, 48-51].

In conclusion, in endometrial carcinoma, the current study demonstrates that there is a statistically significant association between SIRT1 expression and malignant transformation. However, no association was found between SIRT1 expression and patient survival, or other clinicopathological parameters. So, although SIRT1 could play a role in the tumorigenesis of EC, it cannot be a predictor of survival or bad prognosis in EC. The results warrant further investigation into the role of SIRT1 in EC, and to explore the downstream molecular mechanisms of SIRT1.

Acknowledgments

We would like to express our gratitude to all those who helped us during the writing of this manuscript. Thanks to all the peer reviewers and editors for their opinions and suggestions.

Conflict of interest

The authors confirm that no part of this work has been submitted or published elsewhere and that there are no conflicts of interest.

Submitted: October 11, 2019

Accepted: March 24, 2020

Published: October 15, 2020

References

- [1] Bray F., Ferlay J., Soerjomataram I., Siegel R. L., Torre L.A., Jemal A.: "Global cancer statistics 2018: GLOBOCAN estimates of incidence and mortality worldwide for 36 cancers in 185 countries". *Ca. Cancer J. Clin.*, 2018, 68, 394-424.
- [2] Bazarbashi S., Al Eid H., Minguet J.: "Cancer Incidence in Saudi Arabia: 2012 Data from the Saudi Cancer Registry". *Asian Pac. J. Cancer Prev.*, 2017, 18, 2437-2444.

- [3] Khabaz M.N., Abdelrahman A.S., Butt N.S., Al-Maghrabi B., Al-Maghrabi J.: "Cyclin D1 is significantly associated with stage of tumor and predicts poor survival in endometrial carcinoma patients". *Ann. Diagn. Pathol.*, 2017, 30, 47-51.
- [4] Morice P., Leary A., Creutzberg C., Abu-Rustum N., Darai E.: "Endometrial cancer". *the Lancet*, 2016, 387, 1094-1108.
- [5] Amant F., Moerman P., Neven P., Timmerman D., Van Limbergen E., Vergote I.: "Endometrial cancer". *the Lancet*, 2005, 366, 491-505.
- [6] Blander G., Guarente L.: "The Sir2 Family of Protein Deacetylases". *Annu. Rev. Biochem.*, 2004, 73, 417-435.
- [7] Saunders L.R., Verdin E.: "Sirtuins: critical regulators at the crossroads between cancer and aging". *Oncogene*, 2007, 26, 5489-5504.
- [8] Karbasforooshan H., Roohbakhsh A., Karimi G.: "SIRT1 and microRNAs: The role in breast, lung and prostate cancers". *Exp. Cell Res.*, 2018, 367, 1-6.
- [9] Gharabaghi M.A.: "Diagnostic investigation of BIRC6 and SIRT1 protein expression level as potential prognostic biomarkers in patients with non-small cell lung cancer". *the Clinical Respiratory Journal*, 2018, 12, 633-638.
- [10] Gong J., Wang H., Lou W., Wang G., Tao H., Wen H., et al.: "Associations of sirtuins with clinicopathological parameters and prognosis in non-small cell lung cancer". *Cancer Manag. Res.*, 2018, 2018, 3341-3356.
- [11] Chen Y., Wang T., Wang W., Hu J., Li R., He S., et al.: "Prognostic and clinicopathological significance of SIRT1 expression in NSCLC: a meta-analysis". *Oncotarget*, 2017, 8, 62537-62544.
- [12] Han F., Zhang S., Liang J., Qiu W.: "Clinicopathological and predictive significance of SIRT1 and peroxisome proliferator-activated receptor gamma in esophageal squamous cell carcinoma: The correlation with EGFR and Survivin". *Pathol Res Pract.* 2018, 214, 686-690.
- [13] Ma M., Chiu T., Lu H., Huang W., Lo C., Tien W., et al.: "SIRT1 overexpression is an independent prognosticator for patients with esophageal squamous cell carcinoma". *J. Cardiothorac. Surg.*, 2018, 13,
- [14] Huffman D.M., Grizzle W.E., Bamman M.M., Kim J., Eltoum I.A., Elgavish A., et al.: "SIRT1 Is Significantly Elevated in Mouse and Human Prostate Cancer". *Cancer Res.*, 2007, 67, 6612-6618.
- [15] Ruan L., Department of Nephrology, The First Hospital of Hebei Medical University, Shijiazhuang, China, Wang L., Wang X., College of Integrative Medicine, Hebei University of Chinese Medicine, Shijiazhuang, China, He M., et al.: "SIRT1 contributes to neuroendocrine differentiation of prostate cancer". *Oncotarget*, 2018, 9, 2002-2016.
- [16] Chen H., Jeng Y., Yuan R., Hsu H., Chen Y.: "SIRT1 Promotes Tumorigenesis and Resistance to Chemotherapy in Hepatocellular Carcinoma and its Expression Predicts Poor Prognosis". *Ann. Surg. Oncol.*, 2012, 19, 2011-2019.
- [17] Jiang H., Zhang X., Tao Y., Shan L., Jiang Q., Yu Y., et al.: "Prognostic and clinicopathologic significance of SIRT1 expression in hepatocellular carcinoma". *Oncotarget*, 2017, 8, 52357-52365.
- [18] FESSEL M.R., LIRA C.B., GIORGIO S., RAMOS C.H.I. and CANO M.I.N.: "Sir2-Related Protein 1 from Leishmania amazonensis is a glycosylated NAD⁺-dependent deacetylase". *Parasitology*, 2011, 138, 1245-1258.
- [19] Qiu G., Li X., Wei C., Che X., He S., Lu J., et al.: "The Prognostic Role of SIRT1-Autophagy Axis in Gastric Cancer". *Dis. Markers*, 2016, 2016, 1-11.
- [20] Jang K.Y., Kim K.S., Hwang S.H., Kwon K.S., Kim K.R., Park H.S., et al.: "Expression and prognostic significance of SIRT1 in ovarian epithelial tumours". *Pathology (Phila.)*, 2009, 41, 366-371.
- [21] Mvunta D.H., Miyamoto T., Asaka R., Yamada Y., Ando H., Higuchi S., et al.: "Overexpression of SIRT1 is Associated With Poor Outcomes in Patients With Ovarian Carcinoma". *Applied Immunohistochemistry & Molecular Morphology*, 2017, 25, 415-421.
- [22] Sung J., Kim R., Kim J., Lee J.: "Balance between SIRT1 and DBC1 expression is lost in breast cancer". *Cancer Sci.*, 2010, 101, 1738-1744.
- [23] Al-Maghrabi J.: "Overexpression of SIRT1 in urothelial carcinoma of the urinary bladder is associated with local recurrence and poor survival". *Saudi Medical Journal*, 2019, 40, 541-547.
- [24] Zhao G., Cui J., Zhang J., Qin Q., Chen Q., Yin T., et al.: "SIRT1 RNAi knockdown induces apoptosis and senescence, inhibits invasion and enhances chemosensitivity in pancreatic cancer cells". *Gene Ther.*, 2011, 18, 920-928.
- [25] Amin M.B., Amin M.B., Edge S., Greene F., Byrd D.R., Brookland R.K., et al.: Pathologic TNM staging of carcinoma and carcinosarcoma of the corpus uteri, AJCC Cancer Staging Manual. 8th Edition New York, Springer, 2017, 2017.
- [26] Al-Maghrabi J., Emam E., Gomaa W., Saggaf M., Buhmeida A., Al-Qahtani M., et al.: "c-MET immunostaining in colorectal carcinoma is associated with local disease recurrence". *Bmc Cancer*, 2015, 15,
- [27] Al-Maghrabi J.: "Cyclooxygenase-2 expression as a predictor of outcome in colorectal carcinoma". *World J. Gastroenterol.*, 2012, 18, 1793.
- [28] Fang Y., Nicholl M.B.: "Sirtuin 1 in malignant transformation: Friend or foe?". *Cancer Lett.*, 2011, 306, 10-14.
- [29] Fang Y., Nicholl M.: "A Dual Role for Sirtuin 1 in Tumorigenesis". *Curr. Pharm. Des.*, 2014, 20, 2634-2636.
- [30] Stünkel W., Campbell R.M.: "Sirtuin 1 (SIRT1)". *J. Biomol. Screen.*, 2011, 16, 1153-1169.
- [31] Bartosch C., Monteiro-Reis S., Almeida-Rios D., Vieira R., Castro A., Moutinho M., et al.: "Assessing sirtuin expression in endometrial carcinoma and non-neoplastic endometrium". *Oncotarget*, 2016, 7, 1144-1154.
- [32] Jiang B., Chen J., Yuan W., Ji J., Liu Z., Wu L., et al.: "Prognostic and clinical value of Sirt1 expression in gastric cancer: A systematic meta-analysis". *Journal of Huazhong University of Science and Technology [Medical Sciences]*, 2016, 36, 278-284.
- [33] Cao Y., Li Y., Wan G., Du X., Li F.: "Clinicopathological and prognostic role of SIRT1 in breast cancer patients: a meta-analysis". *Int. J. Clin. Exp. Med.*, 2015, 8, 616-624.
- [34] Kang Y., Sun F., Zhang Y., Wang Z.: "SIRT1 acts as a potential tumor suppressor in oral squamous cell carcinoma". *J. Chin. Med. Assoc.*, 2018, 81, 416-422.
- [35] Jeh S.U., Park J.J., Lee J.S., Kim D.C., Do J., Lee S.W., et al.: "Differential expression of the sirtuin family in renal cell carcinoma: Aspects of carcinogenesis and prognostic significance". *Urologic Oncology: Seminars and Original Investigations*, 2017, 35, 675.e9-675.e15.
- [36] Chung S.Y., Jung Y.Y., Park I.A., Kim H., Chung Y.R., Kim J.Y., et al.: "Oncogenic role of SIRT1 associated with tumor invasion, lymph node metastasis, and poor disease-free survival in triple negative breast cancer". *Clinical & Experimental Metastasis*, 2016, 33, 179-185.
- [37] Hong W.G., Pyo J.: "The clinicopathological significance of SIRT1 expression in colon cancer: An immunohistochemical study and meta-analysis". *Pathology - Research and Practice*, 2018, 214, 1550-1555.
- [38] Zu G., Ji A., Zhou T. and Che N.: "Clinicopathological significance of SIRT1 expression in colorectal cancer: A systematic review and meta-analysis". *Int. J. Surg.*, 2016, 26, 32-37.
- [39] Wang C., Yang W., Dong F., Guo Y., Tan J., Ruan S., et al.: "The prognostic role of Sirt1 expression in solid malignancies: a meta-analysis". *Oncotarget*, 2017, 8, 66343-66351.
- [40] Asaka R., Miyamoto T., Yamada Y., Ando H., Mvunta D. H., Kobara H., et al.: "Sirtuin 1 promotes the growth and cisplatin resistance of endometrial carcinoma cells: a novel therapeutic target". *Lab. Invest.*, 2015, 95, 1363-1373.
- [41] LIN L., ZHENG X., QIU C., DONGOL S., LV Q., JIANG J., et al.: "SIRT1 promotes endometrial tumor growth by targeting SREBP1 and lipogenesis". *Oncol. Rep.*, 2014, 32, 2831-2835.
- [42] Hishida T., Nozaki Y., Nakachi Y., Mizuno Y., Iseki H., Katano M., et al.: "Sirt1, p53, and p38MAPK Are Crucial Regulators of Detrimental Phenotypes of Embryonic Stem Cells with Max Expression Ablation". *Stem Cells*, 2012, 30, 1634-1644.
- [43] Roth M., Chen W.Y.: "Sorting out functions of sirtuins in cancer". *Oncogene*, 2014, 33, 1609-1620.
- [44] Matias-Guiu X., Prat J.: "Molecular pathology of endometrial carcinoma". *Histopathology*, 2013, 62, 111-123.
- [45] Moore R.L., Dai Y., Faller D.V.: "Sirtuin 1 (SIRT1) and steroid hormone receptor activity in cancer". *J. Endocrinol.*, 2012, 213, 37-48.
- [46] Moore R.L., Faller D.V.: "SIRT1 represses estrogen-signaling, ligand-independent ERalpha-mediated transcription, and cell proliferation in estrogen-responsive breast cells". *J. Endocrinol.*, 2013, 216, 273-285.
- [47] Leeuwen I.V., Lain S.: "Sirtuins and p53". *Adv. Cancer Res.*, 2009, 102, 171-195.
- [48] Macedo de Oliveira M.V., Andrade J.M.O., Paraíso A.F., Santos

- S.H.S.: "Sirtuins and Cancer: New Insights and Cell Signaling". *Cancer Invest.*, 2013, 31, 645-653.
- [49] Bosch-Presegue L., Vaquero A.: "The Dual Role of Sirtuins in Cancer". *Genes & Cancer*, 2011, 2, 648-662.
- [50] Sebastián C., Satterstrom F.K., Haigis M.C., Mostoslavsky R.: "From Sirtuin Biology to Human Diseases: An Update". *J. Biol. Chem.*, 2012, 287, 42444-42452.
- [51] Song N., Surh Y.: "Janus-faced role of SIRT1 in tumorigenesis". *Ann. N. Y. Acad. Sci.*, 2012, 1271, 10-19.

Corresponding Author:

JAUDAH AL-MAGHRABI, M.D.
Department of Pathology, Faculty of Medicine,
King Abdulaziz University
P.O. BOX 80205, Jeddah (Saudi Arabia)
e-mail: jalmaghrabi@hotmail.com