

Sentinel lymph node mapping with carbon nanoparticles in endometrial cancer

Chen J.Y.¹, Wang Z.Q.¹, Liang S.C.¹, Hou H.Y.¹, Chen D.B.¹, Wang J.L.¹

¹Gynecology Department, Peking University people's Hospital, Beijing (China)

Summary

Aim: A retrospective study was conducted to explore the value of sentinel lymph node (SLN) mapping with carbon nanoparticles (CNP) in endometrial cancer patients. **Methods:** Seventy-six endometrial cancer patients who underwent sentinel lymph node mapping with or without systemic pelvic lymphadenectomy were involved in this study. All patients received cervical injection of carbon nanoparticles. The detection frequency for sentinel lymph nodes was calculated for all 76 patients, while the sensitivity and negative predictive value for metastasis were calculated for patients who underwent additional systemic pelvic lymphadenectomy (n=43). Clinical factors associated with sentinel lymph node detection were also evaluated. **Results:** The overall and bilateral detection frequencies were 71.1% (54/76) and 61.1% (33/54), respectively. A total of 291 sentinel lymph nodes were removed from 54 patients, with the median number removed per patient being 4 (range 3-7). sentinel lymph nodes were mostly located in the external iliac (45.7%) and obturator (41.2%) regions. Fifteen positive lymph nodes including 6 positive sentinel lymph nodes were found in 5 patients. Two of the five patients failed sentinel lymph node mapping but showed positive lymph nodes after systemic pelvic lymphadenectomy. The sensitivity and negative predictive value of sentinel lymph node mapping were therefore both 100%. **Conclusion:** The detection frequency of sentinel lymph node mapping with carbon nanoparticles in endometrial cancer patients was not as high as for some other cancer types. However, the accuracy of this method was high despite the relatively low detection frequency. More research is needed to improve sentinel lymph node mapping in endometrial cancer patients.

Key words: Sentinel lymph node; Endometrial cancer; Carbon nanoparticles.

Introduction

Endometrial cancer is one of the most common malignant tumors in women. Lymph node involvement is an independent factor associated with recurrence and poor prognosis of this disease [1]. Surgical staging of endometrial cancer includes total hysterectomy, bilateral salpingo-oophorectomy (TLH+BSO) and lymph node assessment. Total removal of the pelvic lymph nodes (usually including the external iliac, internal iliac, obturator, and common iliac nodes) and sometimes also the para-aortic lymph nodes is considered to be the standard procedure for assessment. Paradoxically, nodal disease occurs in very few patients, yet the prevalence of the high-risk group is significantly greater than the low risk group [2]. It is important to note however that total dissection can lead to lower limb lymphedema, thereby severely impacting the patients' quality of life. A previous study reported a major difference in the occurrence of lymphedema between patients who did or did not undergo systemic dissection [3].

With a view to removing as few nodes as possible without losing essential information for assessment, biopsy of sentinel lymph nodes (SLNs) is performed since these are the first nodes into which a tumor drains. This technique is designed to map the lymph nodes draining the uterus by injecting special tracers and then searching for labeled nodes within a specified time. Although there are already promis-

ing results for SLN mapping in endometrial cancer, several problems remain to be solved. The ideal mapping technique includes a feasible injection site, excellent tracers, suitable accessory equipment, a professional surgical team and the appropriate selection of patients. It has been shown that SLN mapping with cervical injection of tracers has a high accuracy and low false-negative rate for the detection of lymphatic metastasis in endometrial cancer[4]. Importantly, this also applies for patients with apparent uterine-confined grade 1 and 2 endometrioid cancers, thus providing an alternative to routine pelvic lymphadenectomy [5]. As for the tracers, Indocyanine Green (ICG) with NIR fluorescent imaging was found to give similar mapping to radiocolloid Tc-99 combined with blue dye, with the former being easier to perform and more reliable due to the fluorescent imaging. In contrast to the common use of these tracers in patients with endometrial cancer, there are few results to date using a new type of tracer, Carbon Nanoparticles (CNP). Whether CNP could serve as an alternative tracer for SLN mapping in endometrial cancer therefore warrants further study.

The aim of this work was to investigate the feasibility and reliability of SLN mapping in endometrial cancer patients following cervical injection of CNP. We also investigated the factors associated with successful mapping and analyzed the distribution of SLNs in our patients.

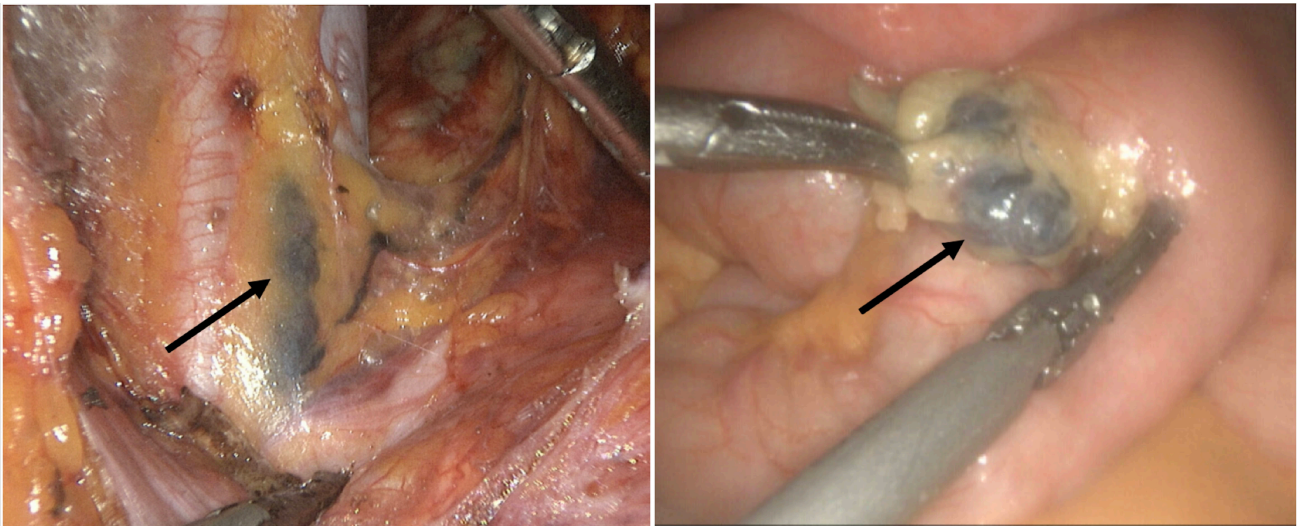


Figure 1. — The black-stained SLNs with CNP injection (as indicated by the black arrows). a. The CNP-labeled lymph nodes between external and internal iliac artery. b. The CNP-labeled lymph nodes that were resected separately.

Materials and methods

Seventy-six patients diagnosed with atypical hyperplasia and endometrial cancer between September 2015 and September 2017 were identified from the records of institute Ethics approvals. The clinical characteristics of these patients are shown in the Results section. All patients underwent SLN mapping followed by total laparoscopic hysterectomy (TLH) and bilateral salpingo-oophorectomy (BSO). Systemic pelvic lymphadenectomy with or without para-aortic lymphadenectomy was also performed in patients who failed mapping and in patients deemed as having high-risk disease (i.e. advanced stage and/or serous or clear cell histology).

SLN Mapping Procedure

Preoperative SLN mapping was performed for each patient. The CNP was injected in a superficial cervical manner (3 to 5 mm depth at 3/6/9/12 o'clock), or in a way that combined superficial (2 mm depth at 3/9 o'clock) and deep (10 mm depth, at 3/9 o'clock) cervical injection. Both techniques injected 0.2 ml of CNP into the cervix at each point. Black-stained SLNs appeared first and were subsequently removed.

Carbon Nanoparticles (CNP)

The Carbon Nanoparticles Suspension (1 ml, 50 mg) used in this study was produced by Chongqing Lummy Pharmaceutical Co., Ltd (address). Its China Food and Drug Administration (CFDA) approval number is H20041829.

Statistical Analysis

The following clinical information was collected: (1) age, height, weight, surgery options; (2) the number and location of SLNs, pelvic lymph nodes (PLNs), para-aortic lymph nodes (PALNs) and positive nodes; (3) pathology type and histology grade; (4) the invasion status of lymph

vascular space, myometrium and para-uterine tissue. The Body Mass Index (BMI) of patients was calculated by dividing their weight in kilograms by their height in meters squared. Overall and bilateral detection were defined as the identification of at least one black stained node from either side or from each side, respectively. The detection frequency was calculated as the percentage of positive patients (overall or bilateral) amongst all patients. The accuracy of SLN mapping was determined by calculating the sensitivity (percentage of patients with SLN metastasis amongst all metastatic cases) and negative predictive value (NPV, percentage of patients without metastasis amongst all SLN negative cases). The mean value \pm standard deviation ($x \pm SD$) and *t*-test were used when data was normally distributed, while the median (interquartile range, IQR) and non-parametric test were used for data that was not normally distributed. The *chi-2* test or Fisher's exact test were used for quantitative data. A value of $p < 0.05$ was considered statistically significant and all *p* values were two-sided. Statistical analyses were conducted using SPSS statistical software, version 20.0. (SPSS Inc., Chicago, IL, USA).

Results

Clinical Characteristics

A total of 76 endometrial cancer patients were included in this study. The mean age of patients was 55.8 years (Standard Deviation, SD = 9.6) and the mean BMI was 26.9 kg/m² (SD = 4.3). The most common histological type was atypical hyperplasia and endometrioid adenocarcinoma (71/76, 93.4%), with the others comprising mucinous adenocarcinoma (2/76, 2.6%), serous adenocarcinoma (2/76, 2.6%) and mixed carcinoma (1/76, 1.3%). Most patients were diagnosed with early stage disease (atypical hyperplasia and FIGO I; 66/76, 86.8%), with only 10 being advanced stage (10/76, 13.2%). TLH + BSO was performed

Table 1. — Clinical characteristics of patients

	Total (n, %)
Pathology type	
Atypical hyperplasia	4 (5.3%)
Endometrioid	67 (88.2%)
Mucinous	2 (2.6%)
Serous	2 (2.6%)
Mixed	1 (1.3%)
Grade of endometrioid cancer	
1	29 (38.2%)
2	26 (34.2%)
3	12 (15.8%)
FIGO stage	
0 [atypical hyperplasia]	4 (5.3%)
I	62 (81.6%)
II	1 (1.3%)
III	8 (10.5%)
IV	1 (1.3%)
LVSI	
Present	3 (3.9%)
Absent	73 (96.1%)
Myometrial invasion	
< 50%	67 (88.2%)
> 50%	9 (11.8%)
Parametrial involvement	
Present	10 (13.2%)
Absent	66 (86.8%)
Surgery (*TLH + BSO +)	
SLNB	33 (43.4%)
SLNB + PLND	9 (11.8%)
SLNB + PLND + PALND	34 (44.7%)

*TLH, Total Hysterectomy; BSO, Bilateral Salpingo-Oophorectomy; SLNB, Sentinel

Lymph Node Biopsy; PLND, Pelvic Lymph Node Dissection; PALND, Para-Aortic

Lymph Node Dissection

on all patients. Thirty-three patients underwent SLN mapping without Pelvic Lymph Node Dissection (PLND). Of the remaining 43 patients, 9 underwent PLND and 34 underwent PLND and para-aortic LN dissection (PALND). Fifty-nine patients were found to have atypical hyperplasia and G1~2 endometrioid lesions. LVSI, deep myometrial invasion (invasion depth > 50% of layer) and para-uterine tissue involvement occurred in 3.9% (3/73), 11.8% (9/73) and 13.2% (10/73) of patients, respectively (Table 1).

Detection frequency and accuracy of SLN mapping

The overall detection frequency from SLN mapping was 71.1% (54/76) (Figure 1). Frequencies for bilateral and unilateral detection were 61.1% (33/54) and 38.9% (21/54), respectively. The total number of SLNs was 291 in 54 patients, while for PLNs it was 1,184 in 43 patients. The median number of SLNs and PLNs was 4 (IQR, 3-7) and 27 (IQR, 19-35), respectively. Only 3 SLNs (3/291, 1.0%)

Table 2. — Detection rate and accuracy

Detection rate	
Overall	71.1% (54/76)
Bilateral	61.1% (33/54)
Unilateral	38.9% (21/54)
Number of SLNs	
Total	291
Median	4.0 (3.0 7.0)
Number of PLNs	
Total	1184
Median	27.0 (19.0 35.0)
Number of Positive Nodes	
Total	16
SLNs	6
non-SLNs	10
Accuracy	
	PLNs (Cases)
	+ -
SLNs	+ 3 0
(Cases)	- 0 25
<i>S</i>	100.00%
<i>NPV</i>	100.00%

S Sensitivity, *NPV* Negative Predictive Value.

were observed in the para-aortic region and these were all from one patient (1/54, 1.9%) (Table 2). Fifteen metastasis positive lymph nodes, including 6 SLNs, were discovered in 5 patients. Two of the five patients failed SLN mapping but were found to have positive lymph nodes after systemic lymphadenectomy (Table 3). Of the 28 patients with successful mapping followed by systemic lymphadenectomy, 3 patients were positive in both SLNs and PLNs, while the remaining 25 patients were negative for both. Thus, the sensitivity and NPV of SLNs were both 100% (Table 2).

Distribution of SLNs and of metastasis positive nodes

SLNs were located in the external iliac (45.7% of total), obturator (41.2%), common iliac (6.5%), internal iliac (2.7%), sacro anterior (1.0%), para-aortic (1.0%), inferior vena cava (1.0%) and inguinal (0.7%) regions (Table 4). Of the 6 metastasis positive SLNs, 4 were located in the obturator and 2 in the external iliac region. The 9 positive non-SLNs were located in the parametrial (n = 2), obturator (n = 2), external iliac (n = 1), common iliac (n = 1) and para-aortic (n = 3) regions.

Factors associated with successful mapping

No significant associations were observed between the success of SNL mapping and pathological type, histological grade, BMI or the presence of LVSI, deep myometrial invasion, parametrial involvement or number of surgical cases ($p > 0.05$) (Table 5).

Table 3. — The characteristics of the 5 patients with nodal metastasis

Characteristics	Case 1	Case 2	Case 3	Case 4	Case 5
Age, y	57	54	64	75	78
Pathology type	Endometrioid	Endometrioid	Endometrioid	Serous	Serous
Grade	3	3	3	3	3
FIGO stage	III	III	III	III	IV
LVSI	Yes	Yes	No	Yes	No
Deep myometrial invasion	Yes	Yes	Yes	Yes	No
Parametrial involvement	No	No	No	No	No
SLNB*	Yes	Yes	Yes	Yes	Yes
PLND*	Yes	Yes	Yes	Yes	Yes
PALND*	Yes	No	Yes	Yes	Yes
Number of SLNs	8	0	0	3	4
Number of positive SLNs	2	0	0	1	3
Number of positive non-SLNs	5	2	2	0	0

*SLNB, Sentinel Lymph Node Biopsy; PLND, Pelvic Lymph Node Dissection; PALND, Para-Aortic Lymph Node Dissection

Table 4. — The distribution of SLNs
(Total number = 291.0)

Region	Number (n, %)
External iliac	133.0 (45.7)
Obturator	120.0 (41.2)
Common iliac	19.0 (6.5)
Internal iliac	8.0 (2.7)
Inguinal	2.0 (0.7)
sacro anterior	3.0 (1.0)
para-aortic	3.0 (1.0)
inferior vena cava	3.0 (1.0)

Discussion

Value of SLN biopsy in endometrial cancer

The assessment of lymph node status is crucial for correct staging of endometrial cancer patients and this partly determines their prognosis and the therapeutic strategy to be employed. To date, systemic pelvic lymphadenectomy has been widely used due to its accuracy for proper staging and appropriate treatment. However, post-lymphadenectomy complications such as lymphedema and lymphocele present major challenges for surgeons and patients [2]. Unlike the systemic removal of nodes, SLN biopsy only removes the lymph nodes where lymphatic metastasis is likely to have occurred first. It is generally believed that lymphatic metastasis has not occurred in patients whose SLNs were found to be negative. SLN biopsy provides an alternative source of information on lymph node status and was integrated into the 2015 National Comprehensive Cancer Network (NCCN) guidelines on endometrial cancer [6].

The typical symptom of irregular vaginal bleeding occurs in early endometrial cancer and hence most patients present with an apparent uterine-confined disease and a very low risk of lymphatic metastasis. These patients are unlikely to benefit from complete lymphadenectomy and

therefore lymphoscintigraphy can be used to maximize the value of nodal assessment. As expected, patients with early disease (atypical hyperplasia and FIGO I) [7] comprised the large majority (66/76, 86.8%) of cases in the present study. None of these early stage patients had nodal disease (0/66), whereas half of the advanced stage (FIGO II-IV) patients (5/10, 50%) showed lymphatic metastasis ($p < 0.001$). Therefore, SLN biopsy appears especially useful for early stage patients.

Multiple factors are associated with successful mapping

Adequate assessment of pelvic lymph nodes depends primarily on a high frequency of detection, especially bilateral detection, as well as high accuracy. Excellent detection frequencies with SLN mapping have been achieved in malignancies such as colorectal cancer (94%), melanoma (98%) and breast cancer (96%) [8]. However, the performance of this technique in endometrial cancer has not been as satisfactory as in the abovementioned cancers. A systematic review published in 2011 by Sokbom *et al.* reported overall and bilateral detection frequencies of 78% (95% Confidence Interval [CI]: 73%-84%) and 61% (95% CI: 20%-81%), respectively [8]. How *et al.* published similar results in 2017 and additionally found the para-aortic detection frequency was just 6% (95% CI: 3%-9%) [9]. The wide range in reported detection frequencies and the considerable 'between-study' heterogeneity suggests that SLN mapping in endometrial cancer is affected by multiple factors [8]. Here we review the main factors related to successful mapping and discuss our result (71.1% detection frequency) in relation to these factors.

The injection site

The injection site is a major factor in SLN mapping that affects detection. Uterine injection, including sub-serosal injection and hysteroscopic endometrial injection, is a reasonable site for draining from the surrounding area of uterine tumors. However, in systematic literature reviews uterine injection showed a lower detection frequency compared

Table 5. — The relevant factors might affect the success rate of SLN mapping

	Detected Cases (n)		Fail detection	*Detection rate (%)	Confidence Intervals (95%)		P value
	Successful	Fail			Lower	Upper	
Pathology Type					0.284	7.804	1
Endometriod	47	20		70.1			
Non-endometriod	7	2		77.8			
FIGO Stage					0.142	2.228	0.462
0 / I	48	18		72.7			
II / III / IV	6	4		60			
BMI*					0.368	2.882	0.956
< 24.0	45	14		76.3			
≥ 24.0	9	8		52.9			
LVSI*					0.22	4.036	1
Present	7	3		70			
Absent	47	19		71.2			
Deep Myometrial Invasion					0.284	7.804	1
Present	7	2		77.8			
Absent	47	20		70.1			
Parametrial Extension					0.992	1.13	0.552
Present	3	0		100			
Absent	51	22		69.9			
Surgical cases					0.396	2.989	0.87
≤ 30	21	9		70			
> 30	33	13		71.7			

*BMI Body Mass Index, *LVSI Lymph Vascular Space Invasion

*Hypothesis for detection: successful = 1, fail = 0

with cervical injection [10]. Gargiulo *et al.* showed that dye injection into the cervical site of endometrial cancer patients led to a very high overall detection frequency, regardless of the type of tracer used [11]. Moreover, the bilateral detection frequency was similar to that reported for uterine injection [7, 8, 10, 12]. Cervical injection could also map the draining pathways for the uterine body [5], as discussed later. Using cervical injection, we obtained a result of 71.1% (54/76) for overall detection and 61.1% (33/54) for bilateral detection. Thus although the overall detection was somewhat lower, the bilateral detection frequency was almost identical to previous studies. The latter result is more important for individual patients. With regard to the para-aortic region, the literature shows significantly less detection of SLNs using cervical injection [8, 13]. This might cause a failure to detect nodal metastasis in the para-aortic region. Isolated para-aortic nodal metastasis occur in approximately 1% of early stage endometrial cancer patients with both low- and high-grade lesions [14]. ‘Over-detection’ in the para-aortic region might lead to extensive lymphadenectomy, leading to extra complications for these patients. In our study, the para-aortic detection frequency was 1.9% (1/54) and just 3 negative lymph nodes were obtained from this single patient, with accompanying pelvic lymph nodes also harvested.

The tracers

The type of tracer used influences both the detection frequency and the accuracy of SLN mapping. Indocyanine Green (ICG) is an excellent mapping agent and its injection into the cervix of endometrial cancer patients achieved overall and bilateral detection frequencies of 96.9% and 84.1%, respectively [15]. ICG is rapidly delivered into lymphatic vessels by binding to albumin, meaning it only takes a short time to appear in lymph node regions. There are some deficiencies, however. ICG can diffuse soon after injection, making it difficult to distinguish nodes from surrounding tissue. Thus, a ‘false-node’ may sometimes be dissected, causing a high false negative rate [16, 17].

CNP is a new generation tracer with several advantages for the detection of SLNs in gynecologic cancers. Firstly, the diameter of CNPs (average 150 nm) prevents them from entering blood capillaries (20~50 nm diameter) but allows them to enter lymphatic capillaries (110~500 nm diameter of endothelial cell space). CNPs therefore concentrate and remain only in lymph nodes that are then subsequently dissected. Secondly, the black staining SLNs can easily be identified by their gross morphology, thus avoiding the need for specialized equipment [18]. However, this characteristic could be a disadvantage in some circumstances due to limited visual recognition by the surgeon. This may have contributed to our somewhat lower overall SLN detection frequency of 71%. Despite this, we recorded scores

of 100.0% for both the sensitivity and negative predictive value of metastasis. These results suggest that cervical injection of CNP is a reliable way to evaluate lymphatic metastasis in endometrial cancer, but that unilateral or bilateral systemic pelvic lymphadenectomy is necessary after failed SLN mapping in one or both sides.

Patient characteristics

High BMI and the presence of LVSI were previously thought to contribute to failed mapping in endometrial cancer because of restricted tracer access to the lymph nodes [19]. However, the present study with CNP found no significant associations between these two factors and the overall detection of SLNs (BMI, $p = 0.956$; LVSI, $p = 1.000$). The pathology type or histological grade of tumor were previously reported not to affect the success of mapping [19]. This was confirmed in the present study. Since no significant difference in the detection frequency was found between early and advanced disease patients, we further subdivided early stage patients into those with low risk of recurrence (51/66, 77.3%) and those with intermediate/high risk (15/66, 22.7%) according to the European Society Of Medical Oncology (ESMO) classification [20]. Interestingly, there were no differences between these two groups for either overall ($p = 0.358$) or bilateral ($p = 0.494$) detection, suggesting that SLN mapping can be applied to all patients with early stage disease, regardless of their risk of recurrence.

SLN distribution following cervical injection

A key issue that needs to be addressed is whether the drainage pathway of injected tracer accurately represents the metastasis pattern of endometrial cancer. Two drainage pathways were observed for pelvic lymph nodes and can be summarized briefly as follows. One crosses over the umbilical ligament to drain the external iliac, obturator and internal iliac regions (pathway I). The other pathway runs along the mesoureter cephalad to drain the common iliac and pre-sacral regions (pathway II). An additional pathway could skip the pelvic lymph nodes and directly drain the para-aortic region (pathway III), thus explaining the rare para-aortic nodal metastases observed in endometrial cancer [5,8]. We recorded a total of 291 SLNs, with the majority located in the external iliac and obturator regions. Of our 54 successfully mapped cases, 52 (96.3%) involved pathway I, 14 (25.9%) involved pathway II, and only 1 case (1.9%) involved pathway III. With regard to the three metastasis cases detected by SLN biopsy, all (100.0%) involved pathway I, consistent with the most common SLN drainage route. No isolated nodes involved in pathway III were found. Of note, one of the three metastasis cases had 5 positive non-SLNs (2 in para-uterine and 3 in para-aortic regions) involved in pathway III and detected following complete lymphadenectomy. This suggests that endometrial cancer patients could have para-aortic lymphatic metastasis without detection by SLN mapping, especially when using cervical injection. However, these non-labeled positive nodes are usually accompanied by positive SLNs, thus in-

dicating the possibility of para-aortic lymphatic metastasis.

Despite the somewhat low detection frequency, cervical injection of CNP was a reliable way to exclude the presence of lymphatic metastasis in endometrial cancer patients. This method showed a high sensitivity and NPV, and notably in patients with early disease. As multiple factors can clearly affect the success of SLN mapping, more research in this area is urgently required.

Author contributions

Wang J.L. contributed to the conception of the study;Liang S.C., Hou H.Y. and Chen D.B. performed the experiment; Wang Z.Q. contributed significantly to analysis and manuscript preparation; Chen J.Y. performed the data analyses and wrote the manuscript.

Ethics approval and consent to participate

Ethical Committee approval was obtained from the Institutional Ethical Committee of Peking University People's Hospital and all subjects signed an informed consent form.

Acknowledgments

This study was supported by a fund from the National Key Technology Research and Development Program of the Ministry of Science and Technology of China (2015BAI13B06).

Conflict of interest

We declare that we do not have any commercial or associative interest that represents a conflict of interest in connection with the work submitted.

Submitted: June 30, 2019

Accepted: September 19, 2019

Published: June 15, 2020

References

- [1] Wakayama A., Kudaka W., Matsumoto H., Aoyama H., Ooyama T., Taira Y., *et al.*: "Lymphatic vessel involvement is predictive for lymph node metastasis and an important prognostic factor in endometrial cancer". *Int. J. Clin. Oncol.*, 2018, 23, 532.
- [2] Vargas R., Rauh-Hain J.A., Clemmer J., Clark R.M., Goodman A., Growdon W.B., *et al.*: "Tumor size, depth of invasion, and histologic grade as prognostic factors of lymph node involvement in endometrial cancer: a SEER analysis". *Gynecol. Oncol.*, 2014, 133, 216.
- [3] Yost K.J., Cheville A.L., Al-Hilli M.M., Mariani A., Barrette B.A., McGree M.E., *et al.*: "Lymphedema after surgery for endometrial cancer: prevalence, risk factors, and quality of life". *Obstet. Gynecol.*, 2014, 124, 307.
- [4] Ruscito I., Gasparri M.L., Braicu E.I., Bellati F., Raio L., Sehoulji J., *et al.*: "Sentinel Node Mapping in Cervical and Endometrial Cancer: Indocyanine Green Versus Other Conventional Dyes-A Meta-Analysis". *Ann. Surg. Oncol.*, 2016, 23, 3749.
- [5] NCCN Guidelines Version 2. 2017: "Uterine Neoplasms". Available at: http://www.nccn.org/professionals/physician_gls/pdf/uterine.pdf
- [6] NCCN Guidelines Version 2. 2015: "Uterine Neoplasms". Available at: http://www.nccn.org/professionals/physician_gls/pdf/uterine.pdf.

- [7] Pecorelli S.: "Revised FIGO staging for carcinoma of the vulva, cervix, and endometrium". *Int. J. Gynaecol. Obstet.*, 2009, 105, 103.
- [8] Kang S., Yoo H.J., Hwang J.H., Lim M.C., Seo S.S., Park S.Y.: "Sentinel lymph node biopsy in endometrial cancer: meta-analysis of 26 studies". *Gynecol. Oncol.*, 2011, 123, 522.
- [9] How J.A., O'Farrell P., Amajoud Z., Lau S., Salvador S., How E., *et al.*: "Sentinel lymph node mapping in endometrial cancer: a systematic review and meta-analysis". *Minerva Ginecol.*, 2018, 70, 194.
- [10] Geppert B., Lonnerfors C., Bollino M., Arechvo A., Persson J.: "A study on uterine lymphatic anatomy for standardization of pelvic sentinel lymph node detection in endometrial cancer". *Gynecol. Oncol.*, 2017, 145, 256.
- [11] Gargiulo T., Giusti M., Bottero A., Leo L., Brokaj L., Armellino F., *et al.*: "Sentinel Lymph Node (SLN) laparoscopic assessment early stage in endometrial cancer". *Minerva Ginecol.*, 2003, 55, 259.
- [12] Sawicki S., Lass P., Wydra D.: "Sentinel Lymph Node Biopsy in Endometrial Cancer—Comparison of 2 Detection Methods". *Int. J. Gynecol. Cancer*, 2015, 25, 1044.
- [13] Sahbai S., Taran F.A., Fiz F., Staebler A., Becker S., Solomayer E., *et al.*: "Pericervical Injection of ^{99m}Tc-Nanocolloid Is Superior to Peritumoral Injection for Sentinel Lymph Node Detection of Endometrial Cancer in SPECT/CT". *Clin. Nuclear Med.*, 2016, 41, 927.
- [14] Abu-Rustum N.R., Gomez J.D., Alektiar K.M., Solow R.A., Hensley M.L., Leitao M.M. Jr., *et al.*: "The incidence of isolated paraaortic nodal metastasis in surgically staged endometrial cancer patients with negative pelvic lymph nodes". *Gynecol. Oncol.*, 2009, 115, 236.
- [15] Papadia A., Zapardiel I., Bussi B., Ghezzi F., Ceccaroni M., De Ponti E., *et al.*: "Sentinel lymph node mapping in patients with stage I endometrial carcinoma: a focus on bilateral mapping identification by comparing radiotracer Tc99(m) with blue dye versus indocyanine green fluorescent dye". *J. Cancer Res. Clinical Oncol.*, 2017, 143, 475.
- [16] Miyashiro I., Hiratsuka M., Sasako M., Sano T., Mizusawa J., Nakamura K., *et al.*: "High false-negative proportion of intraoperative histological examination as a serious problem for clinical application of sentinel node biopsy for early gastric cancer: final results of the Japan Clinical Oncology Group multicenter trial JCOG0302". *Gastric cancer*, 2014, 17, 316.
- [17] Lu Y., Wei J.Y., Yao D.S., Pan Z.M., Yao Y.: "Application of carbon nanoparticles in laparoscopic sentinel lymph node detection in patients with early-stage cervical cancer". *PLoS One*, 2017, 12, e0183834.
- [18] Liang S.C., Wang Z.Q., Wang J.L.: "Clinical analysis of 76 cases of sentinel lymph node detection in cervical cancer and endometrial cancer". *Zhonghua Fu Chan Ke Za Zhi*, 2017, 52, 605.
- [19] Eitan R., Sabah G., Krissi H., Raban O., Ben-Haroush A., Goldschmit C., *et al.*: "Robotic blue-dye sentinel lymph node detection for endometrial cancer - Factors predicting successful mapping". *Eur. J. Surg. Oncol.*, 2015, 41, 1659.
- [20] Colombo N., Preti E., Landoni F., Carinelli S., Colombo A., Marini C., *et al.*: "Endometrial cancer: ESMO Clinical Practice Guidelines for diagnosis, treatment and follow-up". *Ann. Oncol.*, 2013, 24, vi33.

Corresponding Author:

WANG JIANLIU, M.D.

No. 11, Xizhimen South Street, Xicheng District

Beijing (China)

E-mail: wangjianliu@pku.edu.cn