

# Hypercalcemia associated with primary mucinous ovarian tumor followed by pseudomyxoma peritonei can be fatal: a case report

Jisu Yeom<sup>1</sup>, Seulki Lee<sup>1</sup>, Youngsun Kim<sup>1</sup>

<sup>1</sup>Department of Obstetrics and Gynecology, Kyung Hee Medical Center, College of Medicine, Kyung Hee university, Seoul, Republic of Korea

## Summary

Hypercalcemia is a common complication of malignancy, occurring in up to 30% of patients. The development of hypercalcemia in patients with cancer portends a worse prognosis, with patients more likely to have advanced disease and decreased survival rates. Mucinous neoplasms of the ovary account for 10%–15% of ovarian neoplasms. They may be benign, borderline, or malignant. The majority are benign or borderline, accounting for 80% and 16%–17%, respectively. Pseudomyxoma peritonei (PMP) is a rare disease. It refers that PMP is the accumulation of mucin in the abdominal or pelvic cavity derived from associated mucinous tumor usually from the appendix, but also associated with ovarian mucinous tumors. Herein, we report a case of hypercalcemia associated with primary mucinous ovarian tumor followed by PMP that had fatal consequences.

**Key words:** Hypercalcemia; Mucinous ovarian tumor; Pseudomyxoma peritonei.

## Introduction

Hypercalcemia often indicates a poor prognosis in patients with malignancies; it is reported in 10–30% patients [1]. Sustained high levels of serum calcium levels can cause severe nervous system problems, including coma as well as renal dysfunction [2]. To decrease morbidity and prevent a potential hypercalcemic crisis, treatment to maintain normal serum calcium level is necessary. Malignancy-associated hypercalcemia (MAHC) is very rare disease in patients with ovarian cancer; few cases have been reported [3].

MAHC can be classified into four types; humoral hypercalcemia of malignancy (HHM), primary or ectopic hyperparathyroidism, osteolytic hypercalcemia, and vitamin D secreting lymphomas [4]. Since the etiology of hypercalcemia is different for each of the four types, the correct differential diagnosis of hypercalcemia is essential to ensure correct treatment. Mucinous neoplasms of the ovary most commonly affect women in their 20 s to 40 s. The clinical manifestations are nonspecific, but most mucinous ovarian neoplasms manifest as large unilateral pelvic masses. Primary treatment is surgical. Since most mucinous ovarian neoplasms are benign or borderline, the overall prognosis is excellent.

PMP is defined as abundant mucinous fluid or gelatinous ascites that it appears to be clonally derived from associated mucinous tumor usually of the appendix, but also associated with ovarian mucinous tumors, although these may be metastatic from appendix or other GI sites. Therefore, it is

prudent to exclude origin of the tumor from the appendix, mostly by surgical excision and histological examination of the appendix, in cases of PMP [5]. It was once thought to have its origin in the ovaries. If left untreated, the tumor produces mucinous fluid that can fill the entire abdominal cavity. This results in multiple organs being compressed, which can be fatal. Therefore, it is important to navigate at the appendix, known as the origin of PMP, and to cleanse the inside of the abdominal cavity during surgery [6, 7].

Here, we present a case of ovarian cancer-associated hypercalcemia and its eventual outcome. To clarify the etiology of hypercalcemia, differential diagnosis was made through laboratory investigations and imaging studies.

## Case Report

A 20-year-old female patient who presented with painful abdominal of 3 months' duration was referred to our hospital for evaluation and treatment. She was diagnosed with a right ovarian cyst (8.7 cm) at another hospital two years before coming to our hospital, but she had refused to follow up and observed. The abdomen-pelvis enhanced computed tomography showed a right ovarian mass (20 cm) such as malignant germ cell tumor or cystadenoma, and multiple lymphadenopathy, including the obturator, both internal iliac, right external iliac, left aortocaval, left paraaortic, and left supraclavicular lymph nodes (Figure 1A).

The initial clinical laboratory findings indicated an elevated serum calcium level of 14.7 mg/dL (normal range: 8.4–10.2 mg/dL), which led us to test the other calcium-related laboratory data. Her serum parathyroid hormone

Table 1. — The calcium-related laboratory data.

Parameter	Standard values	Pre-operative	Post-operative
Calcium	8.4-10.2 mg/dL	14.7	9.6
Phosphate	2.5-4.5 mg/dL	3.6	2.8
1,25(OH) <sub>2</sub> D	23.5-147 nmol/L	-	-
Albumin	35-55 g/L	39	26
Creatinine	44-115 μmol/L	50	81
PTH	1.1-7.3 pmol/L	0.43	-
PTH-rP	< 1.3 pmol/L	18.9	125.0

(PTH)-related protein (PTH-rP) was 18.9 pmol/L (normal range: < 1.3 pmol/L), and PTH value was low, 4.3 pg/mL (normal range: 11-73 pg/mL). Serum cancer antigen 125 (CA125) level was 201 U/mL. The calcium-related laboratory data were shown in Table 1.

The positron emission tomography-computed tomography (PET-CT) was performed and no skeletal metastasis or parathyroid gland hyperplasia of orthotopic or ectopic parathyroid gland adenoma were observed. (Figure 1B). The patient was diagnosed with MAHC. She was treated for hypercalcemia with massive intravenous hydration and diuresis, followed by intravenous pamidronate (total 90 mg). Her hypercalcemia transiently resolved after the treatment. The patient's calcium level decreased to 8.8 mg/dL. On the other hand, excessive intravenous hydration caused pleural effusion. Because of her general condition and for preserving her fertility, she underwent a right salpingo-oophorectomy only. The left adnexa and uterus were clear in intraoperative findings, lymph node enlargement was not observed, and the omentum was also clear.

Peritoneal washing was done and it had no malignant cells, and the histopathologic results of the right ovary indicated mucinous carcinoma (FIGO stage IIA), destructive stromal invasive pattern and lymphovascular invasion was observed (Figures 2A and 2B). The postoperative serum calcium level was remained normal level at 9.6 mg/dL. On the 7th postoperative day, her calcium level was 13.7 mg/dL and the potassium level had increased to 5.5 mmol/L (normal range: 3.5-5.1 mmol/L).

She was treated for hypercalcemia with hydration, diuresis, pamidronate (60 mg), and zolenic acid (3 mg) and for the hyperkalemia with kalimate. However, the serum calcium level increased to 16.1 mg/dL, potassium to 5.9 mmol/L, and serum creatinine level was 1.46 mg/dL. Moreover, her mental status was drowsy to stupor. The patient was transferred to the Intensive Care Unit and started on continuous renal replacement therapy (CRRT). After two days of CRRT, the patient's mental state was alert and the laboratory findings were normal. Two days later, she complained of severe abdominal distension and was diagnosed with acute kidney injury. The abdomen-pelvis enhanced computed tomography scan (Figure 3) showed marked progression of the PMP, direct invasion of the right kidney and

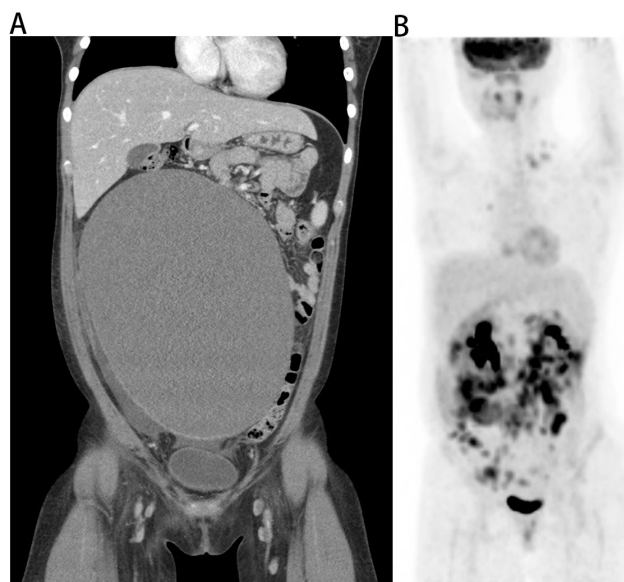


Figure 1. — Radiologic findings, A. Abdominal-pelvis enhanced computed tomography. About 20 cm mass in right ovary. B. The positron emission tomography-computed tomography. No skeletal metastasis or parathyroid gland hyperplasia.

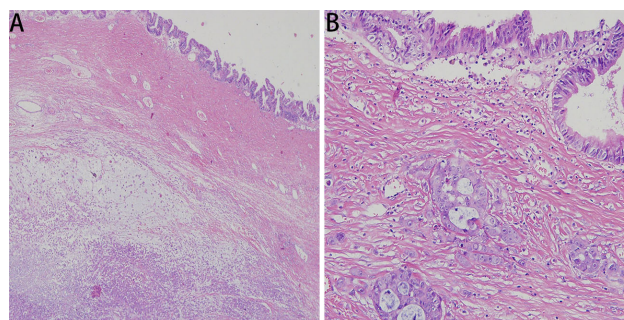


Figure 2. — The histopathological results of mucinous carcinoma on destructive stromal invasive pattern and lymphovascular invasion. A. Hematoxylin & Eosin staining ×40. B. Hematoxylin & Eosin staining ×200.

compression of the inferior vena cava, abdominal aorta, and branches of the great vessels. The patient succumbed within 4 days, 30 days after being hospitalized.

## Discussion

It is found that up to 10-30% of patients with cancer increase in calcium [8]. The most common cancers accompanied by hypercalcemia are lung cancer, renal cell carcinoma, multiple myeloma and breast cancer. Malignancy-associated hypercalcemia in ovarian cancer has mostly been described in small cell and clear cell carcinomas of the ovary. Ovarian cancer-related hypercalcemia is rare and has only a few cases are reported [8].

Many women with ovarian cancer develop elevated serum calcium because ovarian cancer overexpress parathy-

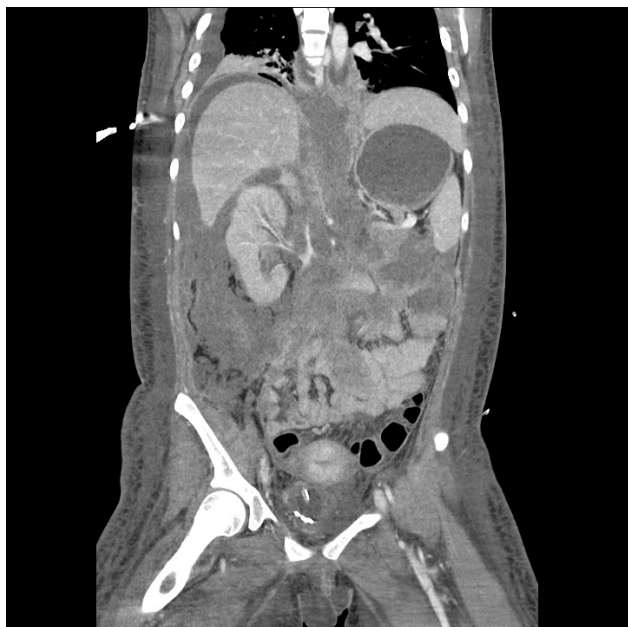

Figure 3. — Post-operative abdominal-pelvis enhanced computed tomography. Marked progression of the pseudomyxoma peritonei in the right kidney and compression of the inferior vena cava, abdominal aorta, and branches of great vessels.

roid hormone-related protein (PTH-rP), it causes calcium levels in blood to rise. About 50% of calcium in blood is bound to albumin, so it is not active state [9]. Clinical ovarian cancer is associated with low serum albumin [9].

Hypercalcemia in malignancy is an independent prognostic factor. Among patients diagnosed with MAHC, 50% die within 1 month and 75% die within 3 months of starting treatment [3]. To prevent symptoms such as neurocognitive dysfunction and renal insufficiency caused by hypercalcemia crisis, an accurate understanding of etiology and appropriate treatment is important.

The mechanisms of MAHC include HHM (humoral hypercalcemia in malignancy), primary or secondary hyperparathyroidism, osteolytic hypercalcemia, and vitamin D secreting lymphomas [4]. HHM, which is related to malignant tumor cell secretion of PTH-rP, is the most common cause of MAHC [2]. PTH-rP is a protein produced by tumors and shares the same N-terminal end as PTH, which enables them to share the same receptor [10]. PTH-rP increases bone resorption, renal retention of calcium, and excretion of phosphate, but decreases renal clearance of calcium, similar to the action of PTH.

There are, however, some differences between the HHM caused by PTH-rP and primary or secondary hyperparathyroidism caused by PTH. Especially, unlike PTH, Calcitriol (1,25-(OH)<sub>2</sub>D) secretion which enhances the intestinal absorption of calcium cannot be increased by PTH-rP [11]. The PTH stimulates the conversion of 25-(OH)D to 1,25-(OH)<sub>2</sub>D in the kidney [11]. As mentioned above in the features of PTH-rP, HHM can be distinguished from other

causes of hypercalcemia. In our case, the patient's calcium-related laboratory values indicated a high level of serum PTH-rP, low level of PTH and 1,25-(OH)<sub>2</sub>D, and a normal level of phosphate.

Thyroid ultrasonography showed normal echogenicity, indicating no primary hyperparathyroidism. And PET-CT also showed no evidence of parathyroid gland adenoma, and did not show skeletal involvement of the tumor. These results suggested that hypercalcemia in this case was HHM caused by PTH-rP secreted from the ovarian cancer cells. Although the treatment of underlying cancer is important and should be the ultimate goal, rapid symptom control by treating hypercalcemic crisis is also important. The treatment of hypercalcemia includes saline hydration and the use of diuretics, bisphosphonate, and dialysis [11].

In our case, the first hypercalcemia could be treated well with pamidronate intravenous injection, but the treatment of the second hypercalcemic crisis, despite pamidronate and blood dialysis did not prevent her from dying, who had lived only 30 days after initial hospitalization. In fact, the main cause of death in our patient was the rapid progress of the disease. Regarding the intraoperative findings, except the right ovary tumor, the abdominal cavity was clear including the appendix, but within two weeks, PMP filled the abdominal cavity, resulting in compression of the abdominal organs. Moreover, the ovary cancer had spread to the abdominal organs, including the kidneys, and to multiple lymph nodes. Maybe one of the cause of her death was the probable spillage of tumor intraoperatively.

The aim of this case report is to announce the importance of the differential diagnosis and treatment of hypercalcemia in ovarian cancer, which is very rare. Moreover, anticancer therapy is necessary. Although we resolved the hypercalcemic crisis, the patient died because of the progress and poor performance of the underlying disease, the mucinous ovary cancer. This case reflects the results of a previous study by Schwartz and Skinner (2013) that hypercalcemia is a poor prognosis factor alone, and that there is a positive association between the degree of serum calcium level and the progress of ovarian cancer [12]. They also stated that the risk for fatal ovarian cancer was 52% higher for each 0.1 mmol/L increase in total serum calcium level [12]. Another research revealed that PTH-rP overexpression is related to suppressing apoptosis, promoting tumor cell growth, migration and invasion through the PI3K-Akt-NF-kB pathway [13]. In our patient, the elevated serum level of PTH-rP seemed to be closely related to the fatal result, given the aforementioned associations. In other words, the rapid progression of metastasis to multiple organs and PMP in our patient could have been promoted by overexpression of PTH-rP.

Considerable controversy surrounds the origin of PMP, but recent research has shown that it is the appendix, not the ovaries [14]. However, in our patient, the appendix was clear intraoperatively. Moreover, in the process of removing the ovary tumor, spillover may have occurred into the

abdominal cavity, and the patient died from the rapidly deteriorating PMP. This case shows that the claim that the appendix is the origin of the PMP should be reconsidered.

In summary, the present study reported a case of hypercalcemia associated with primary mucinous ovarian tumor followed by PMP. The laboratory findings of PTH-rP and PTH, thyroid sonography, and PET-CT were useful in differential diagnosis. Based on the different etiologies of hypercalcemia, an adequate treatment should be treated first, but the ultimate goal of these patients should be treatment for the primary cancer.

### Ethics approval and consent to participate

All subjects gave their informed consent for inclusion before they participated in the study. The study was conducted in accordance with the Declaration of Helsinki,

### Acknowledgements

Thanks to all the peer reviewers and editors for their opinions and suggestions.

### Conflict of Interest

The authors have no conflicts of interest to declare.

Submitted: February 05, 2020

Accepted: April 01, 2020

Published: October 15, 2020

### References

- [1] Goldner W.: "Cancer-Related Hypercalcemia". *Journal of Oncology Practice*, 2016, 12, 426-432.
- [2] Stewart A.F.: "Hypercalcemia Associated with Cancer". *N. Engl. J. Med.*, 2005, 352, 373-379.
- [3] Ma X.G., Wang Y.M., Zhang X.H., Dong M.T., Yang W., Xue F.X.: "Ovarian cancer presenting with hypercalcemia: two cases with similar manifestations but different mechanisms". *Cancer Biol Med.*, 2018, 15, 182-187.
- [4] Xuegong M., Yingmei W., Xuhong Z., Mengting D., Wen Y., Xue F.X.: "Ovarian cancer presenting with hypercalcemia: two cases with similar manifestations but different mechanisms". *Cancer Biology & Medicine*, 2018, 15, 182.
- [5] Qu Z.: "Management of pseudomyxoma peritonei". *World J. Gastroenterol.*, 2006, 12, 6124.
- [6] Lieske B., Moran B.: "Pseudomyxoma peritonei". *Intraperitoneal Cancer Therapy*, 2015, 225-234.
- [7] Faris J.E., Ryan D.P.: "Controversy and Consensus on the Management of Patients With Pseudomyxoma Peritonei". *Curr. Treat. Options Oncol.*, 2013, 14, 365-373.
- [8] Santaripa L., Koch C.A., Sarlis N. J.: "Hypercalcemia in Cancer Patients: Pathobiology and Management". *Horm. Metab. Res.*, 2010, 42, 153-164.
- [9] Baird G.S.: "Ionized calcium". *Clin. Chim. Acta*, 2011, 412, 696-701.
- [10] Mundy G.R., Edwards J.R.: "PTH-Related Peptide (PTHrP) in Hypercalcemia". *J. Am. Soc. Nephrol.*, 2008, 19, 672-675.
- [11] Reagan P., Pani A., Rosner M. H.: "Approach to Diagnosis and Treatment of Hypercalcemia in a Patient With Malignancy". *Am. J. Kidney Dis.*, 2014, 63, 141-147.
- [12] Schwartz G.G., Skinner H.G.: "Prospective studies of total and ionized serum calcium in relation to incident and fatal ovarian cancer". *Gynecol. Oncol.*, 2013, 129, 169-172.
- [13] Shen X., Mula R.V.R., Evers B.M., Falzon M.: "Increased cell survival, migration, invasion, and Akt expression in PTHrP-overexpressing LoVo colon cancer cell lines". *Regul. Pept.*, 2007, 141, 61-72.
- [14] Morera-Ocon F.J., Navarro-Campoy C.: "History of pseudomyxoma peritonei from its origin to the first decades of the twenty-first century". *World J Gastrointest Surg*, 2019, 11, 358-364.

Corresponding Author:

YOUNGSUN KIM, M.D., Ph.D.

Department of Obstetrics and Gynecology

Kyung Hee Medical Center, College of Medicine,

Kyung Hee University, Kyungheedaero 23,

Dongdaemungu, Seoul, +82 (Republic of Korea)

e-mail : chacha0725@naver.com