

Primary cervical choriocarcinoma with germ cell tumor: a case report with literature review

P. Lu¹, D. Wu¹, X.X. Yue¹, J.W. Miao², Y.M. Wu³

¹The Medicine Department of Obstetrics and Gynecology, Capital Medical University, Beijing

²Department of Gynecology Tumor, Beijing Obstetrics and Gynecology Hospital, Capital Medical University,

³Beijing Maternal and Child Health Care Hospital, Beijing (China)

Summary

Background: Gestational trophoblastic diseases (GTD) is a series of malignant cancer can be subdivided in pregnancy-associated disease or non-pregnancy choriocarcinoma. The latter among the GTD is extremely rare, particularly primary cervical choriocarcinoma. **Case Report:** The authors present a case of primary cervical choriocarcinoma with germ cell tumor which is rarely reported. A 46-year-old female visited Beijing Obstetrics and Gynecology hospital because of irregular vaginal bleeding who had undergone radical cervical cancer surgical treatment. After surgery, her symptoms were not visibly changed and the result of pathology suggested cervical cancer. Finally, the authors confirmed its non-gestational origin with ovarian yolk sac tumor by immunohistochemical staining and the level of serum beta-hCG. Fortunately, multiple courses of chemotherapy with BEP regimen were effective for this case. **Conclusion:** During the course of diagnosis and therapy, immunohistochemical staining and the level of beta-hCG are useful. We could distinguish The tissue origin of this tumor with cervical cancer was distinguished and early diagnosis contributed to the therapy of this disease.

Key words: Choriocarcinoma; Primary cervical choriocarcinoma; Diagnosis; Immunohistochemistry; β -hCG.

Introduction

Choriocarcinoma is a tumor that occurs most commonly in the uterus. Extrauterine choriocarcinoma is rarely seen in clinical practice and has been reported to almost occur in the ovaries, fallopian tubes, and elsewhere in the pelvis [1]. Primary cervical choriocarcinoma, which mainly presents cervical mass and vaginal bleeding, is similarly to cervical cancer. Therefore, accurate diagnosis of its clinical course is necessary. Here the authors report an extremely rare case that was diagnosed with primary cervical choriocarcinoma with germ cell tumor, and review the related literature.

Case Report

A 46-year-old female was admitted to this hospital for continuous vaginal bleeding on September 23th, 2016. Three months prior, she had undergone hysteroscopy and curettage at the local hospital because of irregular vaginal bleeding. The result of histology suggested that it was adenocarcinoma sited in the uterine cavity and cervical canals, which was considered as endometrioid adenocarcinoma (middle-low differentiation), with the exception of adenocarcinoma from cervical canals. She had regular menstrual cycle and was gravida 3 para 1. Her last pregnancy ended in full term delivery in 2007. Her first and second unplanned pregnancies were ended by drug abortion in 2009 and 2013, respectively.

After the woman came to the hospital, her pathological tissues were diagnosed as middle-low adenocarcinoma from pelvic cavity

and cervical, and the tissues effluent from cervical canals were confirmed with middle-low differentiation and poorly differentiation adenocarcinoma by histopathology, part of cytoplasm showed transparent (clear cell carcinoma), and papillary formation in some part (Figure 1). The level of serum β -hCG was not clear, and other tumor markers proved negative (carcinoembryonic antigen, cancer antigen 125, and cancer antigen 199). The gynecological examination showed multiple uterine myomas and the patient was submitted for routine clinical and laboratory evaluation, such as chest radiography, abdominal ultrasonography and pelvic MRI, and so on. There was no pathologic finding in her tests (chest X-ray, blood count, and blood chemistry). MRI revealed that it was cervical cancer (FIGO Stage IB) with a suspicious lymph node on the left side of pelvic cavity and the anterior wall of uterine myoma.

Two days later she presented to the hospital and underwent laparoscopic radical hysterectomy with bilateral salpingo-oophorectomy and pelvic lymph node dissection, para-aortic lymphadenectomy, and bilateral infundibulopelvic ligaments' ligation on September 26th, 2016. Post-operative studies confirmed that there were a couple of myomas found in the anterior and posterior of the uterus, with cervical enlargement, and a cauliflower-like mass with a maximum of 2+ centimeters (cm) diameter was observed in cervical canal which invaded stroma with depth of 1/2, the right lymphadenovarium with maximum of 1.5 cm, and behind the external iliac lymph node was enlarged to 1 cm. Pathologic evaluation of the surgical specimens including histopathology and immunohistochemical demonstrated that trophoblastic tumor with hemorrhage and necrosis was observed locally in the cervix which was considered a choriocarcinoma and could not exclude epithelioid trophoblastic tumor (1.0×0.6 cm), and the remaining cervix was confirmed as adenocarcinoma in situ (AIS) (Figures 1 and

Revised manuscript accepted for publication July 16, 2018

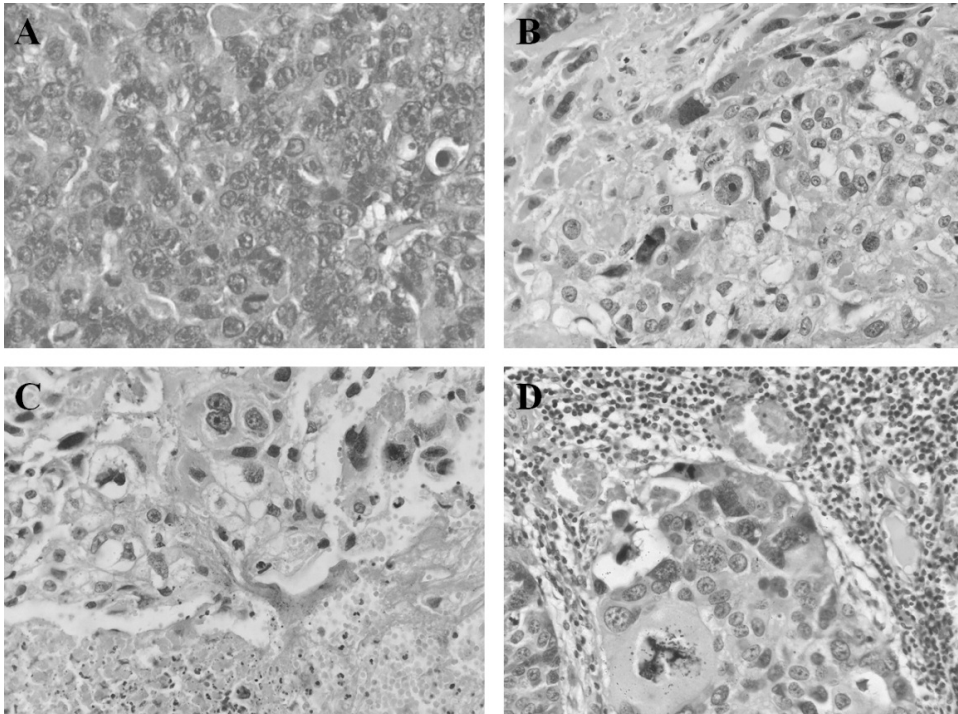


Figure 1. — (A) The tissues effluented from cervical canals show that the gland epithelium has atypical hyperplasia and part of cytoplasm shows transparent (clear cell carcinoma) and papilla formation (Hematoxylin–Eosin $\times 400$). (B–C) Cervical mass illustrates both neoplastic cytotrophoblast and syncytiotrophoblast with many erythrocytes and necrosis (Hematoxylin–Eosin $\times 400$). (D) Lym-phatic metastasis (Hematoxylin–eosin $\times 400$).

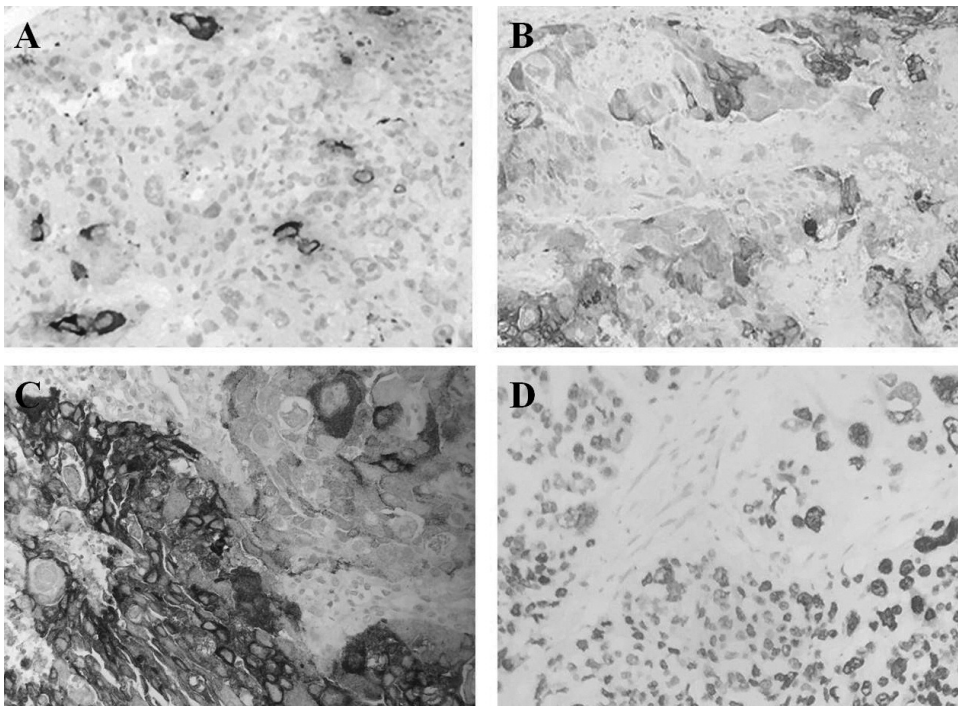


Figure 2. — Positive reactions of cancer cells with hCG (A), Inhibin (B), PALP (C), and SALL4 (D) revealed by immunohistochemistry ($\times 400$).

2). The pathological tissues combined with immunohistochemical staining and inhibin together with HCG, EMA, CK7, PLAP, SALL4, α -inhibin, and p16 diffusely positively stained in tumoral tissue consulted by Cancer Hospital Chinese Academy of Medical Sciencem as well as revealed that the uterus and the rotor from uterine cavity were a mixed germ cell tumor, which were firstly considered as choriocarcinoma and yolk sac tumor (Figure 2). Postoperative period was excellent and the drainage tube was re-

moved nine days after surgery.

An interval of approximately one month then passed during which the patient underwent operation until she received chemotherapy. On examination, there was no visible or palpable abnormality. The level of β -hCG was 37.21 U/L, and a week later the level of β -hCG increased to 75.21 U/L. Two weeks passed, the β -hCG slowly increased to 91.91 U/L. Chest computer digital CT showed nodes with an approximate diameter of 0.5 cm in superior

lobe of right lung and inferior lobe of left lung, which were diagnosed as inflammation and obsolete focus in bilateral pulmonary. On November 15th, 2016, the patient received the first stage chemotherapy with bleomycin for three days (10 mg/m²), etoposide for five days (60 mg/m²) and cis-platinum 20 mg for five days. Prior to chemotherapy, the patient was given 10 mg of dexamethasone to prevent an allergic reaction. There was no adverse event with regards to her therapy.

Discussion

Choriocarcinoma which is highly malignant but curable, with remission rates quoted at approximately 80%-90% in the era of modern chemotherapy represents a malignant form of GTD [2]. While choriocarcinoma can be subdivided in gestational and non-gestational disease. The former is the result of a pregnancy and is usually located in the uterine cavity, but it can also be found rarely in the ovaries, fallopian tubes, vagina, vulva, cervix or pelvic region [3]. However, the cause of non-gestational choriocarcinoma is not clear, and it is often found outside of the uterus. Non-gestational choriocarcinoma is very rare and a particularly primary cervical choriocarcinoma. Furthermore the phenomenon of choriocarcinoma coexisting with other malignancies is generally lacking in case reports.

The pathogenesis of primary cervical choriocarcinoma is largely unknown, which may arise from metaplastic transformation of epithelial tissue [4]. Similar to the presented case, such a kind of cervical carcinoma is sometimes difficult to reach a prompt and accurate diagnosis, especially based on clinical features and intraoperatively. It can be easily misdiagnosed as cervical cancer because of the characteristics similarity. However, the level of β -hCG and immunohistochemistry are potentially valuable tools to confirm the diagnosis.

Germ cell tumor is the mainly a common ovarian malignancy in reproductive women and accounts for about two-thirds of the ovarian cancers [5]. Malignant ovarian germ cell tumors are classified as dysgerminoma and non-dysgerminoma. The latter commonly includes neoplasms that contain teratoma, embryonal, yolk sac tumor, and/or choriocarcinoma elements [6]. Ovarian yolk sac tumor (OYST) also known as endodermal sinus tumor, is a highly malignant germ cell tumor and is highly aggressive whose five-year survival rates are unclear because of differing stages [7]. Preoperative clinical and biological (alpha-fetoprotein, AFP) examinations are helpful to diagnose OYST. Adequate surgical treatment in removing the primary tumor is effective in this patient, but fertility-sparing surgery and chemotherapy with the BEP are important [8]. Therefore to obtain an accurate histological diagnosis and to assess the disease extent are critical.

Sal-like protein 4 (SALL4) is a zinc-finger transcription factor mainly expressed in embryonic stem cells and important during embryonic development [9]. Such expression may reflect stem-cell like differentiation and must be

considered when using SALL4 as a marker for germ cell tumors. SALL4 transcription factor is associated with embryonic cell pluripotency and has proven to be a useful immunohistochemical marker for germ cell tumors [10]. Embryonal carcinoma of ovary is usually present along with other components, such as dysgerminoma and immature teratoma. However OYST with choriocarcinoma is severely presented. The present authors found SALL4 to be positive with immunohistochemical in their patient (Figure 2).

Here the authors reported a woman diagnosed with primary cervical cancer with OYST, and this present case exhibited the required pathological and immunohistochemistry characteristics, as described in the previously reported cases, to determine a diagnosis of choriocarcinoma with other malignant cancer. Pure choriocarcinoma is sensitive to chemotherapy which is curable though chemotherapy, but in non-gestational choriocarcinoma, such as primary cervical cancer which could be transformed by cervical cancer, surgery is needed because of cervical tumor and its low responsiveness to chemotherapy. Serum β -hCG might not be detected in those cases with usual protocols. Choriocarcinoma has a very good prognosis even in advanced stages because it is a chemosensitive tumor type; the accurate diagnosis is necessary. Immunohistochemical staining and the level of β -hCG are helpful tools for these patients which are suspected to have a histological tumoral type.

References

- [1] Udare AS., Mondel PK.: "Extrauterine choriocarcinoma: another uncommon primary pelvic retroperitoneal mass seen in adults". *RadioGraphics*, 2013, 33, 301.
- [2] Morgan J.M., Lurain J.R.: "Gestational trophoblastic neoplasia: an update". *Curr. Oncol. Rep.*, 2008, 10, 497.
- [3] Mitrovic S.L.J., Arsenijevic P.S., Kljakic D., Djuric J.M., Milosavljevic M.Z., Protrka Z.M., et al.: "Gestational choriocarcinoma of the cervix". *Arch. Iran. Med.*, 2014, 17, 783.
- [4] Morimura Y., Yazawa M., Hoshi K., Takano Y., Hang X.L., Honda T., et al.: "Uterine cervical clear-cell adenocarcinoma with a choriocarcinomatous component: a case report". *J. Obstet. Gynaecol. Res.*, 1996, 22, 437.
- [5] Bel Haj Salah M., Brahim E.B., Zidi Y.S., Tangour M., Kilani H., Chatti-Dey S.: "Mixed germ cell tumor of the ovary with rhabdomyosarcomatous component. A case report". *Ann. Pathol.*, 2010, 30, 394.
- [6] Viana L.S., Tsunoda A.T., Nunes J.S., Fregnani J.H., Vieira M.A., Borges A.K., et al.: "Preservation of pregnancy in a patient with acute abdominal pain secondary to advanced and hemorrhagic yolk sac tumor of the right ovary". *J. Clin. Oncol.*, 2011, 29, e758.
- [7] Goyal L.D., Kaur S., Kawatra K.: "Malignant mixed germ cell tumour of ovary—an unusual combination and review of literature". *J. Ovarian Res.*, 2014, 7, 91.
- [8] Even C., Lhommé C., Duvillard P., Morice P., Balleyguier C., Pautier P., et al.: "Ovarian yolk sac tumour: general review". *Bull. Cancer*, 2011, 98, 963.
- [9] Yang J., Chai L., Fowles T.C., Alipio Z., Xu D., Fink L.M., et al.: "Genome-wide analysis reveals SALL4 to be a major regulator of pluripotency in murine-embryonic stem cells". *Proc. Natl. Acad. Sci. U S A*, 2008, 105, 19756.

- [10] Miettinen M., Wang Z., McCue P.A., Sarlomo-Rikala M., Rys J., Biernat W., et al.: "SALL4 expression in germ cell and non-germ cell tumors: a systematic immunohistochemical study of 3215 cases". *Am. J. Surg. Pathol.*, 2014, 38, 410.

Corresponding Author:
JIN-WEI MIAO, Ph.D.
Department of Gynecologic Oncology
Beijing Obstetrics and Gynecology Hospital
Capital Medical University
Beijing Maternal and Child Health Care Hospital
(10)10026 Beijing (China)
e-mail: miaojinweigyn@163.com