

# Malignancy-transformed mature cystic teratoma surgical treatment requires comprehensive staging procedures including pelvic/para-aortic lymphadenectomy

B. Barczyński<sup>1</sup>, K. Frąszczak<sup>1</sup>, M. Bilski<sup>2</sup>, J. Szumiło<sup>3</sup>, I. Wertel<sup>1</sup>, M. Sobstyl<sup>4</sup>, G. Polak<sup>1</sup>, L. Grzybowska-Szatkowska<sup>5</sup>, J. Kotarski<sup>1</sup>

<sup>1</sup>Department of Oncological Gynaecology and Gynaecology, Medical University of Lublin, Lublin

<sup>2</sup>Nu-med, Center of Oncology Diagnostics and Therapy, Zamość

<sup>3</sup>Department of Clinical Pathomorphology, Medical University of Lublin, Lublin

<sup>4</sup>Department of Gynaecology and Gynaecological Endocrinology, Medical University of Lublin, Lublin

<sup>5</sup>I Department of Radiation Therapy, Center of Oncology of the Lublin Region St. John from Dukla, Lublin (Poland)

## Summary

This report presents the case of squamous cell cancer (SCC) originating from a mature cystic teratoma (MCT) diagnosed in pregnant women, in whom retroperitoneal spread to para-aortic lymph nodes was confirmed as the only evidence of extraovarian disease in a relatively short time after primary tumor excision. The 35-year-old multipara was diagnosed in early pregnancy with an ovarian tumor. The patient qualified for elective caesarean section with left ovarian cystectomy. Pathological result proved SCC in MCT and the patient underwent debulking surgery without total pelvic and para-aortic lymphadenectomy. Final staging confirmed ovarian malignancy FIGO IA, and no adjuvant treatment was recommended. Early imaging examination during routine follow-up demonstrated enlarged para-aortic lymph nodes and the patient qualified for total pelvic and para-aortic lymphadenectomy. Postoperative pathology result confirmed metastases in para-aortic lymph nodes and standard adjuvant chemotherapy was administered.

**Key words:** Malignancy-transformed mature cystic teratoma; Para-aortic lymphadenectomy.

## Introduction

The diagnosis of ovarian tumor in pregnancy is rare but not uncommon, and risk of malignancy has been reported to be 2% to 3% of all ovarian masses diagnosed during pregnancy [1]. Most commonly diagnosed ovarian tumors in pregnant women are germ-cell and epithelial tumors [2]. Benign mature cystic teratoma (MCT) is one of the germ cell tumors arising in the ovary. It comprises of well-differentiated tissues derived from all germ layers. Since benign teratomas are totipotent tumors, any type of malignant transformation or combination of malignancies can be expected. Generally, malignant changes rarely occur in MCTs with squamous cell carcinoma (SCC), and adenocarcinoma being the most common [3]. Due to relative rarity of invasive SCC arising in MCT, commonly used conventional imaging techniques (ultrasound scan and MRI) are not sensitive and specific enough to establish the definite diagnosis unequivocally. Similarly, there is no clear consensus regarding treatment of such neoplasms. In general, it is recommended to treat the patient according to guidelines for malignant ovarian germ cell tumours and epithelial ovarian cancers (e.g. according to National Comprehensive Cancer Network or European Society of Gy-

necological Oncology recommendations). Such treatment depends on FIGO classification and desire of preserving fertility. Nevertheless, even in early FIGO stages of the disease, recommended treatment should include comprehensive staging procedures (peritoneal washing cytology, pelvic/para-aortic lymphadenectomy, omentectomy, multiple biopsies on suspicious lesions, and random biopsies of peritoneum), which remains controversial for some oncologic centres. Considering the fact, that most malignant ovarian germ cell tumours are diagnosed in FIGO stage IA, and exhibit excellent sensitivity to chemotherapy, there is no consensus whether such extensive staging procedures in patients with no macroscopic evidence of intra- and extraperitoneal spread are absolutely necessary, particularly regarding lymphadenectomy.

As a general rule, surgical treatment during pregnancy is indicated only for tumors that are symptomatic or highly suspicious for malignancy due to rapid growth and/or associated with ascites and other evidence of extraovarian disease [1]. Vast majority of stable and asymptomatic tumors are usually appropriate for expectant management with surgery to occur during elective caesarean section or postpartum [1, 4].

The authors present a case of a woman diagnosed in early

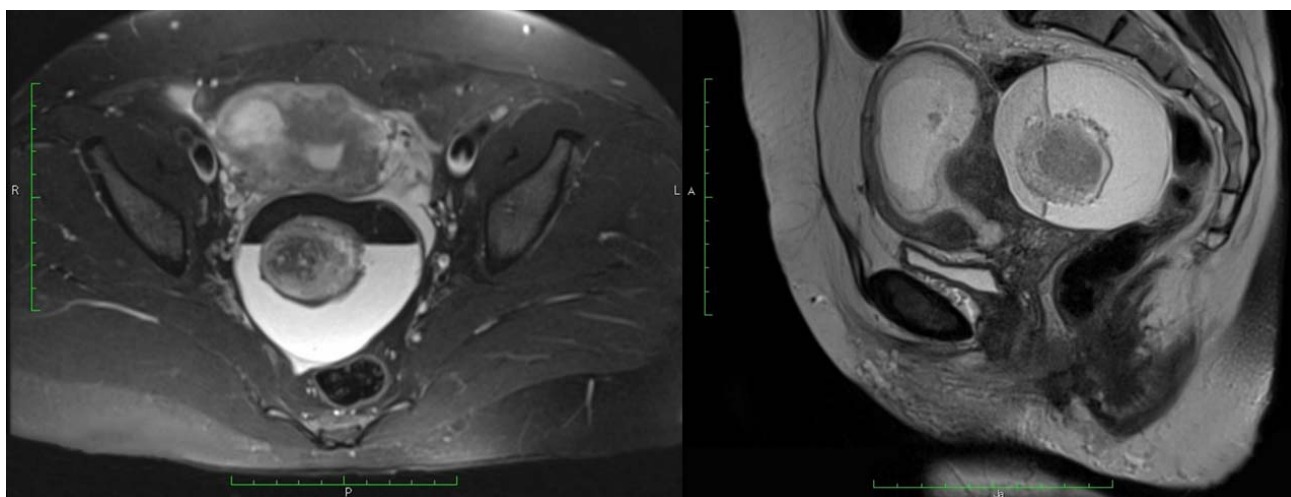


Figure 1. — Axial and sagittal MRI showing left ovarian fluid cyst with a two-phase liquid-fat system. Centrally inside the cyst, a spherical lesion with heterogeneous signal intensity and a diameter of about 40 mm (most likely a thrombus) is identified.

pregnancy with ovarian tumor, which was excised during elective caesarean section, and pathology report confirmed invasive SCC arising in mature cystic teratoma. The patient underwent suboptimal surgical procedure and developed early extraperitoneal recurrence of the disease.

### Case Report

The 35-year-old multipara was admitted to hospital in her ninth week of a fourth gestation with lower abdominal pressure. Her medical history included gastritis with *Helicobacter pylori* infection. Routine gynecological pelvic examination confirmed solid pelvic mass and the patient qualified for additional imaging examination. She underwent transvaginal ultrasound and pelvic MRI. Ultrasound examination showed unilocular 83-mm-diameter left ovarian cyst with the presence of echogenic dots in cyst fluid, with a 40-mm-diameter solid hyperechogenic component (so-called white-ball) showing no detectable Doppler signal, and posterior shadowing – most characteristic features of a teratoma. MRI presented enlarged uterine muscle with the foetus and left ovarian fluid cyst: 83 × 75 × 72 mm, with a two-phase liquid-fat system. Centrally inside the cyst, a spherical lesion with heterogeneous signal intensity and a diameter of about 40 mm (most likely a thrombus) was identified (Figure 1). Apart from routine laboratory tests, which showed no significant abnormalities, she had negative tumor markers (CA15-3, CA 19-9, CA-125) and ROMA test performed with the risk of malignancy of 3.67%. Tumor was classified as potentially benign and the patient was discharged from the hospital with no pain symptoms and recommendation of routine perinatal care. She had routine first, second, and third trimester ultrasound scans which showed no tumor growth during pregnancy. Finally the patient qualified for elective caesarean section in 36th week of pregnancy with left ovarian cystectomy or left adnexectomy. During laparotomy, careful

visual inspection of the entire abdominal cavity was performed and no signs of intraperitoneal spread of the disease was diagnosed. She delivered a healthy newborn by caesarean section and ovarian cystectomy was performed. Final pathology result demonstrated squamous cell G2 cancer in 70-mm-diameter MCT (Figure 2). Subsequently, five weeks later, the patient who did not want to preserve fertility qualified for standard debulking surgery (total hysterectomy, bilateral salpingo-oophorectomy, omentectomy, and appendectomy) with comprehensive staging procedures including pelvic (and not para-aortic) lymph node sampling. Postoperative pathology result showed no evidence of the disease (pT0N0M0). Final staging was ovarian malignancy FIGO IA and no adjuvant chemotherapy was administered. Routine follow-up CT and PET scan performed two months after debulking surgery demonstrated enlarged para-aortic lymph nodes. The patient qualified for total pelvic and paraaortic lymphadenectomy and postoperative pathology result confirmed metastases in para-aortic lymph nodes, what upstaged her to FIGO IIIA1. As a continuation of treatment she received six courses of adjuvant chemotherapy (paclitaxel plus cisplatin) with good general tolerance. She completed her first-line chemotherapy and she is now under careful observation with 24 months of disease-free survival.

### Discussion

Malignant transformation of MCT is an extremely rare clinical condition and has been reported in literature only sporadically. Thus, its detailed epidemiological and clinical characteristics is poorly known, and methods of preoperative diagnosis and treatment protocols still remain challenging for gynaecologic surgeons. In most cases, the diagnosis is unexpected, based on postoperative pathology report. Risk factors of malignancy in MCT include patient age, tumor size, serum markers, and imaging character-

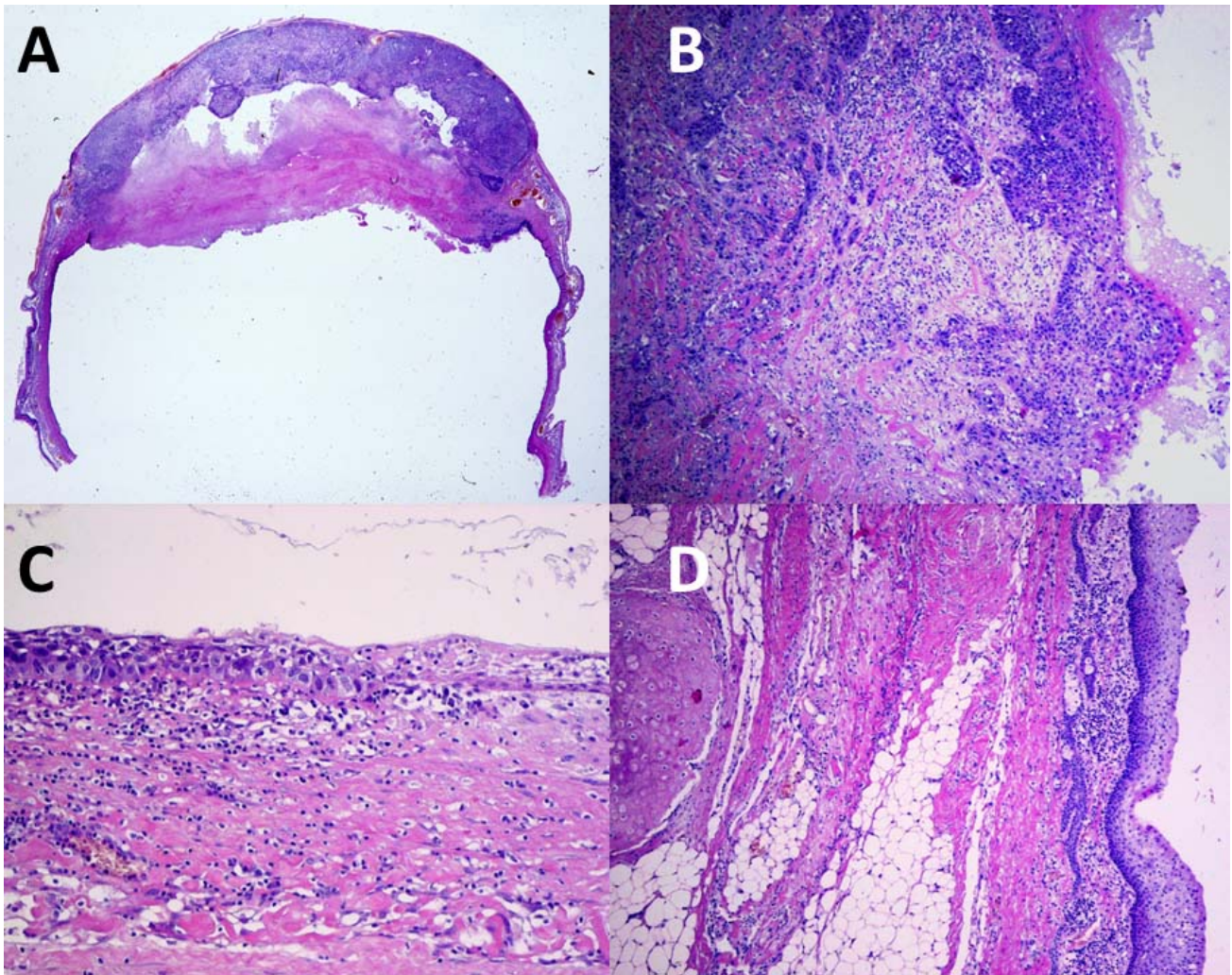


Figure 2. — Gross examination of resected ovary revealed cystic tumor sized  $70 \times 70 \times 60$  mm composed of squamous cell carcinoma originating from a mature teratoma (A). The cyst is filled with hairs and sebaceous masses. Microscopic examination of the solid part of the tumor shows partly necrotic squamous cell carcinoma G2 with no features of tunica albuginea infiltration (B). The cyst is covered by normal keratinised squamous epithelium partly with features of carcinoma in situ (C). At the edges of the tumor mature teratoma elements are identified (D) (H+E staining).

istics. Retrospective analyses prove that vast majority of SCC in MCTs are diagnosed in peri- and postmenopausal women, with only small number of cases in patients in typical reproductive age (approximately 15% of cases in women < 40 years of age) [5]. Some authors conclude that combination of two criteria: patient's age less than 40 and serum SCC antigen concentration less than 2.5 ng/ml, may be considered reliable factors for differential diagnosis between benign and malignancy-transformed MCT [6]. Similarly, patients > 60-years-old, who have unilateral MCT with SCC antigen value of  $\geq 2.0$  ng/ml and tumor  $\geq 10$  cm, may be a high-risk group for malignant transformation [7]. According to other retrospective study, the mean age at the diagnosis of patients with malignant transformation of MCT was 43.0 years, which was higher than that of patients with benign disease (36.5 years) [8]. The size of the lesion is also considered to be a risk factor for malignancy.

Although MCTs are diagnosed in a wide range of dimensions, malignant transformation is generally detected in larger tumors. In the study of Kikkawa *et al.*, the mean diameter of MCT with SCC transformation was 152 mm, and the authors conclude to implement differential diagnosis in all patient with MCT-like ovarian tumors in patient > 45 years of age with tumors > 99 mm in greatest dimension [9]. Similarly, malignancy-transformed MCT mean tumor size larger than 100 mm was found in other studies, including case-reports [6, 8, 10]. Although the usefulness of serum markers in malignancy-transformed MCT is not clearly proved, it is a standard to evaluate panel of markers preoperatively in differential diagnosis of all ovarian tumors. Some authors demonstrate that CA125 and CA-19.9 may have some predictive value [11], whereas others do not confirm this [6]. Kikkawa *et al.* suggest that SCC antigen, and CEA may serve as useful serum markers in differential

diagnosis of malignancy-transformed MCT [9].

As MCTs are composed of well-differentiated tissues delivered from all germ layers, ultrasound and MRI show various patterns. Thus, it is almost impossible to make a reliable preoperative diagnosis of malignant changes in MCTs even if examination was performed by ultrasound or radiology expert. MCT is ultrasonographically presented as a uni- or multilocular cyst, showing heterogeneous internal echos in the cyst with acoustic shadows, and multiple hyperechoic fine lines and dots, which are due to reflection by clumps of hair, sebum, or fat component within the mass. In some cases, there is a presence of well defined solid hyperechoic round nodule within the cystic mass [12]. Similarly, typical enhancing solid component visualised during MRI examination is more likely benign than indicative of malignant transformation and is identified postoperatively as glial tissue, thyroid tissue, fibrous stroma, or vessels [13].

To summarize, diagnosis of malignant transformation in MCT is extremely difficult and in most cases impossible, especially in young, reproductive-aged women. Diagnostic process is far more difficult in pregnant women. In this presented case, retrospective analysis of all risk factors did not demonstrate any possibility of malignancy in MCT. The patient was young (35-years-old), tumor size was relatively small (83 mm in diameter), serum tumor markers and ROMA test were negative, and commonly used imaging techniques showed typical MCT. Thus, an expectant management was chosen, and the patient was recommended elective caesarean section in 36th week of gestation with concurrent tumor resection. As soon as the postoperative pathology result proved squamous-cell malignant transformation, the patient was re-operated and underwent standard debulking surgery and comprehensive staging.

In the presented case, the authors did not decide to perform complete pelvic- and para-aortic lymphadenectomy as a standard procedure. In the present authors' opinion, there is no strong data in the literature regarding survival benefits for patients with non-epithelial gynaecological malignancies. Furthermore, there are no established standard treatment procedures in case of specific rare ovarian tumors like malignancy-transformed MCT. Therefore, due to lack of definite treatment strategy, most authorities recommend to surgically treat such ovarian malignancy as epithelial neoplasm, the disease with completely different biology. Nevertheless, according to many authors, the utility of lymph node dissection in malignancy-transformed MCT is controversial since the mode of spread is generally by direct extension or peritoneal seeding [14, 15]. In this particular case, the decision to avoid extensive lymphadenectomy was also made to avoid severe complications in postpartum patient such as abdominal incisional pain, excessive bleeding, infection, or intestinal obstruction, not to mention the delay it would cause to postoperative adjuvant therapy, if indicated, waiting for the large wound to heal [16]. Undoubtedly, total lymphadenectomy may influence adjuvant treatment planning, especially in early-stage malignant disease.

In the presented case, the patient initially staged FIGO IA did not receive adjuvant chemotherapy, and upstaging her to FIGO IIIA1 resulted in adjuvant chemotherapy administration.

To conclude, malignant transformation of MCT, due to its rare incidence and non-specific presentation, remains a diagnostic and therapeutic dilemma. Based on the present authors experience with this disease and literature data, they suggest careful and thorough preoperative assessment of all multilocular solid cysts in young women, even if serum markers suggest low risk of malignancy. Although there is no consensus regarding treatment of such tumors, optimal cytoreduc should be performed in all patients who do not wish to preserve fertility. To the present authors' knowledge, it is the first case of SCC arising in MCT diagnosed in pregnant women, in whom retroperitoneal spread to para-aortic lymph nodes was confirmed as the only evidence of extraovarian disease in short time after elective caesarean section with concurrent initial primary tumor excision.

#### Authors' contributions

BB, KF, MB, IW, MS, GP designed the research study. JS performed immunohistochemical examinations. LGS, JK analyzed data. BB, KF, MB wrote the manuscript. All authors contributed to editorial changes in the manuscript. All authors read and approved the final manuscript.

#### Ethics approval and consent to participate

The patient gave her consent for all or any part of this material to appear in EJGO medical journal.

#### Acknowledgments

This study was supported by grants from Medical University of Lublin (NO. DS 120/2019).

#### Conflict of interest

There are no conflicts of interest to declare for any of the authors.

Submitted: January 27, 2019

Accepted: April 01, 2019

Published: June 15, 2020

#### References

- [1] Leiserowitz G.S., Xing G., Cress R., Brahmabhatt B., Dalrymple J.L., Smith L.H.: "Adnexal masses in pregnancy: how often are they malignant?". *Gynecol. Oncol.*, 2006, 101, 315.
- [2] Sayar H., Lhomme C., Verschraegen C.F.: "Malignant adnexal masses in pregnancy". *Obstet. Gynecol. Clin. North. Am.*, 2005, 32, 569.
- [3] Goudeli C., Varytimiadi A., Koufopoulos N., Syrios J., Terzakis E.: "An ovarian mature cystic teratoma evolving in squamous cell carcinoma: A case report and review of the literature". *Gynecol. Oncol. Rep.*, 2016, 18, 27.
- [4] Marino T., Craig S.D.: "Managing adnexal masses in pregnancy". *Contemp. Ob/Gyn.* 2000, 45, 130.
- [5] Chen R.J., Chen K.Y., Chang T.C., Sheu B.C., Chow S.N., Huang S.C.: "Prognosis and treatment of squamous cell carcinoma from a

- mature cystic teratoma of the ovary". *J. Formos. Med. Assoc.*, 2008, 107, 857.
- [6] Mori Y., Nishii H., Takabe K., Shinozaki H., Matsumoto N., Suzuki K., et al.: "Preoperative diagnosis of malignant transformation arising from mature cystic teratoma of the ovary". *Gynecol. Oncol.*, 2003, 90, 338.
- [7] Yamanaka Y., Tateiwa Y., Miyamoto H., Umemoto Y., Takeuchi Y., Katayama K., Hashimoto K.: "Preoperative diagnosis of malignant transformation in mature cystic teratoma of the ovary". *Eur. J. Gynaecol. Oncol.* 2005, 26, 391.
- [8] Park C.H., Jung M.H., Ji Y.I.: "Risk factors for malignant transformation of mature cystic teratoma". *Obstet. Gynecol. Sci.* 2015, 58, 475.
- [9] Kikkawa F., Nawa A., Tamakoshi K., Ishikawa H., Kuzuya K., Suganuma N., et al.: "Diagnosis of squamous cell carcinoma arising from mature cystic teratoma of the ovary". *Cancer*. 1998, 82, 2249.
- [10] Togami S., Kawamura T., Kamio M., Douchi T.: "A rare case of microinvasive squamous cell carcinoma arising in mature cystic teratoma of the ovary". *Eur. J. Gynaecol. Oncol.* 2016, 37, 420.
- [11] Kawai M., Kano T., Kikkawa F., Morikawa Y., Oguchi H., Nakashima N., et al. "Seven tumor markers in benign and malignant germ cell tumors of the ovary". *Gynecol. Oncol.* 1992, 45, 248.
- [12] Jung S.I.: "Ultrasonography of ovarian masses using a pattern recognition approach". *Ultrasonography*. 2015, 34, 173.
- [13] Shin H.J., Kim K.A., Kim B.H., Lee J.K., Park Y.S., Lee J., et al.: "Benign enhancing components of mature ovarian teratoma: magnetic resonance imaging features and pathologic correlation". *Clin. Imaging*, 2016, 40, 1156.
- [14] Dos Santos L., Mok E., Iasonos A., Park K., Soslow R.A., Aghajanian C., et al.: "Squamous cell carcinoma arising in mature cystic teratoma of the ovary: a case series and review of the literature". *Gynecol. Oncol.*, 2007, 105, 321.
- [15] Ülker V., Gedikbasi A., Numanoglu C., Ozluk Y., Saygi S., Gulkiplik A., Salihoglu Y.: "Mucinous adenocarcinoma arising in ovarian mature cystic teratoma in pregnancy". *Arch. Gynecol. Obstet.* 2009, 280, 287.
- [16] Kusunoki S., Huang K.G., Magno A., Lee C.L.: "Laparoscopic technique of para-aortic lymph node dissection: A comparison of the different approaches to trans- versus extraperitoneal para-aortic lymphadenectomy". *Gynecol. Minim. Invasive. Ther.* 2017, 6, 51.

Corresponding Author:

B. BARCZYŃSKI, M.D.

I Department of Oncological Gynaecology  
and Gynaecology, Medical University of Lublin  
Lublin (Poland)

e-mail: bbarczynski@poczta.onet.pl