

# Primary fallopian tube carcinoma clinically manifested as vaginal adenocarcinoma in a post-hysterectomy patient: a case report and literature review

Mingming Sun<sup>1,2</sup>, Tong Gao<sup>1,2</sup>, Yuqing Zhao<sup>1,2</sup>, Weiguo Hu<sup>1,2</sup>, Wei Jiang<sup>1,2</sup>

<sup>1</sup>Department of Gynecology, Obstetrics and Gynecology Hospital of Fudan University

<sup>2</sup>Shanghai Key Laboratory of Female Reproductive Endocrine Related Diseases, Shanghai (China)

## Summary

**Objective:** The present authors describe the first case of a primary fallopian tube carcinoma (PFTC) clinically manifested as vaginal adenocarcinoma in a post-hysterectomy patient, and it reminds of the importance to perform bilateral salpingectomy during hysterectomy for a benign condition. **Case Report:** A 65-year-old woman with a history of hysterectomy presented with vaginal bleeding. Localized vaginal adenocarcinoma was diagnosed after the MRI, PET-CT scan, and biopsy. However, the final diagnosis of primary fallopian tube high grade serous adenocarcinoma was made after optimal laparoscopic cytoreductive surgery. She received chemotherapy with carboplatin and docetaxel given once every three weeks for six cycles. **Conclusion:** When the imaging results were indistinguishable, post-hysterectomy vaginal bleeding could be the only early symptom of PFTC, and bilateral salpingectomy is important to help prevent re-intervention for malignant or benign fallopian tube pathology. It still requires more research to preoperatively find a better diagnostic method for PFTC.

**Key words:** Primary fallopian tube carcinoma; Vaginal adenocarcinoma; Risk-reducing salpingectomy.

## Introduction

Primary fallopian tube carcinoma (PFTC) is recognized as a rare gynecologic malignancy and accounts for approximately 0.14%–1.8% of female genital malignancies [10]. Abnormal vaginal bleeding is a rare symptom for a post-hysterectomy patient. The existing cases of clinically occult primary fallopian tube carcinoma presenting as special metastasis manifestations are limited to small series and reports. In this article, the authors report an unusual case of primary fallopian tube carcinoma that clinically manifested as vaginal adenocarcinoma in a post-hysterectomy patient. In this case, preoperative imaging, including MRI and PET-CT, created a false impression of tumor location. The predominantly solid appearance of the tumor in the biopsy led to diagnostic confusion with the primary origin of the tumor. For this patient, when the imaging results were indistinguishable and manifested as a vaginal malignant tumor with a history of hysterectomy, the diagnosis of primary fallopian tube carcinoma was difficult to make. The authors performed laparoscopic surgery in an effort to discover a fallopian tube lesion by chance. Aggressive cytoreductive surgery and chemotherapy were given to maximize survival. The patient may have avoided fallopian tube cancer if risk-reducing salpingectomy was done in the setting of hysterectomy for her hysteromyoma ten years prior.

## Case Report

A 65-year-old female with a history of hysterectomy ten years ago for myoma presented with vaginal bleeding since September 2017. She was gravid 5, para 1, living child 1, with no significant personal or family history. Then, she was referred to a local hospital and received a vaginal apex biopsy with the result of vaginal adenocarcinoma. MRI revealed a mass in the left pelvic floor close to anterior rectum and adhering to the vaginal apex. The colonoscopy result was negative. For further treatment, she was referred to this hospital for pathological consultation, which confirmed vaginal apex high-grade adenocarcinoma (prone to serous carcinoma). The HPV result was negative. The immunohistochemical studies of the biopsied lesion showed positive staining for P53, P16, and PAX-8 and negative staining for CA125, WT-1, ER, and PR.

Transvaginal ultrasound identified a 37 × 29 × 32 mm solid mass in the upper left vagina close to the left ovary. Doppler evaluation of intra-tumoral blood vessels confirmed low resistance to flow. No ascites or other abnormalities were present (Figure 1). On admission, she had a 18F-Fluoro-2-deoxyglucose-PET-CT (18F-FDG-PET-CT). The imaging results revealed a vaginal malignant tumor with possible lymphatic metastasis. There was no intense FDG uptake in other parts of the body (Figure 2). The primary diagnosis included vaginal apex adenocarcinoma, post-hysterectomy, and post-thyroidectomy. During ex-

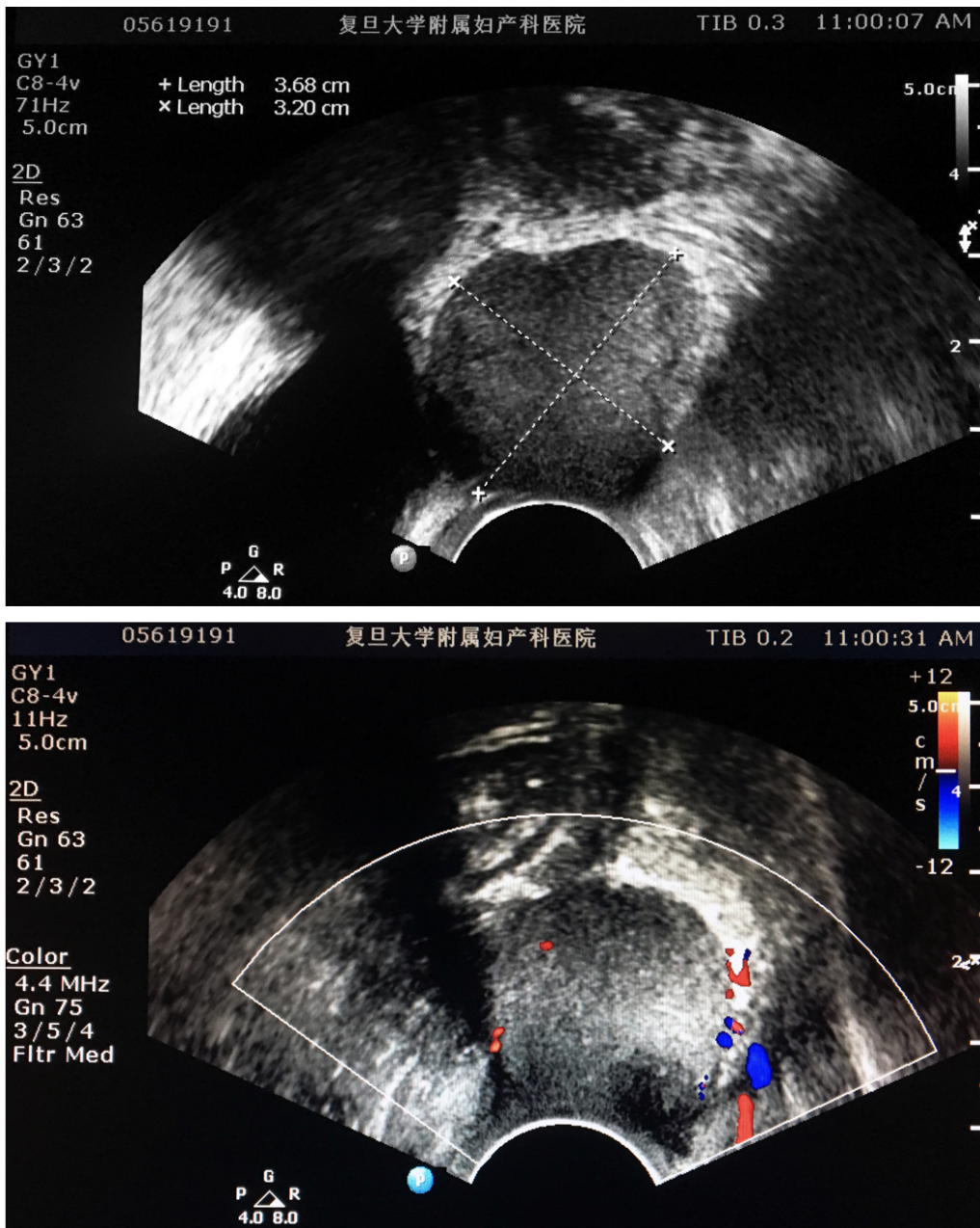


Figure 1. — Ultrasound manifestation of the patient. Transvaginal ultrasound identified a 37×29×32 mm, solid mass in the upper left vagina close to the left ovary. Doppler evaluation of in-tratumoral blood vessels confirmed a low resistance to flow. No ascites or other abnormalities were present.

ploratory laparoscopy, absence of the uterus was confirmed with a brittle neoplastic lesion on the left tubal fimbria with a severe adhesion between the left peritoneum and a hard vaginal lump. The size of left vaginal apex lesion was approximately 4 cm, and the boundaries were unclear. Scattered small lesions (1 mm–1 cm) could be seen on the peritoneal surface of the bladder, Douglas cul-de-sac, and mesentery. Other pelvic and abdominal organs were not involved macroscopically. Then, laparoscopic pelvic lesion resection, extensive tissue resection of the uterine left side, bilateral salpingo-oophorectomy, omentectomy,

pelvic lymph node dissection (PLND) and vaginal mass resection, and subtotal vaginectomy were performed. The tumor mass was completely excised with residual tumor size of 0 cm. The histopathological examination indicated that the bilateral ovaries and pelvic lymph nodes did not show primary or secondary neoplastic involvement. However, high-grade serous carcinoma (HGSC) of the left tube with vaginal wall, peritoneal mass, and omentum involved. Furthermore, there were free cancerous lesions within the lumen of the right fallopian tube. Immunohistochemically, the tumor cells were positively stained for P53, P16, and

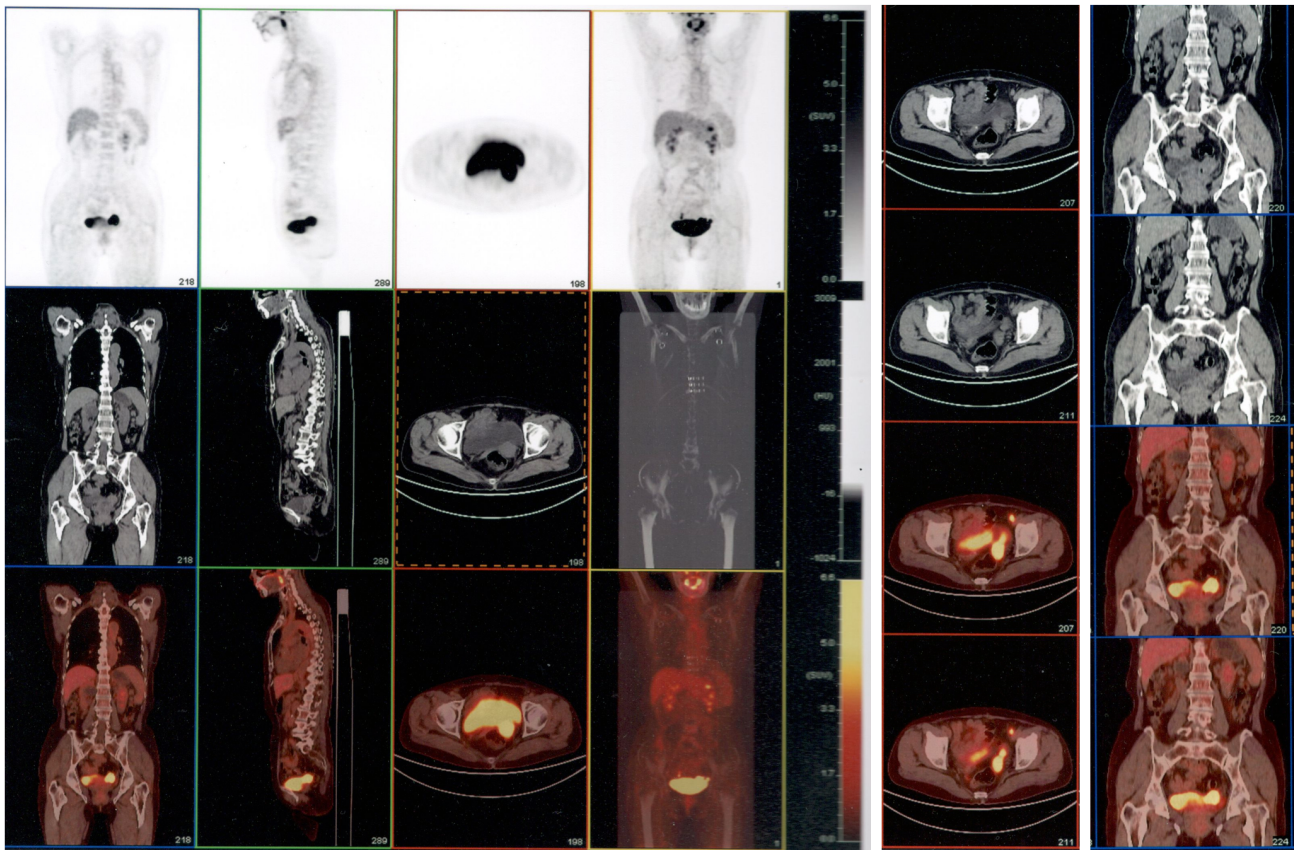


Figure 2. — 18F-FDG-PET-CT image demonstrates uptake in left pelvic floor and anterior rectum, which is adhering to the vaginal apex.

PAX-8, but negatively stained for CA-125, WT-1, ER, and PR (Table 1). Since these findings corresponded to a high-grade serous adenocarcinoma after surgery, the authors revised the diagnosis as high-grade serous adenocarcinoma of the fallopian tube at Stage IIIB with vaginal metastasis, post-hysterectomy, and post-thyroidectomy. The patient recovered well postoperatively and received carboplatin and docetaxel given once every three weeks for six cycles after operation based on the decision of a multidisciplinary team (MDT) at this hospital.

Table 1. — Summary of the immunohistochemical staining patterns.

Stain	Result (vaginal lesion)	Result (Postoperative pathology)
CA-125	Negative	Negative
P53	Positive	Positive
P16	Positive	Positive
WT-1	Negative	Negative
PAX-8	Subtotal Positive	Subtotal Positive
ER	Negative	Negative
PR	Negative	Negative

## Discussion

The etiology of PFTC is unknown. Hormonal, reproductive (nulliparous women), genetic factors (women with germline BRCA mutation), and a possible link between chronic uterine tube inflammation in a background of chronic pelvic inflammatory disease (PID) are thought to play a role in increasing the risk for PFTC [1, 2]. Serous carcinoma originating in the fallopian tubes are uniformly asymptomatic in their early stage, and it is the spread of the disease to other pelvic sites that produces the symptoms and signs most often observed [3]. PFTC disseminates by exfoliation of cells throughout the abdominal cavity, causing peritoneal carcinosis. Tumor spread may also occur by means of contiguous invasion, transluminal migration, hematogenous dissemination, and through lymphatic spread [4]. Through searching PubMed, the authors found some reported cases of occult fallopian tube carcinoma manifested as metastatic symptoms (Table 2). For this patient, abnormal vaginal bleeding after a history of total hysterectomy was first found. Preoperatively, the primary diagnosis was vaginal adenocarcinoma because of the vaginal apex biopsy and indistinguishable imaging results. In the face of biopsy of a metastatic vaginal lesion, appropriate broad immunohistochemical staining can be invaluable in pinpointing the primary tumor site in such patients. Imaging for suspected gynecologic malignancies includes

Table 2. — Literature review of cases of fallopian tube carcinoma manifested as metastatic symptoms.

Author (year)	Age	Cancer	Metastatic	manifestation	Preoperative diagnosis	Diagnostic method
Toyoda <i>et al.</i> , 2017 [5]	83	HGSC of the RFT	Metastatic tumor	diaphragm	Metastatic diaphragm tumor from the pelvic viscera	Surgical pathology
Atallah <i>et al.</i> , 2014 [6]	73	HGSC of the RFT	Ipsilateral metastatic carcinoma	axillary	Metastatic breast carcinoma	IHC profile of the enlarged axillary LN
Hiensch <i>et al.</i> , 2015 [7]	57	HGSC of the LFT	Malignant effusion	right pleural	Metastatic adenocarcinoma with uncertain primary site	Elevated CA-125, PET, IHC, diagnostic surgery
Asai-sato <i>et al.</i> , 2010 [8]	67	HGSC of the RFT fimbria	Rectovaginal mass	septum	Rectovaginal septum tumor	A transrectal biopsy, surgical pathology
Eken <i>et al.</i> , 2016 [9]	60	HGSC of the LFT	Palpable	left supraclavicular LN	Advanced-stage ovarian tumor	An excisional biopsy of the LN, IHC, imaging examination
Sakurai <i>et al.</i> , 2010 [10]	76	Adenocarcinoma of the RFT	Enlarged	supraclavicular LN	Metastatic adenocarcinoma with uncertain primary site	Biopsy of LN, IHC, exploratory laparotomy

HGSC: high-grade serous carcinoma; IHC: immunohistochemical; LN: lymph node; LFT: left fallopian tube; RFT: right fallopian tube.

ultrasound and CT and MRI scans of the abdomen. Several studies indicate that malignancies exhibit intense uptake on 18F-FDG-PET imaging. However, fallopian tube carcinoma is detected by imaging only 0–10% of the time [1]. Since the fallopian tube lumen and fimbria connect directly to the abdominal cavity, what was seen during surgery were extensive implanted lesions in the abdominal cavity.

In one of the largest studies evaluating the effectiveness of ovarian cancer screening, prophylactic bilateral salpingo-oophorectomy from age 35–40 for BRCA1 carriers and from age 40–45 for BRCA2 carriers is the only effective strategy, as it reduces the risk of ovarian cancer by 96% [11]. Risk-reducing salpingo-oophorectomy (RRSO) achieves an 80% reduction of ovarian and fallopian tube cancers among BRCA1/2 mutation carriers [12]. According to a non-randomized multicenter trial of GOG-0199, clinical occult cancer was detected among 2.6% of high-risk women undergoing RRSO with BRCA1/2 mutations [13]. The results of recent studies have suggested that high-grade serous ovarian cancer predominantly arises within the fallopian tubes. Therefore, prophylactic salpingectomy during benign gynecological surgery is now expected as an attempt to reduce the ovarian cancer incidence. In younger patients, prophylactic salpingectomy can be considered instead of adnexectomy. Taking into account the well-known benefits of ovarian conservation, prophylactic salpingectomy involved fallopian tube removal for primary prevention of epithelial carcinoma of the fallopian tubes, ovaries, and peritoneum in women undergoing pelvic surgery for another indication. Other advantages of this intervention are the avoidance of hydrosalpinx (which affects 30% of women after hysterectomy), the 7.8% lifetime risk of revision surgery, tubal infection, and benign and malignant fallopian tube tumors. Salpingectomy has no known physiological side effects, is safe and feasible, does not worsen surgical outcomes, does not significantly increase the op-

erative time and is not related to increased rates of intraoperative and postoperative complications or re-admission [14]. With the paradigm shift in assigning tubal origin to many high-grade serous ovarian carcinomas, new recommendations are also emerging for non-BRCA carrier women, which favor bilateral salpingectomy in the setting of hysterectomy for benign conditions or in place of tubal ligation, when irreversible contraception is desired [12]. As for this case, prophylactic bilateral tubal resection in the setting of hysterectomy for benign conditions would have to be a relatively lower risk choice for the patient.

In conclusion, the reported case indicated that post-hysterectomy vaginal bleeding could be the only early symptom of PFTC. Hysterectomy for benign conditions can be combined with bilateral salpingectomy to prevent re-intervention for malignant or benign fallopian tube pathology.

### Conflict of Interest

All authors declare that there is no conflict of interest.

### References

- [1] Pectasides D., Pectasides E., Economopoulos T.: "Fallopian tube carcinoma: a review". *Oncologist*, 2006, 11, 902.
- [2] Zardawi I.M.: "Primary fallopian tube carcinoma arising in the setting of chronic pelvic inflammatory disease". *Case Rep. Med.*, 2014, 645, 045.
- [3] Pardeshi S.P., Kulkarni M.M., Hishikar V.A.: "Primary fallopian tube carcinoma". *Eur. J. Obstet. Gynecol. Reprod. Biol.*, 2013, 169, 155.
- [4] Riska A., Leminen A.: "Updating on primary fallopian tube carcinoma". *Acta. Obstet. Gynecol. Scand.*, 2007, 86, 1419.
- [5] Toyoda T., Suzuki H., Nakajima T., Iwata T., Matsuoka A., Nishikimi K., Yonemori Y., *et al.*: "Successful diagnosis of an occult fallopian tube carcinoma detected from the diaphragm metastasis". *Gen. Thorac. Cardiovasc. Surg.*, 2018, 1, 4.
- [6] Atallah C., Altinel G., Fu L., Arseneau J., Omeroglu A.: "Axillary metastasis from an occult tubal serous carcinoma in a patient with ipsilateral breast carcinoma: a potential diagnostic pitfall". *Case Rep. Pathol.*, 2014, 2014, 534034.

- [7] Hiensch R., Meinhof K., Leytin A., Hagopian G., Szemraj E., Epelbaum O.: "Clinically occult primary fallopian tube carcinoma presenting as a malignant pleural effusion". *Clin. Respir J.*, 2017, *11*, 28.
- [8] Asaisato M., Hayashi H., Miyagi Y., Takahashi M., Shigeta H.: "An inconspicuous fallopian-tube carcinoma clinically manifested as a rectovaginal septal tumor: a pitfall for diagnosis and treatment". *Int. J. Clin. Oncol.*, 2011, *16*, 161.
- [9] Eken M.K., Kaygusuz E.I., Temizkan O., İlhan G., Çöğendez E., Karateke A.: "Occult serous carcinoma of fallopian tube presenting as supraclavicular lymphadenopathy". *Taiwan J. Obstet. Gynecol.*, 2016, *55*, 450.
- [10] Sakurai N., Tateoka K., Fukaya K., Terada T., Kubushiro K.: "Supraclavicular lymph node metastasis as the initial presentation of primary fallopian tube carcinoma". *Int. J. Clin. Oncol.*, 2010, *15*, 301.
- [11] Van der Velde N.M., Mourits M.J., Arts H.J., de Vries J., Leege B.K., Dijkhuis G., *et al.*: "Time to stop ovarian cancer screening in BRCA1/2 mutation carriers?". *Int. J. Cancer*, 2009, *124*, 919.
- [12] Kos Z., Broaddus R.R., Djordjevic B.: "Fallopian tube high-grade serous carcinoma with intramucosal spread and presenting as a malignancy on pap smear". *Int. J. Gynecol. Pathol.*, 2014, *33*, 443.
- [13] Sherman M.E., Piedmonte M., Mai P.L., Ioffe O.B., Ronnett B.M., Van Le L., *et al.*: "Pathologic findings at risk-reducing salpingo-oophorectomy: primary results from Gynecologic Oncology Group Trial GOG-0199". *J. Clin. Oncol.*, 2015, *32*, 3275.
- [14] Setúbal A.G., Alves J.S., Lavado O., Faria J.: "Mini-laparoscopy for removal (partial) of adnexae at the time of hysterectomy". *J. Minim. Invasive Gynecol.*, 2017, *24*, 201.

Corresponding Author:

Wei JIANG, M.D., Ph.D.

Department of Gynecology

Obstetrics and Gynecology Hospital of Fudan

University 419 Fangxie Road

Shanghai 200011 (China)

e-mail: jw52317@126.com