

Infertility and borderline malignant ovarian tumors: a case of successful pregnancy after fertility-preserving management of the disease

T. Armeanu^{1,2}, R. Maftei^{2,4}, G. Simionescu^{1,2,3}, D. Nicolaiciuc^{1,2,3}, N. Plopa^{1,2,3}, B. Doroftei^{1,2,3}

¹Clinical Hospital "Cuza Voda", Iasi. ²Origyn Fertility Center, Iasi
³Department of Mother and Child Medicine, ⁴Department of Morphostructural Sciences I,
University of Medicine and Pharmacy "Gr. T. Popa", Iasi (Romania)

Summary

For women of reproductive age diagnosed with gynaecologic cancers, techniques that aim to preserve the fertility are a growing area of research. Fertility-sparing surgical techniques should be an option for these patients, since removing the abnormal ovarian tissue may restore conceiving potential. The authors present the case of a 26-year-old woman diagnosed incidentally with a borderline ovarian tumor during an infertility check-up, who obtained a spontaneous pregnancy two months after laparoscopic unilateral adnexectomy, followed by IVF and embryo-banking.

Key words: Infertility; Borderline ovarian tumor; Fertility-sparing surgery; Pregnancy; Low malignant potential; IVF.

Introduction

Infertility, as defined by the World Health Organization, is the failure to achieve a clinical pregnancy after 12 months or more of regular unprotected sexual intercourse and it is an arising global issue, affecting 8% to 12% of reproductive-aged couples worldwide. Female infertility is responsible for one-third of the cases, the remaining two-thirds consisting of male or mixed infertility. Assessing the causes of female infertility is essential and there are two key points: the structure of the reproductive organs and the function of the hormonal hypothalamic-pituitary-gonadal axis [1, 2].

There are multiple causes of female infertility including structural factors, such as pelvic adhesions after chronic infection and pelvic inflammatory disease resulting in tubal obstruction, endometriosis, uterine fibroids, endometrial polyps or uterine congenital abnormalities or the Asherman syndrome [3]. Hormonal imbalances may cause anovulatory cycles and genetic factors may lead to premature ovarian failure [4].

Although not cited as one of the most frequent causes of female infertility, ovarian tumors are certainly worth looking into, as they may affect the reproductive outcome in more than one way: by decreasing the follicle count from the tissue surrounding the tumoral ovarian mass and the destructive potential of abnormally proliferative tissue [5].

The challenge when it comes to the management of young patients with tumoral ovarian masses, is the fine bal-

ance between correctly diagnosing and treating the disease, lowering the chances of recurrence, and at the same time, preserving the conceiving potential. Low malignant potential ovarian tumors are masses exhibiting an atypical epithelial proliferation greater than the one observed in the benign counterpart, but without stromal invasion, the incidence being approximately 1.8-4.8 per 100,000 women per year [6]. Firstly, this histological entity was described in 1929 as having a less aggressive behavior than invasive epithelial ovarian tumors, and since 1971 the term borderline tumor was agreed upon and is now widely-used. It is worth mentioning that there are three terms which are used to define this entity to lessen the confusion: borderline tumors, tumors of low malignant potential, and atypical proliferative tumors. They account for 10% to 20% of all ovarian epithelial tumors and one-third of the cases are diagnosed in women of less than 40 years of age, making them an area of interest and a great challenge when it comes to infertility, fertility-sparing surgery, and medical management of the disease in women of childbearing age [7].

Case Report

The authors present the case of a 26-year-old female with no medical history of gynecological surgical pathology and/or clinical symptoms other than primary infertility for three years and heavy menstrual flow.

Informed and written informed consent was obtained from the patient to present the information related with their medical

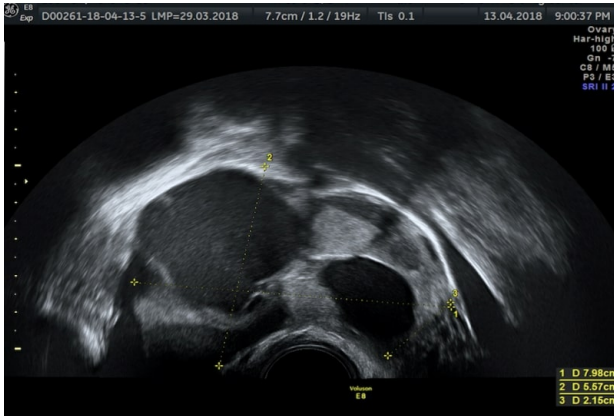

Figure 1. — Transvaginal pelvic ultrasound revealing an enlarged left ovary with an abnormal multiloculated mass with mixed cystic-solid content.

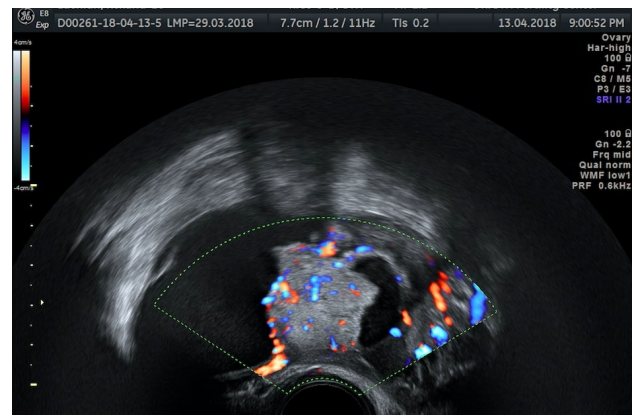


Figure 2. — Actual Doppler signal flow.

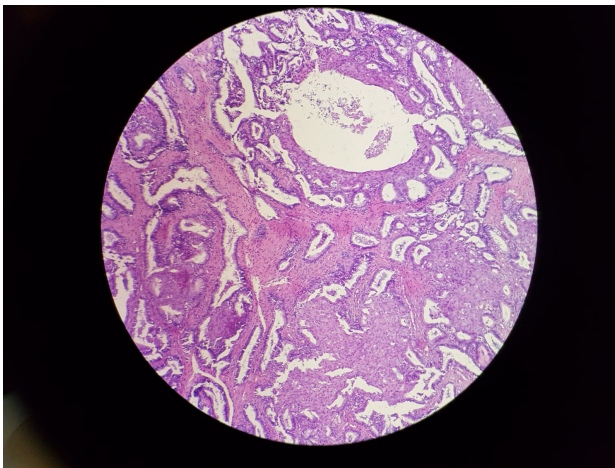


Figure 3. — Tumor proliferation of endometrial glands with mild cytonuclear atypia, squamous metaplasia, and fibrous stroma.

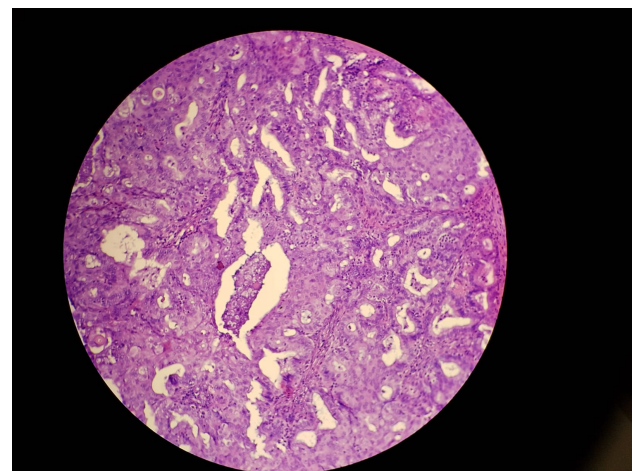


Figure 4. — Tumor proliferation of endometrial glands with squamous metaplasia and fibrous stroma (HE, $\times 10$).

records. The study protocol and the publication of the manuscript were approved by the Ethical Committee at the Origyn Fertility Center, where the investigations took place.

During the first fertility checkup, the patient was submitted to a medical interview, a clinical exam, and a transvaginal ultrasound. According to the anamnesis, the patient was a non-smoker, with no significant comorbidities or relevant family-associated diseases, regular periods, no history of past pelvic infections and normal results at the annual Pap smears. The patient did not complain of abdominal or pelvic pain and the bimanual palpation exam showed no tenderness at the moment of the exam. The transvaginal ultrasound revealed three intrauterine hyperechoic endometrial findings suggestive of polyps, the larger being 12 mm in size. The uterus was normal in size and the structure of myometrium was homogenous. In the rectouterine pouch of Douglas, no signs of pelvic inflammatory disease or free fluid were observed. Furthermore, the cervix was examined, and both the length and structure were normal. Upon examination of the adnexae and the ovaries, the right adnexa showed no abnormalities. The right ovary, which was $37 \times 21 \times 17$ mm in size presented four antral follicles, without any signs of cystic masses or adhesions. In con-

trast, the left ovary was significantly larger in size, $80 \times 55 \times 21$ mm with a cystic appearance (Figure 1), intracystic vegetation, and increased color flow Doppler signal (Figure 2). The patient was advised to undergo a series of blood analysis and a MRI scan. At the follow-up exam, the blood tests revealed elevated serum levels of CA 19-9 (79.76 U/ml reference value less than 27), ROMA score 33.36 % chance of malignancy (reference value less than 11% for the age group), and an AMH level of 1.24 ng/ml. The first MRI scan describes the cystic lesion on the left ovary with mixed content both fluid and solid sized 55×58 mm to be suggestive of endometriod or haemorrhagic cyst, and no other pathological findings other than a small quantity of fluid in the Douglas pouch (normal uterus and cervix, normal right adnexa) and no sign of secondary lesions in the thorax, abdomen or ischiorectal fossae.

Taking into consideration all the aforementioned clinical and paraclinical data, the patient underwent a surgical procedure, the medical team opting for a less invasive laparoscopic approach. At the intraoperative inspection of the peritoneal cavity, the left ovary was visibly enlarged, with a large cystic mass having superficial cortex vessels visible on its surface, adherent to the left fallopian tube, while the left side of the uterus presented velamentous adhesions. No macroscopic lesions were found on the peritoneum or

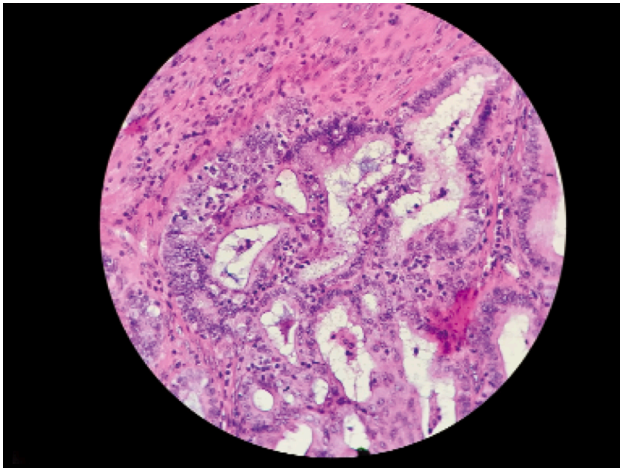


Figure 5. — Endometroid intraepithelial neoplasia (HE, ×20).

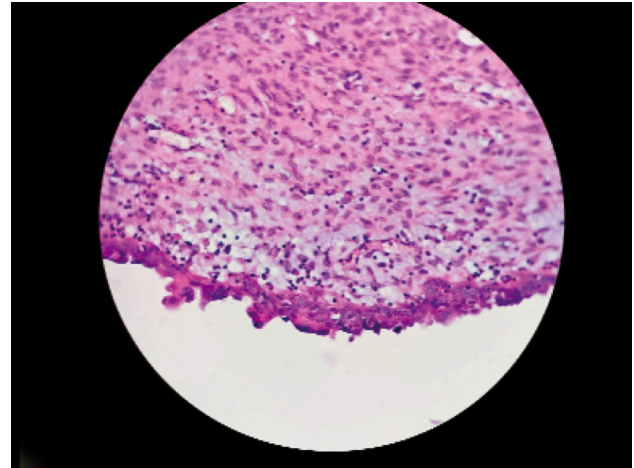


Figure 6. — Endometroid intraepithelial neoplasia (HE, ×40).

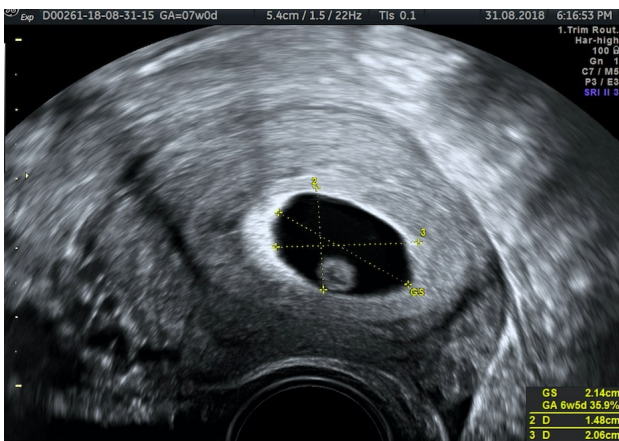


Figure 7. — Transvaginal ultrasound at seven weeks of amenorrhea showing an ongoing early intrauterine pregnancy.

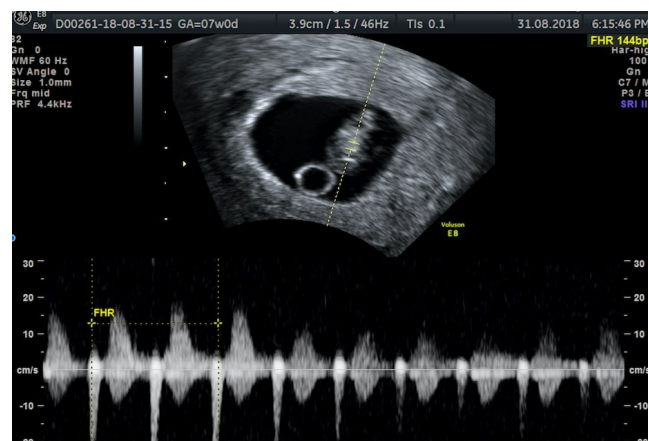


Figure 8. — Actual cardiac activity of the embryo.

liver. The mass was incised and a small tissue sample was sent to extemporaneous exam during surgery.

The preliminary pathology exam showed endometrioid borderline tumor with focal intraepithelial neoplasia. Left adnexectomy was performed with the extraction of the ovary and tube in an endobag, to prevent intraperitoneal malignant cell dissemination. Furthermore, peritoneal tissue biopsy and peritoneal washing cytology was performed to further exclude malignant cell contamination. Additionally, uterine dilation and curettage was also performed and the tissue samples were sent for cell atyp screening, to exclude endometrial malignancy. There were no intraoperative complications or haemorrhage and the vital signs remained stable throughout entire intervention, with normal postoperative standard biochemical analysis.

The postoperative evolution of the patient was favorable under antithrombotic, antibiotic prophylaxis and analgic treatment, subsequently being discharged from the hospital two days later. The final pathology report showed no abnormal cells with signs of atypical mitotic activity in the peritoneal washing sample, in the peritoneal tissue samples, and the endometrial tissue harvested during the uterine curettage.

The final histologic tissue pathology report of the excised sur-

gical specimen was conclusive and in accordance with the extemporaneous report. The examined sections captured the following aspects: papillary proliferation composed of epithelial elements arranged in simple or branching tubular glands, with mild to moderate cytonuclear atypia, low mitotic rate, and squamous morules, embedded in a sparse fibromatous stroma. Microscopic foci of intraepithelial carcinoma are present (atypical hyperplasia with rare atypical mitotic figures), composed of irregular crowded glands disposed in a cribriform pattern, embedded in dense fibrous stroma, with dystrophic calcifications, but no inflammatory response. No vascular invasion, nor tumoral necrosis were identified in the examined area. The fragmented biopsy did not enable the assessment of the integrity of the capsule (Figures 3-6). The patient was further referred to an oncological committee who established that the tumor was a pT1aNxMxG1 and did not require any other medical or surgical interventions other than close follow up at six-month intervals after normal postoperative CT scan showed no remaining or secondary lesions and the ROMA score had dropped to 4.75% risk of malignancy.

Taking into consideration that the ovarian mass was an incidental finding during an infertility check-up and that the surgical

management of the case preserved the remaining right ovary and fallopian tube, the patient requested to undergo further tests to assess her chances of conceiving. Due to the removal of the left ovary, the serum level of the AMH decreased from 1.24 ng/ml prior to surgery to 0.74 ng/ml afterwards. During fertility investigations, a routine sperm analysis was also performed and the exam results were normozoospermia. In the light of the decreased ovarian reserve, the patient decided to undergo an IVF procedure. At the beginning of the following cycle, controlled ovarian stimulation was commenced, using a short antagonist protocol by administering 200 units of follitropin beta per day, for a period of nine days.

Oocyte maturation was triggered by the subcutaneously administration of chorionic gonadotropin alpha in a dosage of 250 micrograms, 36 hours prior oocyte retrieval. Nine follicles were punctured through ovum pick up method and a total number of nine mature oocytes were retrieved. Subsequently, intracytoplasmic sperm injection (ICSI) was performed, resulting in four fertilized oocytes (fertilization rate 44.4%). The embryos were culture in time lapse system (embryoscope), until blastocyte stage (ExB1/1, HB1/2, ExB1/1, ExB2/1) and then vitrified with the purpose of performing a frozen-thawed single embryo transfer afterwards.

Next month, the patient complained of a menstrual delay, therefore a hCG analysis was recommended. The result of the first determination was 2,081 mUI/ml and the result of the second determination, performed 36 hours later, was 3,968 mUI/ml, thereby a spontaneous pregnancy was confirmed. Transvaginal ultrasound at seven weeks showed a regularly shaped intrauterine gestational sac with a crown rump length of 9 mm, normal yolk sack size, and shape and positive embryo cardiac activity of 144 beats per minute. At the moment the patient was ten weeks pregnant with no obstetrical complications.

Discussions

The aim of this article was to present the case of a 26-year-old woman diagnosed incidentally with a borderline ovarian tumor during an infertility check-up who obtained a spontaneous pregnancy two months after laparoscopic unilateral adnexaectomy. The prognosis for patients with borderline ovarian tumors seems to be quite favourable, with survival rates at five years for early-stage disease of approximately 98% [8].

Regarding the causes and the risk factors associated with borderline ovarian tumors, although there is no certain and evident single cause established, they do seem to originate from the surface epithelium of the ovary [9] and nulliparous women are at greater risk of developing them compared to parous ones [10]. Based on histological findings, borderline ovarian tumors are classified as serous (50%), mucinous (45%), endometrioid, clear cell or Brenner tumors [11].

There has been great controversy regarding the safety of conservative versus radical surgery in these type of tumors diagnosed at an early stage. Recurrence rates seem to be slightly higher in patients undergoing fertility-sparing surgery than in those undergoing radical surgery [12, 13], however the survival rate seems unaltered since recurrent lesions seem to be also of borderline nature and completely

curable through surgical resection. For first stage disease, conservative surgery consists of unilateral salpingo-oophorectomy or even cystectomy for young women willing to preserve their fertility, while bilateral salpingo-oophorectomy or even total hysterectomy with bilateral adnexaectomy may be considered for women of menopausal age, who already conceive or do not intend to preserve their fertility.

The laparoscopic approach is safe, feasible, well-tolerated, and cost effective for both radical and conservative management. Notwithstanding the benefits of this type of interventions, studies [14, 15] that highlighted the negative impact on the ovarian reserve, as measured by serum anti-Müllerian hormone levels (AMH) A study carried out by Doroftei *et al.* [16] on 5,069 Romanian women showed a mathematical relation between age and ovarian reserve, emphasizing once more on the usefulness of this biomarker in making clinical decisions in ART. In the present case, the patient's AMH decreased significantly from 1.24 ng/ml prior to surgery to 0.74 ng/ml postoperative, thereby the authors considered that a longer waiting period between surgery and the start of an IVF cycle may have a negative impact on fertility due to deterioration of the ovarian reserve. Furthermore, studies conducted by Someglia *et al.* [17] and Ho *et al.* [18] showed that a significantly lower number oocytes were retrieved from the operated ovaries compared to the contralateral ovary during IVF treatment.

Since infertility is frequently observed in patients with borderline ovarian tumors [17, 18] and conservative treatment is applied, the question that arises is if ovarian stimulation or IVF should be proposed to these patients? Some studies have linked ovarian hyper stimulation to a higher risk of onset of borderline ovarian tumors or even ovarian cancer, however the link remains unclear. Results so far suggest that infertility drugs and assisted reproduction techniques may be safely used in patients who experience infertility after conservative treatment of an early-stage gynaecological cancer [21, 22], however particular monitoring and a joint cooperation between oncologists and specialists in assisted reproduction is essential [23].

The authors may conclude that the advancements from the field of human assisted reproduction molecular biology and oncologic surgery brought new opportunities to women of childbearing age and fertility-preserving management should be highly considered for this category of patients.

References

- [1] Practice Committee of the American Society for Reproductive Medicine: "Testing and interpreting measures of ovarian reserve: a committee opinion". *Fertil. Steril.*, 2015, 103, e9.
- [2] Eniola O.W., Adetola A.A., Abayomi B.T.: "A review of Female Infertility; important etiological factors and management". *J. Microbiol. Biotech. Res.*, 2012, 2, 379.
- [3] Dean D.D., Agarwal S., Tripathi P.: "Connecting links between genetic factors defining ovarian reserve and recurrent miscarriages".

- J. Assist. Reprod. Genet.*, 2018, 35, 2121.
- [4] Abrao M.S., Muzii L., Marana R.: "Management of Infertility Today: Proceedings of a Workshop sponsored by the Pontifical Academy for Life". *Inter. J. Obstet. Gynaecol.*, 2013, 123, S18.
- [5] Morice P., Denschlag D., Romolakis A., Reed N., Schneider A., Kesic V., Colombo N.: "Recommendations of the fertility task force of the European Society of Gynaecologic Oncology about the conservative management of ovarian malignant tumors". *Int. J. Gynecol. Cancer*, 2011, 21, 951.
- [6] Tavassoli F.A., Devilee P.: "World Health Organisation classification of tumors. Pathology and genetics". *Tumors of the breast and female genital organs*. Lyon: IARC Press, 2003
- [7] Morice P., Camatte S., El Hassan J., Lhomme AC., Duvillard P., Castaigne D.: "Clinical outcomes and fertility results after conservative treatment for ovarian borderline tumor". *Fertil. Steril.*, 2001, 75, 92.
- [8] Gershenson D.M.: "Clinical management of potential tumors of low malignancy". *Clin. Obstet. Gynecol.*, 2002, 16, 513.
- [9] Harris R., Whittemore A., Itnyre J., Collaborative Ovarian Cancer Group: "Characteristics relating to ovarian risk: a collaborative analysis of 12 US case-control studies. Epithelial tumors of low malignant potential in white women". *Am. J. Epidemiol.*, 1992, 136, 1204.
- [10] Riman T., Dickman P.W., Nilsson S., Correia N., Nordlinder H., Magnusson C.M.: "Risk factors for epithelial borderline ovarian tumors: results of a Swedish case-control study". *Gynecol. Oncol.*, 2001, 83, 575.
- [11] Winter W.E. 3rd., Kucera P.R., Rodgers W., McBroom J.W., Olsen C., Maxwell G.L.: "Surgical staging in patients with ovarian tumors of low malignant potential". *Obstet. Gynecol.*, 2002, 25, 2928.
- [12] Zanetta G., Rota S., Chiari S., Bonari C., Bratina G., Mangioni C.: "Behavior of borderline tumors with particular interest to persistence, recurrence, and progression to invasive carcinoma: a prospective study". *J. Clin. Oncol.*, 2001, 19, 2658.
- [13] Seracchioli R., Venturoli S., Colombo F.M., Govoni F., Missiroli S., Bagnoli A.: "Fertility and tumor recurrence rate after conservative laparoscopic management of young women with early-stage borderline ovarian tumors". *Fertil. Steril.*, 2001, 76, 999.
- [14] Chang H.J., Han S.H., Lee L.R.: "Impact of laparoscopic cystectomy on ovarian reserve: serial changes of serum anti-Müllerian hormone levels". *Fertil. Steril.*, 2010, 94, 343.
- [15] Iwase A., Hirokawa W., Goto M.: "Serum anti-Müllerian hormone level is a useful marker for evaluating the impact of laparoscopic cystectomy on ovarian reserve". *Fertil. Steril.*, 2010, 94, 2846.
- [16] Doroftei B., Mambet C., Zlei M.: "It's Never over until It's over: How Can Age and Ovarian Reserve Be Mathematically Bound through the Measurement of Serum AMH—A Study of 5069 Romanian Women". *PLoS One*, 2015, 10, e0125216.
- [17] Somigliana E., Ragni G., Benedetti F.: "Does laparoscopic excision of endometriotic ovarian cysts significantly affect ovarian reserve? Insights from IVF cycles". *Hum. Reprod.*, 2003, 18, 2450.
- [18] Ho H.Y., Lee R.K.K., Hwu Y.M., Lin M.H., Su J.T., Tsai Y.C.: "Poor Response of Ovaries with Endometrioma Previously Treated with Cystectomy to Controlled Ovarian Hyperstimulation". *J. Assist. Reprod. Genet.*, 2002, 19, 507.
- [19] Fauvet R., Poncelet C., Boccara J., Descamps P., Fondrinier E., Darai E.: "Fertility after conservative treatment of borderline ovarian tumors: a french multicenter study". *Fertil. Steril.*, 2005, 83, 284.
- [20] Morris R.T., Gershenson D.M., Silva E.G., Fallen M., Morris M., Wharton J.T.: "Outcome and reproductive function after conservative surgery for borderline ovarian tumors". *Obstet. Gynecol.*, 2000, 95, 541.
- [21] Nicolaiciu D., Simionescu G., Doroftei B., Anton SC., Bolota M., Ioanid N., et al.: "Abdominal radical trachelectomy as a method of preserving fertility in patients with cervical cancer". *Med. Rev. Chir.*, 2018, 122, 96.
- [22] Kardakis S.: "Fertility-preserving surgery in patients with early stage cervical carcinoma". *ISRN Oncol.*, 2012, 2012, 817065..
- [23] Mitildzans A., Bazarova J., Brikune J., Gelderina E., Isajevs S., Lakutins J., et al.: "First Successful Full Term Pregnancy Outcome in Latvia Following a Radical Trachelectomy for the Patient with a Combined Pathology of a Cervical Cancer and Severe Subfertility". *Acta Chir Latviensis*, 2016, 16, 44.

Corresponding Author:
 R. MAFTEI, M.D.
 Origyn Fertility Center Iasi
 Department of Morphostructural Sciences I,
 University of Medicine and Pharmacy "Gr. T. Popa"
 Iasi (Romania)
 e-mail: ginecologie@gmail.com