

Laparoscopic ureteral reconstruction in gynaecological recurrent cancer surgeries: an initial case series study

Yuji Tanaka¹, Yusuke Shimizu¹, Ai Ikki¹, Kota Okamoto¹, Atsushi Fusegi¹, Makoto Nakabayashi¹, Makiko Omi¹, Tomoko Kurita¹, Terumi Tanigawa¹, Yoichi Aoki¹, Sachiko Netsu¹, Mayu Yunokawa¹, Hidetaka Nomura¹, Maki Matoda¹, Sanshiro Okamoto¹, Kohei Omatsu¹, Hiroyuki Kanao¹

¹Department of Gynecologic Oncology, Cancer Institute Hospital of JFCR, Koutouku, 135-8550, Tokyo, Japan

Summary

In combined resection of the bladder and ureter during laparoscopic surgery for gynaecological recurrent cancer, some cases require laparoscopic ureteral reconstruction techniques. In the open surgery approach, it has been reported that gynaecological advanced or recurrent tumour surgeries solely conducted by a gynaecologic group, with combined resection of multiple organs, improves the prognosis. However, to the best of our knowledge, in the minimally invasive surgery approach, there are no reported case series in the field of gynaecological recurrent tumour surgery conducted by only a gynaecologic group, with combined resection of the bladder and ureter. Therefore, we conducted this pilot study to describe the feasibility of laparoscopic gynaecologic recurrent malignant tumour surgery involving ureteral reconstruction. We retrospectively searched our patient database for women with gynaecological cancer who underwent laparoscopic ureteral reconstruction techniques in gynaecological recurrent cancer surgeries. Nine patients underwent laparoscopic ureteral reconstruction for long-segment ureteral defects in gynaecologic surgeries. In all cases, R0 surgical resection were successfully performed. The ureteral defect lengths ranged from 3.5-10 cm (median, 4 cm). The Boari flap was necessary in one of the eight cases with a ureteral defect of less than 8 cm. The ureteral defect was less than 12 cm in all cases, but substitution was required in three cases. In all cases except one, no urinary complications occurred. In conclusion, it is feasible for a gynaecologist to perform laparoscopic ureteral reconstruction combined resection of the bladder and ureter during laparoscopic surgery for gynaecological recurrent cancer.

Key words: Ureteral reconstruction; Boari flap; Ileal substitution; Laparoscopy; Gynaecology.

Introduction

In recurrent gynaecological tumours, R0 resection involving combined resection of the bladder and ureter often plays an important role. However, such surgery has some unsolved problems.

Firstly, clarification is required regarding who should operate on patients with recurrent or advanced gynaecological tumour. In gynaecological surgery, some recurrent or advanced tumour resection cases require ureteral or digestive tract reconstruction techniques. In those cases, surgery can be performed by either a gynaecologist alone or with a general surgeon or urologist. Several studies have reported that the surgery should be performed by gynaecologic oncologists specialised in treating gynaecologic cancer who recognise the specific behaviour of the disease [1-6]. Notably, in these reports, surgery was performed by an open surgery approach, and there are no reports of gynaecological recurrent tumour surgery conducted by only a gynaecologic group, with combined resection of the bladder and ureter, via a minimally invasive approach.

Secondly, the optimal surgical approach (open surgery approach vs. minimally invasive surgery approach) for recurrent cancer resection also requires elucidation. Because laparoscopy optimises visualisation and provides meticu-

lous dissection, laparoscopic or robotic surgery can be advantageous over open surgery for resection of such complicated procedures [7, 8]. In ureteral reconstruction, a highly invasive reconstruction is required based on the distance of the urinary tract defect in the following order: ureterocystostomy, psoas hitch, Boari flap with psoas hitch and ileal substitution. In the field of urology, Fugita *et al.* (2001) [9] and Gill *et al.* (2000) [10] first successfully performed laparoscopic Boari flap and laparoscopic ileal substitution in 2001 and 2000, respectively. Laparoscopic ureteral reconstruction has been reported to be as safe as the open technique and superior in terms of postoperative recovery in urologic surgeries [11, 12]. However, there are no reports of laparoscopic urethral reconstruction by gynaecologists other than one video case report of our team [13].

Therefore, we conducted this pilot study to describe the feasibility of laparoscopic gynaecologic recurrent malignant tumour surgery involving ureteral reconstruction.

Materials and Methods

Patient population

We retrospectively searched our patient database for women with gynaecological cancer who underwent laparoscopic ureteral reconstruction techniques in gynaecological

recurrent cancer surgeries at the Cancer Institute Hospital of JFCR from January 1, 2015 to December 31, 2019.

In this study, laparoscopic ureteral reconstruction included laparoscopic ureteral reconstruction by ureterocystostomy, psoas hitch, Boari flap with psoas hitch and ileal substitution. Patients were excluded if they had denied access to their medical records for research purposes. Approval from the review board of Cancer Institute Hospital of JFCR was obtained for this study.

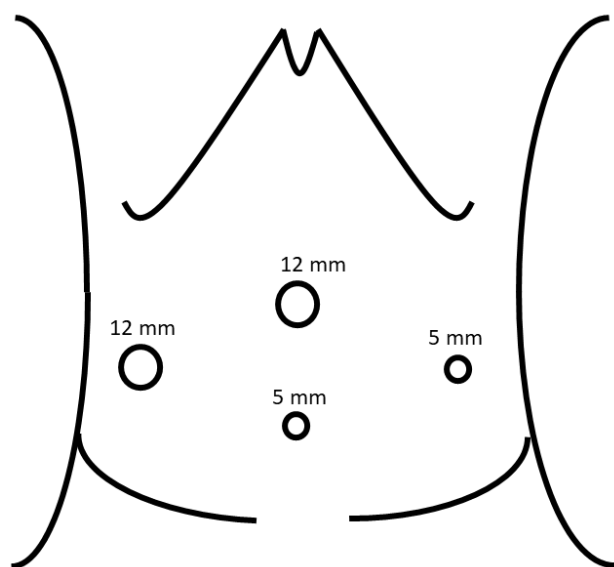


Figure 1. — Port position of laparoscopy.

Surgical procedures

All procedures were performed under general anaesthesia. A transperitoneal approach was employed in all cases, and all procedures were performed by a single gynaecologist with extensive experience in ureteral reconstruction by the open surgery approach. The represented port position is shown in Figure 1. A 12 mm trocar for the 0° lens laparoscope was placed at the umbilicus, and two 5 mm trocars and one 12 mm trocar were placed in the lower abdomen. Our surgical technique of laparoscopic ureteral reconstruction using the Boari flap with psoas hitch and ileal substitution was previously described in our video report [13]. The ureter was identified and transected at the required position. Using various techniques, recurrent tumours were resected laparoscopically. When the surgeon assessed it as necessary, the external iliac vessel, internal iliac vessel, vagina, rectum, small intestine, and/or bladder were resected en bloc with the recurrent tumour. The surgical margin was checked by an intraoperative frozen section analysis, and a negative result was confirmed before reconstruction.

As the first step in urinary reconstruction, the bladder was filled with normal saline and mobilised by exposing the Retzuis and paravesical spaces. The bladder was repaired in cases where partial cystectomy was performed.

Based on the ureteral defect length, ureterocystostomy, psoas hitch, Boari flap with psoas hitch and ileal substitution were performed as ureteral reconstruction techniques.

Laparoscopic ureteroneocystostomy technique with and without psoas hitch

The ureteral tip was spatulated by a posterior incision. A detrusor myotomy was performed until the bluish bladder mucosa was delineated to create a tunnel with a length about four or five times the ureter size. An optimal bladder mucosa window was then created. Subsequently, the ureter tip mucosa was fixed to the bladder mucosa with interrupted vicryl 4.0 sutures. The detrusor muscle was reapproximated with interrupted vicryl 3.0 sutures. This technique is called extravescical ureteroneocystostomy. If the tension of the ureter was strong, the psoas hitch technique was also used. The fixation of the bladder on the psoas tendon was performed with interrupted vicryl 1.0 sutures. During the above procedure, a Double J 6 Fr ureteral stent was inserted, the placement of which was confirmed by an X-ray examination.

Laparoscopic Boari flap with psoas hitch technique

A Boari flap of about 3–4 cm width was created with its base at the posterior lateral bladder wall above the original ureteric orifice and its tip at the contralateral anterior bladder wall. According to the result of the Übelhör modification method, a wide rhombic flap was created with a broad basis, which can be rotated to the psoas muscle [14]. To release the tension of the vesicoureteral junction, the psoas hitch technique was also used. The fixation of the bladder on the psoas tendon was performed with interrupted vicryl 1.0 sutures. The ureter tip was spatulated by a posterior incision. A submucosal tunnel was created starting at the medial rim of the hitched bladder. To create a nonrefluxing anastomosis, the ureter was pulled through the cystostomy site, and an interrupted vicryl 4.0 suture was used to approximate the spatulated edges of the ureter tip to the bladder mucosa. This technique is called intravesical ureteroneocystostomy. The bladder was closed in two layers with vicryl 3.0 sutures. The tunnel was created using interrupted sutures, which were imbricated over the ureter, resulting in a non-refluxing mechanism. During the above procedure, a Double J 6 Fr ureteral stent was inserted, the placement of which was confirmed by an X-ray examination (Figure 2).

Laparoscopic intracorporeal ileal substitution technique

Ureteral reconstruction was performed laparoscopically. The ileum was pulled down to the pelvis to assess the adequate length for anastomosis. The interposed bowel segment should be anastomosed when possible to the renal pelvis proximally and to the bladder distally. The following procedure was performed as a minilaparotomy. A required segment of the ileum was harvested extracorporeally using anastomosis staplers. The bowel continuity was re-established by performing functional end-to-end anastomosis.

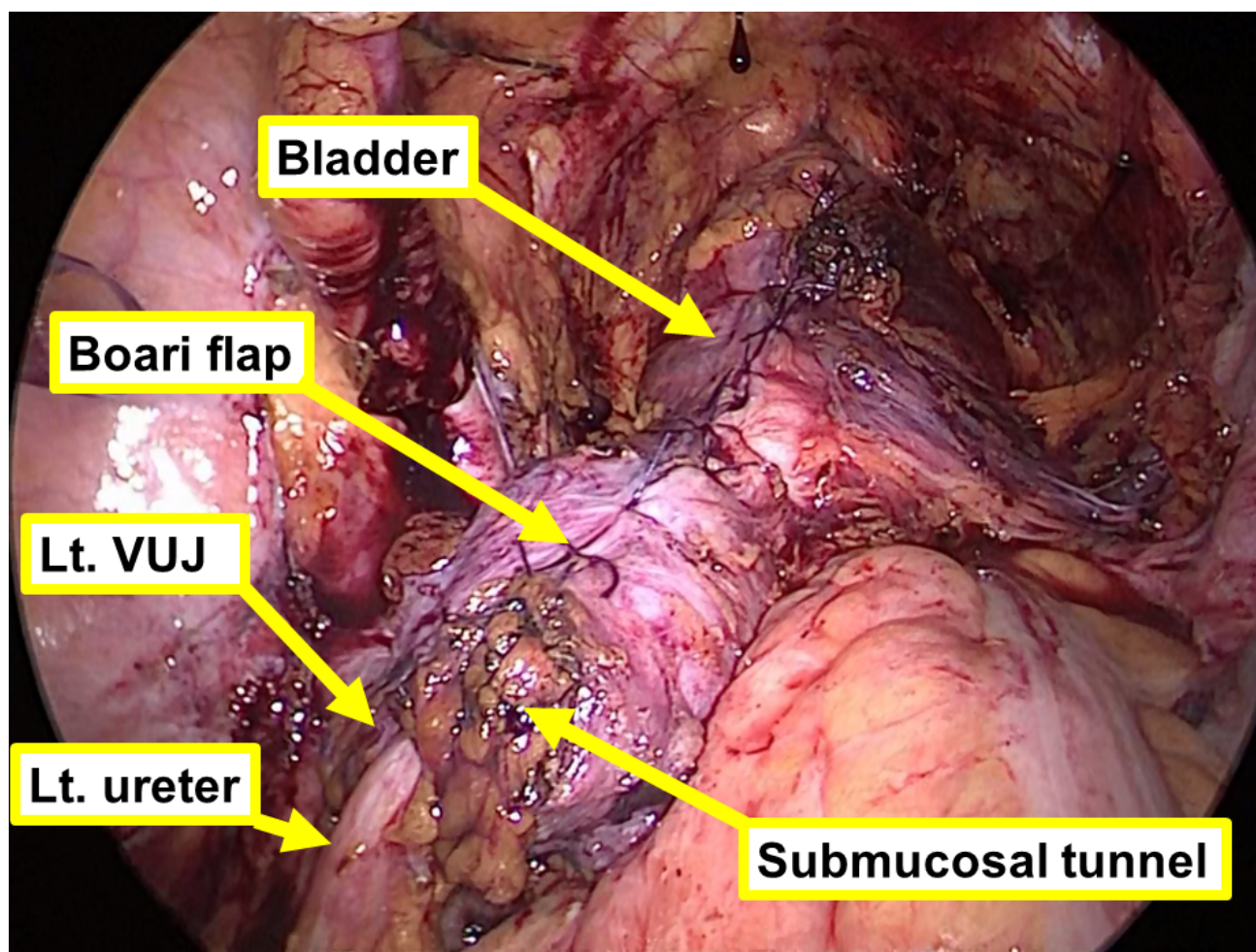


Figure 2. — Laparoscopic findings of psoas hitch and Boari flap. VUJ, vesicoureteral junction.

sis using a surgical stapler. The incision was then closed to restore the pneumoperitoneum. Laparoscopic surgery was again performed. The ureter tip was spatulated by a posterior incision. An incision was made in the proximal and antimesenteric positions of the harvested ileum segment for ureter-ileum anastomosis. The ureter-interpositional ileum was anastomosed, creating a watertight seal using intracorporeal freehand vicryl 4.0 suturing. An incision was made in the bladder for ileum-bladder anastomosis. The interpositional ileal-bladder flap was anastomosed, creating a watertight seal, using intracorporeal freehand vicryl 4.0 suturing. During the above procedure, the ileum segment was copiously irrigated, and a Double J 6 Fr ureteral stent was inserted, the placement of which was confirmed by an X-ray examination (Figure 3).

Postoperative care

The drains were removed when the creatinine level of the fluid was equivalent to the serum creatinine level. A Foley catheter was left for 7 days postoperatively before discharge. Retrograde cystography was performed at the time of Foley catheter removal. The ureteral stent was removed 2 or 3 months postoperatively when there was no leakage of

urine into the abdominal cavity and no hydronephrosis on contrast computed tomography (CT). A detailed history and clinical examination were performed in all cases. Postoperative contrast CT was performed at least every six months in all cases for detection of complications, such as late recurrence of stenosis and recurrence of tumour.

Analysis

The database was reviewed to include data on the patients' characteristics, disease aetiology, perioperative data, complications, and follow-up. The Clavien-Dindo scale was used to evaluate postoperative complications, and scores of IIIa or higher were defined as major complications.

Results

A total of nine cases underwent laparoscopic ureteral reconstruction due to combined resection of the bladder and ureter in laparoscopic gynaecological surgery. In all cases, the surgical indications were recurrent gynaecological tumours. In three of the nine cases, radiotherapy was performed prior to laparoscopic resection of the tumour. Four cases had comorbidities, such as hypertension and di-

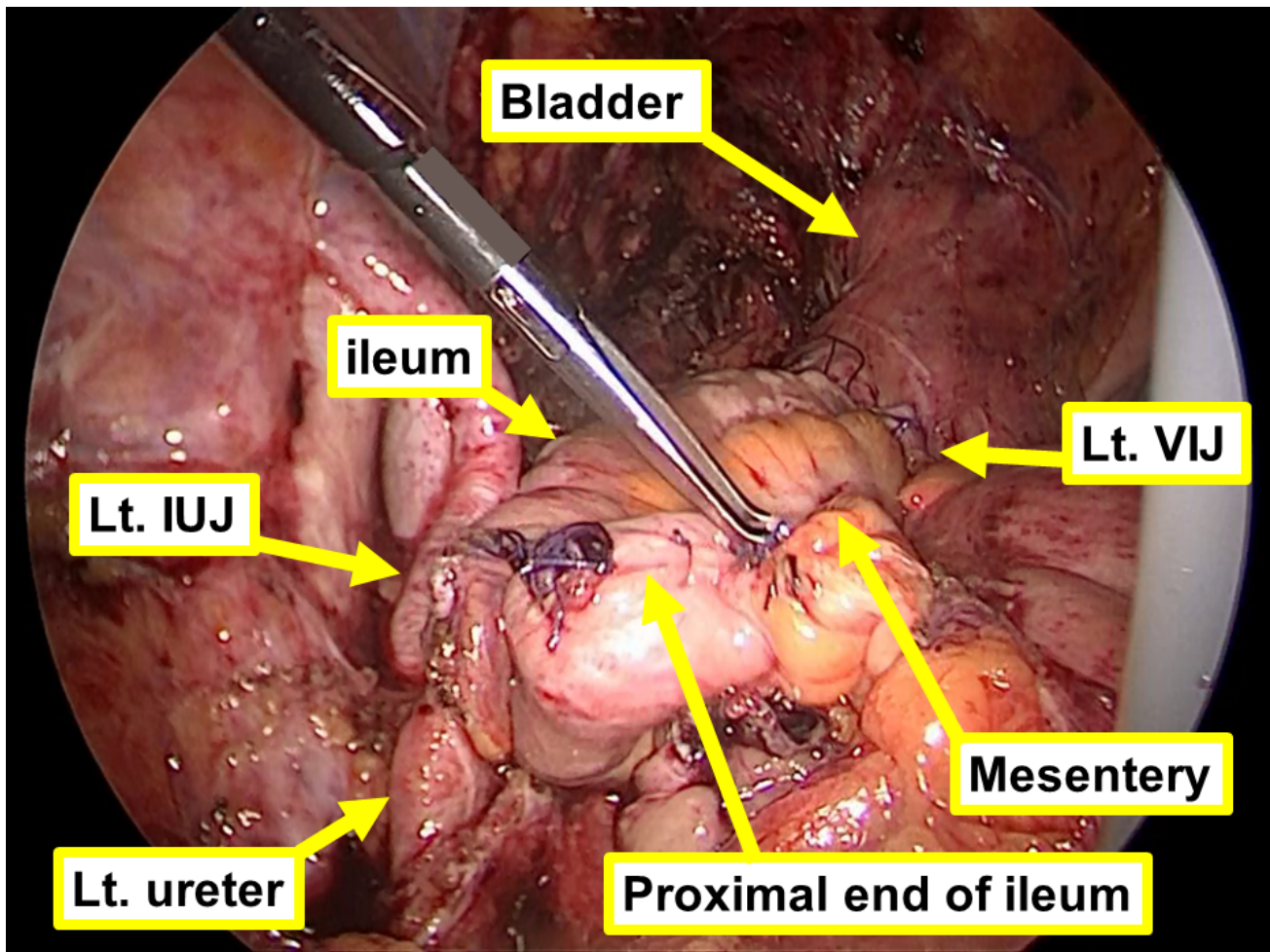


Figure 3. — Laparoscopic findings of substitution. VIJ, vesicoileal junction; IUJ, ileoureteral junction.

abetes mellitus. In addition, CT showed preoperative hydronephrosis in four cases (Table 1).

Laparoscopic surgery was performed in all cases, and no case was converted to laparotomy. Tumours were completely resected in all cases using various laparoscopic procedures. Partial cystectomy was performed in eight of the nine cases. The ureteral defect length was 3.5 cm to 10 cm (median, 4 cm). A psoas hitch, Boari flap, or ileal substitution was necessary in five of the six cases with a ureteral defect of less than 5 cm. A psoas hitch and a Boari flap or ileal substitution were necessary in seven of the eight cases with a ureteral defect of less than 8 cm. The ureteral defect was less than 12 cm in all cases, but ileal interposition was required in three cases. In all cases except one, the ureteral stent was removed within 3 months, and no hydronephrosis was observed, and no other urinary complications occurred.

In case 4, complications of vesicovaginal fistula and ureteroneocystostomy anastomosis failure occurred. In this case, twice radiation therapy was administered to the recurrent tumour before laparoscopic resection of the recurrent tumour. Radiation therapy was performed at 71 Gy as external irradiation and at 48 Gy as internal irradiation. The pa-

tient had a history of diabetes and hypertension. She had undergone bilateral percutaneous nephrostomy management and is currently alive 42 months after surgery without recurrence. The median length of the postoperative hospital stay was 21 days. Factors responsible for the main hospital discharge period extension included infectious diseases and thrombosis. The follow-up period ranged from 10 to 41 months (median, 15 months) (Table 2).

The comparison of the preoperative imaging tumour size and the postoperative pathological tumour size showed that the postoperative tumour size was larger in all the cases. In the three cases that received preoperative radiation therapy, the postoperative tumour size divided by the preoperative tumour size was 1.6-2.9 (median, 2.3). In the six cases that did not receive preoperative radiation therapy, the postoperative tumour size divided by the preoperative tumour size was 1-1.9 (median, 1.3).

Discussion

We describe the technical feasibility of laparoscopic ureteral reconstruction for the surgery of recurrent gynaecological malignancies. Laparoscopic and robotic surgeries

Table 1. — Preoperative findings.

Case	Primary disease	Primary operation	Radio therapy	Surgical indication	^a Preoperative imaging tumour size (mm)	Preoperative hydronephrosis	Comorbidity
1	EC	mRH, BSO, PLA, PALA, OM	No	Recurrent at parametrium	30	Yes	No
2	OC	SH, BSO, OM, LAR	No	Recurrent at pelvic sidewall	21	Yes	No
3	EC	mRH, BSO, PLA	No	Recurrent at parametrium	29	Yes	HTN
4	EC	SH, BSO, PLA, PALA, OM	Yes	Recurrent at vaginal stump	14	No	DM, HTN
5	CC	SH+BS	No	Recurrent at pelvic lymph node	24	Yes	No
6	CC	mRH, BS	Yes	Recurrent at vaginal stump	25	No	No
7	EC	RH, BSO, PLA	No	Recurrent at pelvic lymph node	30	No	HTN
8	CC	SH, BSO	Yes	Recurrent at vaginal stump	10	No	No
9	CC	mRH, BS	No	Recurrent at vaginal stump	35	No	DM, HTN

EC = endometrial cancer, OC = ovarian cancer, CC = cervical cancer, HTN = hypertension, DM = diabetes mellitus, SH = simple hysterectomy, mRH = modified radical hysterectomy, RH = radical hysterectomy, BS = bilateral salpingectomy, BSO = bilateral salpingo-oophorectomy, OM = omentectomy, PLA = pelvic lymphadenectomy, PALA = para-aortic lymphadenectomy, LAR = lower anterior resection ^aPreoperative imaging tumour size was measured by MRI.

are useful for recurrent tumour resection of the pelvis because they can provide magnification of the visual field and reachability into the deep pelvis with forceps [7, 8]. In all our cases, the tumours were completely excised using laparoscopic multi-organ resection, including bladder and ureteral resection. Either open surgery or laparoscopic surgery should be decided when performing ureteral and/or digestive tract reconstructive surgery after laparoscopic removal of a recurrent tumour. Our study suggests that it is feasible for gynaecologists to perform laparoscopic ureteral reconstruction. Laparoscopic and robot-assisted surgeries are less invasive than laparotomy; thus, it is desirable to perform reconstruction with laparoscopic surgery or robot-assisted surgery if possible. However, laparoscopic or robot-assisted surgery requires high skill, so careful case selection is necessary. Some cases reported successful robot-assisted surgery of recurrent tumour resection of the pelvis [15]. However, there are no studies demonstrating which is better, laparoscopic surgery or robotic surgery. Research is needed to verify which approach is suitable for minimally invasive surgery in ureteral reconstruction surgery.

The success rate of laparoscopic ureteral reconstruction is described as follows. A previous urological study showed that the overall success rate of laparoscopic ureteral reconstruction is approximately 90% [16, 17]. Our gynaecological study showed a similar success rate. In almost all cases, the ureteral stent was removed within 3 months; no hydronephrosis was observed, and no other urinary compli-

cations occurred. However, in one case, complications of vesicovaginal fistula and ureteroneocystostomy anastomosis failure occurred. In this case, severe radiation therapy was administered; in addition, the patient had a history of diabetes, hypertension, and obesity. Whether this complication was specifically caused by laparoscopic surgery is unclear, but patients receiving radiation therapy and those with multiple underlying diseases are at risk for developing postoperative complications.

We suggest that gynaecologists should perform the surgery on recurrent gynaecologic malignancies, including ureteral reconstruction. Surgery by a group of doctors from multiple specialised fields seems to be safe, but when it comes to very complicated surgery, such as recurrent tumour surgery, sole execution of the surgery by a gynaecologic group might improve the prognosis. Mercado *et al.* identified 31,897 advanced ovarian cancer patients and reported that patients treated by a general surgeon had a higher hazard of death (HR = 1.63) compared to those treated by a gynaecologist [5]. They stated that the complexity of surgical treatment appears to warrant the skill of a gynaecologically-trained surgeon. Furthermore, they discussed the necessity of recognising the specific behaviour of the disease. In our study, the postoperative tumour diameter tended to be larger than the tumour diameter observed in the preoperative image evaluation, especially in cases that received radiotherapy. This indicates that more invasive surgery is likely to be required than preoperative eval-

Table 2. — Perioperative findings.

Case	OP time (min)	Blood Loss (mL)	Procedure	Ureteral defect (cm)	ureteral reconstruction	Removal of US/Post-op hydronephrosis	^a Major urological complication	POS (days)	FUP (months)	R0	Pathological tumour Size (mm)
1	438	150	Lt Ur, PC, PV, Lt Pm	6	Lt IS	Yes/No	No	24	12	Yes	58
2	330	75	Rt Ur, Rt IAV, SBR	10	Rt IS	Yes/No	No	20	15	Yes	40
3	645	110	Rt Ur, PC, Rt Pm, LAR	4	Rt IS	Yes/No	No	32	10	Yes	37
4	350	100	Rt Ur, PC, PV	3.5	Rt PH	No/Yes	^b Yes	37	41	Yes	40
5	393	50	Lt Ur, PC, Lt Pm, LAR	6	Lt Bo+PH	Yes/No	No	14	36	Yes	24
6	282	50	Lt Ur, PC, PV, Lt Pm	3.5	Lt PH	Yes/No	No	15	34	Yes	40
7	540	350	Rt Ur, PC, Rt IAV, LAR	4	Rt PH	Yes/No	No	27	15	Yes	30
8	320	110	Rt Ur, PC, Rt Pm, TV	3.5	Rt UC	Yes/No	No	11	13	Yes	23
9	327	180	Rt Ur, PC, PV, Rt Pm, Rt IAV, SBR	3.5	Rt PH	Yes/No	No	21	10	Yes	50

R0 = R0 resection, US = ureteral stent, POS = length of postoperative hospital stay, FUP = follow-up period, Rt = right, Lt = left, Ur = ureterectomy, PC = partial cystectomy, PV = partial vaginectomy, TV = total vaginectomy, Pm = parametrectomy, SBR = small bowel resection, LAR = lower anterior resection, IAV = resection of Internal iliac artery and vein, LV = resection of external iliac vein, IS = ileal substitution, UC = ureterocystoneostomy PH = psoas hitch, B = Boari flap, ^amajor complications about urological problems (defined Clavien-Dindo scale is IIIa or more), ^bvesicovaginal fistula and ureteroneocystostomy anastomosis failure.

uation. Commonly, the tumour edges are unclear in recurrent tumour surgery and a consistent surgical strategy is required. Multidisciplinary surgery might result in inappropriate resection lines and failure of en bloc resection [6]. In addition, the time taken to schedule surgery dates between departments increases the risk of cancer progression and opportunities for surgical treatment may be missed. However, these discussions are only for open surgery, and it is unclear whether the same theory can be applied to laparoscopic surgery. In our study this time, laparoscopic ureteral reconstruction seemed to be technically feasible. A larger study with a single primary cancer type should be conducted and the oncological prognosis should be evaluated in a long-term follow-up study.

We describe the characteristics of ureteral reconstruction in gynaecological surgery for malignant tumours. Some urological studies showed that ureteral reconstruction was successfully performed using laparoscopic or robotic surgery [11, 12]. They performed the psoas hitch, Boari flap and ileal substitution to repair 5-cm to 8-cm, 8-cm to 12-cm, and > 12-cm ureteral defects, respectively [14, 18]. However, in urological studies, a variety of benign pathologies, including vesicoureteral reflux, mega ureter, obstruction, or stricture (congenital or acquired due to surgical injury or infection) is mostly observed. This condition

is very different from the ureteral reconstruction in the gynaecological malignant tumour surgery that we handle. As suggested by our case series, most of the ureteral defects in gynaecological malignant tumour surgery were short defects of the cardinal ligament level, and most of them were 8 cm or less. Nevertheless, some cases required Boari flap and ileal substitution. The reasons for this are as follows. First, recurrent gynaecologic cancer at the pelvis often invades or adheres severely to the bladder, and a relatively high proportion of partial cystectomy is needed to ensure adequate resection margins. Consequently, bladder capacity decreases. Second, in the case of recurrent gynaecologic cancer, radiation is performed in many cases, and the bladder capacity is reduced due to radiation cystitis. In these lower bladder capacity cases, the amputated ureter does not easily reach the partially cystectomised bladder, even if the ureteral defect is short, and Boari flap or ileal substitution is required. Therefore, total laparoscopic surgery for resection of gynaecological recurrent cancer requires anatomical knowledge and suture skills.

The main limitation of this study is its small sample size and the various surgical indications, which make it difficult to discuss the oncological prognosis. Based on the demonstration of feasibility in this study, a larger study on a single primary cancer type should be conducted to discuss the on-

ological prognosis. In addition, the follow-up period of this study might be short. Furthermore, this study lacks a comparison between open ureteral reconstruction and laparoscopic ureteral reconstruction.

Conclusions

Our study demonstrated that it is both effective and feasible for a gynaecologist to perform laparoscopic ureteral reconstruction (combined resection of the bladder and ureter) during laparoscopic surgery for gynaecological recurrent cancer. However, ureteral reconstruction in resection of recurrent gynaecological tumours may require advanced procedures, such as Boari flap and ileal substitution, even with a short ureteral defect, so anatomical knowledge and suture skills are required.

Authors' contributions

All authors contributed to the study conception and design. All authors collected the data. Y.T. and H.K. analysed the data. Y.T. wrote the first draft of the manuscript, and all authors commented on the previous versions of the manuscript. All authors have read and approved the final manuscript.

Ethics approval and consent to participate

All subjects gave their informed consent for inclusion before they participated in the study. The study was conducted in accordance with the Declaration of Helsinki, and the protocol was approved by the Ethics Committee of Cancer Institute Hospital of JFCR (approval number: 2020-1076).

Acknowledgments

The authors thank the doctors of the Department of Genitourinary Oncology, Cancer Institute Hospital of JFCR for their excellent technical advice and splendid assist of peri and post-operative care.

Conflict of Interest

The authors declare no competing interests.

Submitted: September 25, 2020

Accepted: November 05, 2020

Published: December 15, 2020

References

- [1] Giede K.C., Kieser K., Dodge J., Rosen B.: "Who should operate on patients with ovarian cancer? An evidence-based review". *Gynecol. Oncol.*, 2005, 99, 447-461.

- [2] Earle C.C., Schrag D., Neville B.A., Yabroff K.R., Topor M., Fahy A., *et al.*: "Effect of surgeon specialty on processes of care and outcomes for ovarian cancer patients". *JNCI*, 2006, 98, 172-180.
- [3] Vermooij F., Heintz A.P.M., Coebergh J., Massuger L.F.A.G., Witteveen P.O., van der Graaf Y.: "Specialized and high-volume care leads to better outcomes of ovarian cancer treatment in the Netherlands". *Gynecol. Oncol.*, 2009, 112, 455-461.
- [4] Naik R., Galaal K., Alagoda B., Katory M., Mercer-Jones M., Farrel R.: "Surgical training in gastrointestinal procedures within a UK gynaecological oncology subspecialty programme". *BJOG*, 2010, 117, 26-31.
- [5] Mercado C., Zingmond D., Karlan B.Y., Sekaris E., Gross J., Maggard-Gibbons M., *et al.*: "Quality of care in advanced ovarian cancer: The importance of provider specialty". *Gynecol. Oncol.*, 2010, 117, 18-22.
- [6] Nishikimi K., Tate S., Kato K., Matsuoka A., Shozu M.: "Well-trained gynecologic oncologists can perform bowel resection and upper abdominal surgery safely". *J. Gynecol. Oncol.*, 2020, 31, e3.
- [7] Kanao H., Aoki Y., Hisa T., Takeshima N.: "Laparoscopic laterally extended endopelvic resection (LEER) for cervical carcinoma recurring at the pelvic sidewall after concurrent chemoradiotherapy: Our experience in three cases". *Gynecol. Oncol.*, 2018, 149, 428-429.
- [8] Iavazzo C., Gkegkes I.D.: "Robotic technology for pelvic exenteration in cases of cervical cancer". *Int. J. Gynaecol. Obstet.*, 2014, 125, 15-17.
- [9] Fugita O.E., Dinlenc C., Kavoussi L.: "The laparoscopic boari flap". *J. Urol.*, 2001, 166, 51-53.
- [10] Gill I.S., Savage S.J., Senagore A.J., Sung G.T.: "Laparoscopic ileal ureter". *J. Urol.*, 2000, 163, 1199-1202.
- [11] Stein R.J., Turna B., Patel N.S., Weight C.J., Nguyen M.M., Shah G., *et al.*: "Laparoscopic assisted ileal ureter: technique, outcomes and comparison to the open procedure". *J. Urol.*, 2009, 182, 1032-1039.
- [12] Rassweiler J.J., Gözen A.S., Erdogru T., Sugiono M., Teber D.: "Ureteral reimplantation for management of ureteral strictures: a retrospective comparison of laparoscopic and open techniques". *Eur. Urol.*, 2007, 51, 512-523.
- [13] Kanao H., Kanno M., Takeshima N.: "Laparoscopic ureteral reimplantation for the management of long-segment ureteral defect in gynecologic surgeries". *J. Minim. Invasive Gynecol.*, 2020, 27, 1476-1477.
- [14] Stein R., Rubenwolf P., Ziesel C., Kamal M.M., Thüroff J.W.: "Psoas hitch and Boari flap ureteroneocystostomy". *Bju Int.*, 2013, 112, 137-155.
- [15] Yang Q., Tang J.: "Application of robot-assisted laparoscopic pelvic exenteration in treating gynecologic malignancies". *Chin. Med. J. (Engl.)*, 2019, 132, 976-979.
- [16] Farina A., Esposito C., Escolino M., Lopez M., Settini A., Varlet F.: "Laparoscopic extravesical ureteral reimplantation (LEVUR): a systematic review". *Transl. Pediatr.*, 2017, 5, 291-294.
- [17] Kapogiannis F., Spartalis E., Fasoulakis K., Tsourouflis G., Dimitroulis D., Nikiteas N.I.: "Laparoscopic and robotic management of ureteral stricture in adults". *In Vivo*, 2020, 34, 965-972.
- [18] Bansal A., Sinha R.J., Jhanwar A., Prakash G., Purkait B., Singh V.: "Laparoscopic ureteral reimplantation with Boari flap for the management of long-segment ureteral defect: a case series with review of the literature". *Turk. J. Urol.*, 2017, 43, 313-318.

Corresponding Author:

HIROYUKI KANAO

Department of Gynecologic Oncology, Cancer Institute Hospital of JFCR, Koutouku, 135-8550, Tokyo, Japan

e-mail: hiroyuki.kanao@jfc.or.jp