EJGO European Journal of Gynaecological Oncology

Lumbosacral neuropathy and buttock necrosis after internal iliac arterial embolization in abundant bleeding cervical carcinoma

Ş. Gezer[1], Ö. Çakır[2]

[1]*Fellow in Gynecologic Oncology, Department of Obstetrics and Gynecology, Kocaeli University School of Medicine, Kocaeli*
[2]*Department of Radiology, Kocaeli University School of Medicine, Kocaeli (Turkey)*

Summary

Objective: In advanced cases of cervical carcinoma, the tumor may cause massive bleeding requiring blood transfusion. When conservative management is ineffective, internal iliac arterial embolization (IIAE) may be life-saving. *Case Report:* The case of lumbosacral neuropathy and buttock necrosis that developed after IIAE. The posterior branch of the internal iliac artery gives the superior gluteal artery, ilio-lumbar artery, and lateral sacral artery. It was anticipated that the gluteal necrosis and neuropathy in this case developed due to ischemic damage with the occlusion of the posterior branch of the internal iliac artery by the embolizing agent. The use of selective embolization where nutrition of the posterior branch of internal iliac artery is preserved, will prevent similar complications.

Key words: Cervical cancer; Buttock necrosis; Neuropathy; Internal iliac artery embolization.

Introduction

Tumoral tissue in advanced stage cervical cancer may cause severe vaginal bleeding that requires transfusion. The severity of hemorrhage may cause hypovolemic shock in patients. Internal iliac arterial embolization (IIAE), which is performed by interventional radiologists, may be life-saving for patients when bleeding cannot be stopped by locally applied Monsel's solution (ferric subsulfate), vaginal packing or an adrenalin tampon on the cervix [1]. In the present manuscript, the authors report lumbosacral plexopathy and buttock necrosis that developed after IIAE, which was performed to stop life-threatening bleeding due to a cervical carcinoma.

Case Report

A gravida 3, parity 3 woman aged 46 years presented to this hospital with vaginal bleeding. The patient was diagnosed as having squamous cervical cancer ten months ago, and was given teletherapy (external beam radiation, 23 fractions 46 Gy) followed by brachytherapy (three fractions 21 Gy) and chemoradiation (cisplatin five cycles) because the disease was at advanced stage (FIGO 3b). Radiotherapy was completed four months before admission to the hospital. No other characteristics were detected in the history of patient. Her heart rate was 104 bpm, blood pressure 80/50 mm Hg, and respiration rate was 28/minute. A two-unit erythrocyte transfusion was initiated after the detection of hemoglobin: 7.3 g/dL. Bleeding was attempted to be stopped using adrenalin tampon when the patient's bleeding continually increased during follow-up in the intensive care unit. However, the bleeding did not stop. The general condition of the patient was unsuitable for urgent dosing of radiotherapy. Therefore, performing IIAE under general anesthesia was planned.

Distal abdominal aortography and pelvic arteriograms were taken after inserting an angiography catheter into the right main femoral artery. The left internal iliac artery was selectively catheterized, and contrast extravasation and pseudoaneurysm

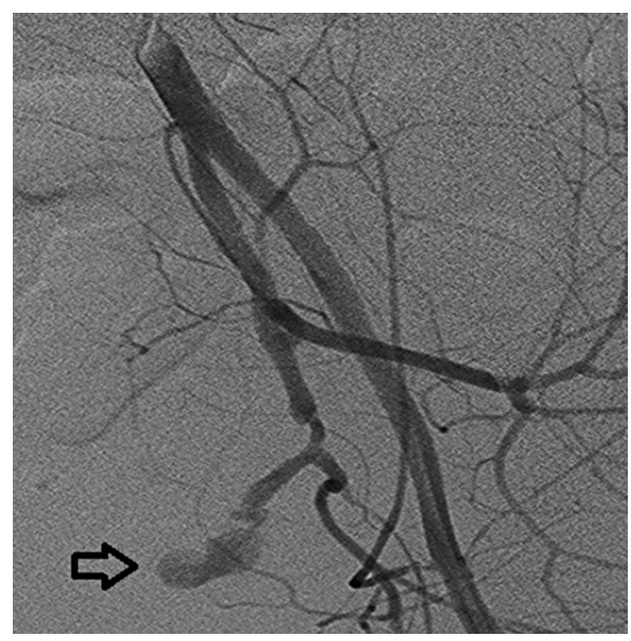

Figure 1. — Contrast extravasation and pseudoaneurysm compatible with hemorrhage in the uterine artery branch using selective catheterization of the left internal iliac artery (black arrow).

Revised manuscript accepted for publication January 18, 2018

7847050 Canada Inc.
www.irog.net

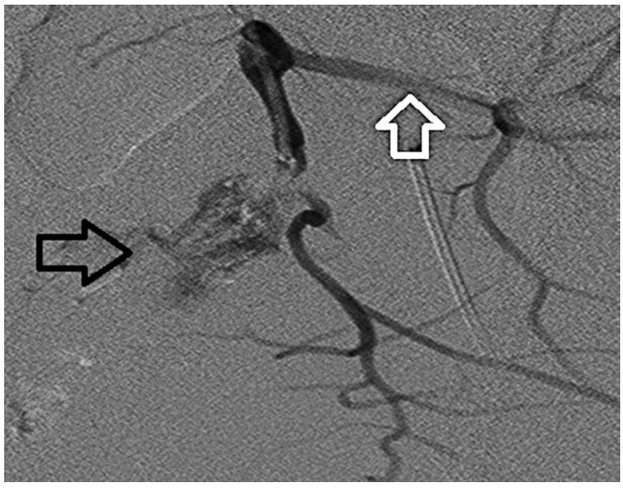

Figure 2. — No pathologic bleeding and pseudoaneurysm were detected in the angiography taken after embolization (black arrow); however, a partial filling defect was observed in the posterior branches of the internal iliac artery (white arrow).

Figure 3. — Left buttock necrosis.

compatible with hemorrhage in the uterine artery branch were observed (Figure 1). Polyvinyl alcohol (PVA) particles in the ranges of 500-1200 microns were injected. No embolizing agent was given in high-flow to avoid reflux. Gelfoam particles mixed at 50% with contrast agent and physiologic serum solution were injected because the required response to embolization could not be obtained during the procedure. No pathologic hemorrhage and pseudoaneurysm was detected in angiographies taken after embolization; however, a partial filling defect was observed in the posterior branches of internal iliac artery (Figure 2). Bleeding completely stopped 24 hours after the procedure. The patient was followed up in the intensive care unit for two days, and eight units of erythrocytes and six units of fresh frozen plasma were administered to the patient. Skin necrosis on the left buttock, and sensation and movement loss in the left foot developed in the first day after the procedure (Figure 3). Magnetic resonance imaging revealed no necrosis in the gluteal muscles, and it was anticipated that necrosis involved the skin and subcutaneous tissue, a 5-cm mass that had invaded the left pelvic wall, and grade 2 hydronephrosis in the left kidney. Plastic surgeons did not recommend debridement, and conservative wound care was performed using mupirocin pomade. Sensational damage involving the entire sacral spinal cord was detected in electroencephalomyelography, and no electrical conduction was detected in any of the left lower extremity nerve. At the end of five months, the necrotic area in the buttock recovered; however, the neurologic deficit remains permanent.

Discussion

Genital hemorrhage that develops in advanced stage cervical carcinoma is a significant cause of morbidity and mortality. Local techniques such as Monsel's solution and adrenalin tampon are frequently used to stop bleeding. Laparotomic or laparoscopic ligation of internal iliac arteries in life-threatening hemorrhage are surgical approaches that may be preferred [2]. However, deteriorated anatomy due to tumor invasion or radiotherapy in these patients may not allow this procedure. IIAE has been used in obstetric and gynecologic emergencies as an alternative to the surgical approach in hemodynamically unstable cases [3].

Pisco *et al.* tested endovascular embolization in 108 patients with pelvic, bladder, and prostate neoplasms, and accomplished complete bleeding control in 69% of patients, and partial control was provided in 21% [4]. Mihmanli *et al.* provided complication-free bleeding control in six patients with gynecologic malignancies [5]. Serdar *et al.* achieved 100% control in eight patients; however, vesicovaginal fistula developed in two patients; it could not be clarified as to whether they were due to embolization or cancer invasion [6]. Tinelli *et al.* obtained complication-free complete bleeding control in ten patients with genital cancer who had severe hemorrhage [7].

Lower extremity paresis [8] and paralysis [9] may be observed after IIAE. Teare *et al.* reported sciatic nerve damage following insertion of a balloon catheter to the internal iliac artery in a patient with placenta percreta [10]. Buttock necrosis is a rare complication reported after IIAE [11, 12].

Association of buttock necrosis and paraplegia after IIAE was reported after pelvic traumas [13]. Similarly, in 2012 Al-Thunyan *et al.* reported buttock necrosis and paraplegia in an obstetric patient [14].

The posterior branch of the internal iliac artery supplies the superior gluteal, ilio-lumbar, and lateral sacral arteries. It was anticipated that the gluteal necrosis and neuropathy, in this case, developed due to ischemic damage with the occlusion of the posterior branch of the internal iliac artery by the embolizing agent. In addition, previous radiotherapy and recurrent pelvic mass of the patient might have had a role as a contributing factor. Selective embolization is recommended to avoid similar damage, and for the identification of bleeding vessels and protection of the posterior branches of the internal iliac artery [15].

In conclusion, IIAE is a treatment option that can be used in life-threatening hemorrhage in patients with advanced-

stage cervical cancer. The use of selective embolization where nutrition of the posterior branch of internal iliac artery is preserved, will prevent similar complications.

Acknowledgments

Özgür Çakır performed the internal iliac artery embolization, Şener Gezer performed literature search, and gave the final approval of the version to be published.

References

[1] Salazar G.M., Petrozza J.C., Walker T.G.: "Transcatheter endovascular techniques for management of obstetrical and gynecologic emergencies". *Tech. Vasc. Interv. Radiol.*, 2009, *12*, 139.

[2] Sobiczewski P., Bidziński M., Derlatka P.: "Laparoscopic ligature of the hypogastric artery in the case of bleeding in advanced cervical cancer". *Gynecol. Oncol.*, 2002, *84*, 344.

[3] Miller F.J. Jr., Mortel R., Mann W.J., Jahshan A.E.: "Selective arterial embolization for control of hemorrhage in pelvic malignancy: femoral and brachial catheter approaches". *AJR Am. J. Roentgenol.*, 1976, *126*, 1028

[4] Pisco J.M., Martins J.M., Correia M.G.: "Internal iliac artery: embolization to control hemorrhage from pelvic neoplasm". *Radiology*, 1989, *172*, 337.

[5] Mihmanli I., Cantasdemir M., Kantarci F., Halit Yılmaz M., Numan F., Mihmanlı V.: "Percutaneous embolization in the management of intractable vaginal bleeding". *Arch. Gynecol. Obstet.*, *2001*, 264, 211.

[6] Yalvac S., Kayikcioglu F., Boran N., Tulunay G., Kose M.F., Bilgic S., Haberal A.: "Embolization of uterine artery in terminal stage cervical cancer". *Cancer Invest.*, 2002, *20*, 754.

[7] Tinelli A., Prudenzano R., Malvasi A., Santantonio M., Lorusso V.: "Emergency endovascular nanopharmacologic treatment in advanced gynecological cancers". *Int. J. Gynecol. Cancer*, 2010, *20*, 1250.

[8] Hare W.S., Holland C.J.: "Paresis following internal iliac artery embolization". *Radiology*, 1983, *146*, 47.

[9] Kritpracha B., Comerota A.J.: "Unilateral lower extremity paralysis after coil embolization of an internal iliac artery aneurysm". *J. Vasc. Surg.*, 2004, *40*, 819.

[10] Teare J., Evans E., Belli A., Wendler R.: "Sciatic nerve ischaemia after iliac artery occlusion balloon catheter placement for placenta percreta". *Int. J. Obstet. Anesth.*, 2014, *23*, 178.

[11] Dietz D.M., Stahlfeld K.R., Bansal S.K., Christopherson W.A.: "Buttock necrosis after uterine artery embolization". *Obstet. Gynecol.*, 2004, *104*, 1159.

[12] Smith D.D., Perez-Delboy A., Burke W.M., Tergas A.I.: "Buttock Necrosis after Uterine Artery Embolization for Delayed Hy sterectomy in Placenta Percreta". *Case Rep. Obstet. Gynecol.*, 2016, *2016*, 6921280.

[13] Suzuki T., Kataoka Y., Minehara H., Nakamura K., Uchino M., Kawai K., Soma K.: "Transcatheter arterial embolization for pelvic fractures may potentially cause a triad of sequel: gluteal necrosis, rectal necrosis, and lower limb paresis". *J. Trauma*, 2008, *65*, 1547.

[14] Al-Thunyan A., Al-Meshal O., Al-Hussainan H., Al-Qahtani M.H., El-Sayed A.A., Al-Qattan M.M.: "Buttock necrosis and paraplegia after bilateral internal iliac artery embolization for postpartumhemorrhage". *Obstet. Gynecol.*, 2012, *120*, 468.

[15] Terek M.C., Saylam C., Orhan M., Yilmaz A., Oztekin K.: "Surgical anatomy of the posterior division of the internal iliac artery: the important point for internal iliac artery ligation to control pelvic haemorrhage". *Aust. N. Z. J. Obstet. Gynaecol.*, 2004, *44*, 374.

Corresponding Author:
Ş. GEZER, M.D.
Division of Gynecologic Oncology
Department of Obstetrics and Gynecology
Kocaeli University School of Medicine
Kocaeli (Turkey)
e-mail: dr.senergezer@gmail.com