

# Loss of 5-hydroxymethylcytosine (5-hmC) expression in endometrioid type endometrial carcinoma

H. Ibrahim, K. Dresser, K. M. Cornejo

<sup>1</sup>Department of Pathology, University of Massachusetts Medical School, UMass Memorial Medical Center, Worcester, MA (USA)

## Summary

**Objectives:** Epigenetic alterations such as DNA methylation are important in cancer development. Recently, the epigenetic marker 5-hydroxymethylcytosine (5-hmC) has been shown to be reduced in a variety of cancers and involved in the process of malignant transformation. The expression of 5-hmC in proliferative endometrium (PE) and endometrioid type endometrial carcinoma (ETEC). **Materials and Methods:** The authors examined the expression of 5-hmC by immunohistochemistry in a total of 60 cases comprised of 29 PE and 31 ETEC. The percentage of nuclear staining was estimated for each case as: 0-25%, 26-50%, and > 50% loss. Endometrial stroma was used as a positive control for the 5-hmC staining. **Results:** Among the 29 PE cases, 28 (97%) had strong and diffuse staining with minimal to no loss of 5-hmC expression ( $\leq 25\%$  of the cells). A loss of 5-hmC staining was observed in > 25% of the cells in 25 of 31 (81%) ETEC cases, of which 16 (52%) of these cases displayed a loss in > 50% of the tumor cells. The loss of 5-hmC expression was significantly increased in ETEC cases in comparison to the PE cases ( $p < 0.0001$ ) by Fishers exact test. **Conclusions:** This study demonstrates that 5-hmC expression is significantly reduced in ETEC compared with PE. These findings suggest that the loss of 5-hmC is an epigenetic event in ETEC and may play a role in its development and progression.

**Key words:** 5-hmC; 5-hydroxymethylcytosine; Immunohistochemistry; Endometrium; Endometrial carcinoma.

## Introduction

Cancer is characterized by genetic and epigenetic aberrations and DNA methylation status is frequently altered in neoplastic cells. 5-hydroxymethylcytosine (5-hmC) is an intermediate in the demethylation process, which was first identified in the 1970's by Penn *et al.* [1]. DNA methylation is effectively reversed by the ten-eleven translocation (TET) family of enzymes, resulting in a variety of demethylated intermediate states, including 5-hmC [2]. 5-hmC levels are decreased in numerous malignancies, including glioblastoma, melanoma, myeloid malignancies, parathyroid, breast, prostate, hepatic, gastric, squamous cell, and renal cancers [3-14]. Recently, loss of 5-hmC levels have been reported to be associated with poor outcomes in some malignancies, such as melanoma, hepatic, gastric, ovarian, and renal cell carcinomas [8, 11-13, 15].

Endometrial cancer is the third most frequent gynecologic malignancy worldwide [16]. Endometrial cancer is a multifactorial disease and the molecular mechanisms underlying its development and progression is poorly understood. The expression of 5-hmC as an intermediate in the demethylation pathway has not been well studied in endometrial carcinoma. The authors aim to examine the expression of 5-hmC in endometrioid type endometrial carcinoma (ETEC) compared to proliferative endometrium (PE).

## Materials and Methods

After approval by the University of Massachusetts Medical School Institutional Review Board, the surgical pathology archives were randomly searched for ETEC and PE cases from January 2013 to December 2016, which contained residual remaining archival formalin-fixed, paraffin-embedded tissue. Select blocks from each case were then assessed for 5-hmC expression by immunohistochemistry.

Immunohistochemical studies were performed on 5-um sections of formalin-fixed, paraffin-embedded tissue. Slides were first deparaffinized, and rehydrated. Antigen retrieval was carried out with 0.01M citrate buffer at pH 6.0 for slides to be stained for 5-hmC. Slides were heated in a 770-W microwave oven for 14 minutes, cooled to room temperature, and rinsed in distilled water. The slides were then placed in 2N HCl for 30 minutes to digest and rinsed in distilled water and Tris-buffer to neutralize the acid. The slides were stained on an autostainer using the staining reagents.

The sections were first blocked for endogenous non-specific protein and peroxidase activity with an application of dual endogenous block for ten minutes, followed by a buffer wash. The sections were incubated for 60 minutes with rabbit-anti-5-hmC at 1:5,000. Following a buffer wash, sections were incubated with a detection reagent (a polymer conjugated with goat-anti-mouse-Ig, goat-anti-rabbit-IgG, and horse-radish peroxidase) for 30 minutes. The sections were washed and treated with a solution of diaminobenzidine and hydrogen peroxide for ten minutes, to produce the visible brown pigment. After rinsing, a toning solution was used for two minutes to enrich the final color. The sections were counterstained with hematoxylin, dehydrated, and cover slipped with permanent media. The endometrial stroma was used

Revised manuscript accepted for publication October 3, 2018

Table 1. — Summary of cases with 5-hmC expression.

Diagnosis	0-25% loss (3+)	26-50% loss (2+)	>50% loss (1+)
PE (n=29)	28 (97%)	0 (0%)	1 (3%)
ETEC (n=31)	6 (30%)	9 (29%)	16 (52%)

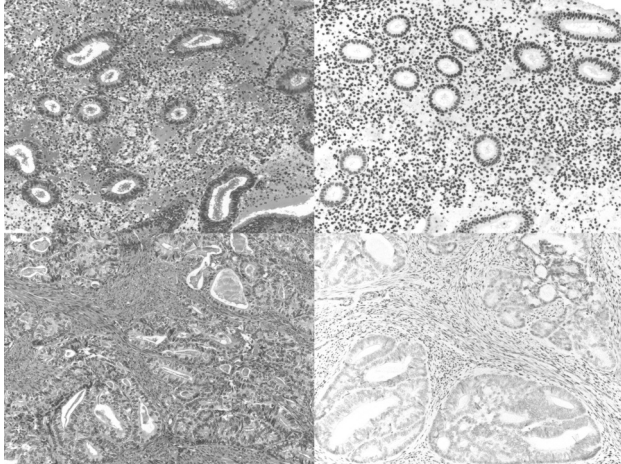


Figure 1. — Expression of 5-hmC in PE and ETEC. A) PE with B) strong positive nuclear staining for 5-hmC ( $\times 100$ ). C) ETEC with D) loss of 5-hmC expression and a positive internal control with diffuse staining in the endometrial stroma ( $\times 100$ ).

as a positive internal control for 5-hmC staining. Negative controls were performed by replacing the primary antibody with non-immune IgG.

The diagnosis of either PE or ETEC was established by examination of hematoxylin and eosin stained sections. Positive staining for 5-hmC was defined as a dark brown nuclear staining pattern in the lesional cells, which was easily observed at low-power magnification ( $< \times 40$ ). No staining was considered negative. The degree of loss of nuclear staining was evaluated based upon the following grading system: 1+ ( $> 50\%$  loss), 2+ (26-50% loss) and 3+ ( $\leq 25\%$  loss).

## Results

A total of 60 cases comprising of 29 PE and 31 ETEC were examined for 5-hmC expression. Among the 29 PE cases, 28 (97%) had strong and diffuse staining with minimal to no loss of 5-hmC expression ( $\leq 25\%$  loss; 3+) (Table 1, Figure 1). A loss of 5-hmC staining was observed in  $> 25\%$  of the tumor cells (1-2+), in 25 of 31 (81%) ETEC cases, of which a little over half ( $n=16$ ; 52%) of these displayed a loss in  $> 50\%$  (1+) of tumor cells. The loss of 5-hmC expression was significantly increased in ETEC cases in comparison to the PE cases ( $p < 0.0001$ ) by Fishers exact test.

## Discussion

DNA methylation is a significant epigenetic modification that has been found to be associated with cancer

pathogenesis [17, 18]. The TET family of proteins convert 5-methylcytosine (5-mc) to a DNA methylation intermediate 5-hmC. Significant reduction in 5-hmC expression has been identified in a number of malignancies [8, 11-13, 15, 18, 19]. The loss of 5-hmC has also been associated with reduced TET expression [20, 21]. At present, only a few studies evaluated DNA methylation processes in neoplasia of the endometrium. Herein, the authors report the presence of 5-hmC in PE and showed a significant loss of 5-hmC expression in ETEC. The results indicate that loss of 5-hmC is an epigenetic event that occurs in ETEC. Similarly, Ciesielski *et al.* reported decreased TET1 and TET2 mRNA expression by real-time quantitative PCR analysis in endometrial cancer in comparison to normal endometrium control tissues [21]. The mean mRNA expression of TET1 and TET2 was also much lower in more advanced cancers (Stage III-IV), which also exhibited the ability to metastasize to regional lymph nodes, in comparison to non-metastatic and low-staged (Stage I-II) cancers [21]. Interestingly, the expression of TET1 and TET2 corresponded to the expression pattern of 5-hmC. This indicates a possible role of TET1 and TET2 in the loss of 5-hmC expression during carcinogenesis in the endometrium [21]. However, unlike TET1 and TET2, 5-hmC levels in DNA did not significantly correlate with prognostic clinicopathological parameters such as tumor stage and lymph node metastasis in their study [21].

A recent study by Roca *et al.* evaluated the expression of TET genes and 5-hmC in endometriosis in comparison to control non-endometriotic endometrium. They identified TET1, TET2, and TET3 expression was decreased in endometriosis compared to the control endometrium, which suggests these DNA methylation epigenetic events may also possibly play a role in the pathogenesis of endometriosis [22].

An early diagnosis is important in improving the prognosis of ETEC. A large majority of ETEC are preceded or associated with pre-malignant lesions such as endometrial hyperplasia or endometrial intraepithelial neoplasia (EIN), but the histological assessment of these entities is often subjective. Therefore, identifying a marker specifically associated with malignant transformation is of great importance.

The present study, in addition to the studies performed by Ciesielski *et al.* and Roca *et al.*, suggest that the loss of 5-hmC and TET expression are epigenetic events involved in neoplasia of the endometrium [21, 22]. Additional studies with a larger cohort of patients will be needed to further characterize the role of 5-hmC deficiency in the spectrum of endometrial neoplasia, such as in endometrial hyperplasia or EIN and its relationship to the tumor behavior, response to treatment, and patient survival in patients with ETEC.

## References

- [1] Penn N.W., Suwalski R., O'Riley C., Bojanowski K., Yura R.: "The presence of 5-hydroxymethylcytosine in animal deoxyribonucleic acid". *Biochem. J.*, 1972, 126, 781.
- [2] Wu X., Zhang Y.: "TET-mediated active DNA demethylation: mechanism, function and beyond. Nature reviews". *Genetics*, 2017, 18, 517.
- [3] Magotra M., Sakhdari A., Lee P.J., Tomaszewicz K., Dresser K., Hutchinson L.M., et al.: "Immunohistochemical loss of 5-hydroxymethylcytosine expression in acute myeloid leukaemia: relationship to somatic gene mutations affecting epigenetic pathways". *Histopathology*, 2016, 69, 1055.
- [4] Eleftheriou M., Pascual A.J., Wheldon L.M., Perry C., Abakir A., Arora A., et al.: "5-Carboxylcytosine levels are elevated in human breast cancers and gliomas". *Clin. Epigenetics*, 2015, 7, 88.
- [5] Jawert F., Hasseur B., Kjeller G., Magnusson B., Sand L., Larsson L.: "Loss of 5-hydroxymethylcytosine and TET2 in oral squamous cell carcinoma". *Anticancer Res.*, 2013, 33, 4325.
- [6] Barazeghi E., Gill A.J., Sidhu S., Norlen O., Dina R., Palazzo F.F., et al.: "5-Hydroxymethylcytosine discriminates between parathyroid adenoma and carcinoma". *Clin. Epigenetics*, 2016, 8, 31.
- [7] Murata A., Baba Y., Ishimoto T., Miyake K., Kosumi K., Harada K., et al.: "TET family proteins and 5-hydroxymethylcytosine in esophageal squamous cell carcinoma". *Oncotarget*, 2015, 6, 23372.
- [8] Lian C.G., Xu Y., Ceol C., Wu F., Larson A., Dresser K., et al.: "Loss of 5-hydroxymethylcytosine is an epigenetic hallmark of melanoma". *Cell*, 2012, 150, 1135.
- [9] Tsai K.W., Li G.C., Chen C.H., Yeh M.H., Huang J.S., Tseng H.H., et al.: "Reduction of global 5-hydroxymethylcytosine is a poor prognostic factor in breast cancer patients, especially for an ER/PR-negative subtype". *Breast Cancer Res. Treat.*, 2015, 153, 219.
- [10] Strand S.H., Hoyer S., Lynnerup A.S., Haldrup C., Storebjerg T.M., Borre M., et al.: "High levels of 5-hydroxymethylcytosine (5hmC) is an adverse predictor of biochemical recurrence after prostatectomy in ERG-negative prostate cancer". *Clin. Epigenetics*, 2015, 7, 111.
- [11] Du C., Kurabe N., Matsushima Y., Suzuki M., Kahyo T., Ohnishi I., et al.: "Robust quantitative assessments of cytosine modifications and changes in the expressions of related enzymes in gastric cancer". *Gastric Cancer*, 2015, 18, 516.
- [12] Liu W.R., Tian M.X., Jin L., Yang L.X., Ding Z.B., Shen Y.H., et al.: "High expression of 5-hydroxymethylcytosine and isocitrate dehydrogenase 2 is associated with favorable prognosis after curative resection of hepatocellular carcinoma". *J. Exp. Clin. Cancer Res.*, 2014, 33, 32.
- [13] Chen K., Zhang J., Guo Z., Ma Q., Xu Z., Zhou Y., et al.: "Loss of 5-hydroxymethylcytosine is linked to gene body hypermethylation in kidney cancer". *Cell Res.*, 2016, 26, 103.
- [14] Orr B.A., Haffner M.C., Nelson W.G., Yegnasubramanian S., Eberhart C.G.: "Decreased 5-hydroxymethylcytosine is associated with neural progenitor phenotype in normal brain and shorter survival in malignant glioma". *PLoS One*, 2012, 7, e41036.
- [15] Zhang L.Y., Li P.L., Wang T.Z., Zhang X.C.: "Prognostic values of 5-hmC, 5-mC and TET2 in epithelial ovarian cancer". *Arch. Gynecol. Obstet.*, 2015, 292, 891.
- [16] Torre L.A., Bray F., Siegel R.L., Ferlay J., Lortet-Tieulent J., Jemal A.: "Global cancer statistics, 2012". *CA Cancer J. Clin.*, 2015, 65, 87.
- [17] Vasanthakumar A., Godley L.A.: "5-hydroxymethylcytosine in cancer: significance in diagnosis and therapy". *Cancer Genet.*, 2015, 208, 167.
- [18] Kudo Y., Tateishi K., Yamamoto K., Yamamoto S., Asaoka Y., Ijichi H., et al.: "Loss of 5-hydroxymethylcytosine is accompanied with malignant cellular transformation". *Cancer Sci.*, 2012, 103, 670.
- [19] Ye C., Li L.: "5-hydroxymethylcytosine: a new insight into epigenetics in cancer". *Cancer Biol. Ther.*, 2014, 15, 10.
- [20] Yang H., Liu Y., Bai F., Zhang J.Y., Ma S.H., Liu J., et al.: "Tumor development is associated with decrease of TET gene expression and 5-methylcytosine hydroxylation". *Oncogene*, 2013, 32, 663.
- [21] Ciesielski P., Jozwiak P., Wojcik-Krowiranda K., Forma E., Cwonda L., Szczepanec S., et al.: "Differential expression of ten-eleven translocation genes in endometrial cancers". *Tumour Biol.*, 2017, 39, 1010428317695017.
- [22] Roca F.J., Loomans H.A., Wittman A.T., Creighton C.J., Hawkins S.M.: "Ten-Eleven Translocation Genes are Downregulated in Endometriosis". *Curr. Mol. Med.*, 2016, 16, 288.

Corresponding Author:  
K. CORNEJO, M.D.  
Department of Pathology  
Massachusetts General Hospital  
55 Fruit St, Warren 831B  
Boston, MA 02114 (USA)  
e-mail: Kcornejo@partners.org