EJGO European Journal of Gynaecological Oncology

Long-term postoperative follow-up of a patient with a borderline serous tumor arising from a paratubal cyst: a case report and review of the literature

J. H. Ahn[1], K. J. Um[1], H. S. Kim[1], Y. J. Jeong[1], Y. S. Lee[2], S. H. Kim[3], J. H. Choi[1]

[1]*Department of Obstetrics and Gynecology, Seoul Medical Center, Seoul*
[2]*Department of Obstetrics and Gynecology, The Catholic University of Korea, College of Medicine, Seoul*
[2]*Department of Nursing, Seoul Medical Center, Seoul (Korea)*

Summary

Background: Borderline paratubal cysts (BPC) are extremely rare, with only nine cases reported in the literature. *Case Report:* A 40-year-old woman presented with a large adnexal mass on gynecological examination. The abdominopelvic computed tomography scan revealed a 20×16-cm-sized cystic adnexal mass that contained no solid portion. The CA 125 level was elevated. She underwent a left salpingectomy with paratubal cystectomy, and frozen-section analysis revealed that the mass was benign. However, the final pathological diagnosis was borderline serous paratubal cyst. The patient underwent another surgery, i.e., ipsilateral oophorectomy with contralateral ovarian biopsy. She was followed up for ten years postoperatively, and no recurrence was observed. *Conclusion:* BPCs are extremely rare, and thus, optimal management methods are unknown. However, conservative surgery is performed in most cases. This is the longest reported follow-up after conservative surgery in a case of BPCs. Continued reporting of BPCs is essential for understanding their prognosis and treatment.

Key words: Paratubal cyst; Borderline paratubal cysts.

Introduction

Paratubal cysts, also known as Morgagni's hydatid cysts, are found in the mesosalpinx, independent of the lumen of the salpinx, and account for approximately 10% of all adnexal masses [1]. Approximately 76% of these cysts originate from the remnants of paramesonephric (Müllerian) or mesonephric (Wolffian) ducts [2].

Most paratubal cysts are benign; however, approximately 2–3% of these cysts have been reported to be malignant [3]. Borderline paratubal cysts (BPC) are very rare, with only nine cases reported in the literature available in English [1, 3-10].

Diagnosing BPCs is difficult. Preoperative imaging studies and tumor markers can be helpful to evaluate the potential malignancy. However, typical imaging findings and tumor markers are currently unknown. Hence, frozen-section analysis may be helpful for making diagnoses in such cases. The appropriate surgical management of BPCs is not well-established owing to its rarity. Finding the optimal treatment for these cysts requires more case reports with long-term monitoring or follow-up. Here, the authors report a case of a borderline paratubal serous cyst in which the patient was followed up postoperatively for ten years, and they also present a review of the literature.

Revised manuscript accepted for publication October 30. 2018

Case Report

A 40-year-old multiparous woman was admitted to this gynecologic clinic with a known adnexal mass. She had a ten-year history of adnexal mass and recently developed abdominal distention. A large pelvic mass was noted on her abdominal exam without tenderness or rebound tenderness. The CA 125 level was elevated to 309.5 (normal range: 0-35) U/mL, but CA 19-9 level was normal. A transvaginal ultrasonography revealed a well-defined, homogenous, low echogenic, 18.7×15.4-cm-sized cystic mass without a solid portion or papillary projection (Figure 1). The abdominopelvic computed tomography (CT) scan showed a 20×16-cm-sized lobulated cystic mass with internal septation, but no solid portion. Both ovaries were clearly examined, and a benign paraovarian or mesenteric cyst was suspected. No lymph node enlargement or ascites were observed (Figure 1).

During the exploratory laparotomy, a 16.5×14-cm-sized paratubal cyst was found, located in the ampullary portion of the left fallopian tube. (Figure 1) The paratubal cyst was attached to the tube but separated from the lumen of the tube. No abnormal pelvic lymph node enlargement or intraperitoneal tumor spread was found. The authors obtained 50 cc of ascites for peritoneal cytology. After the aspiration of 2,000 mL of chocolate-colored serous fluid in the paratubal cyst, left salpingectomy with paratubal cystectomy was performed. The frozen-section analysis of specimens showed negative results for malignancy. However, the final pathological review showed a serous type tumor of low malignant potential. The ipsilateral fallopian tube was not involved, and peritoneal cytology was negative. Gross pathological findings showed a 16.5×14-cm-

7847050 Canada Inc.
www.irog.net

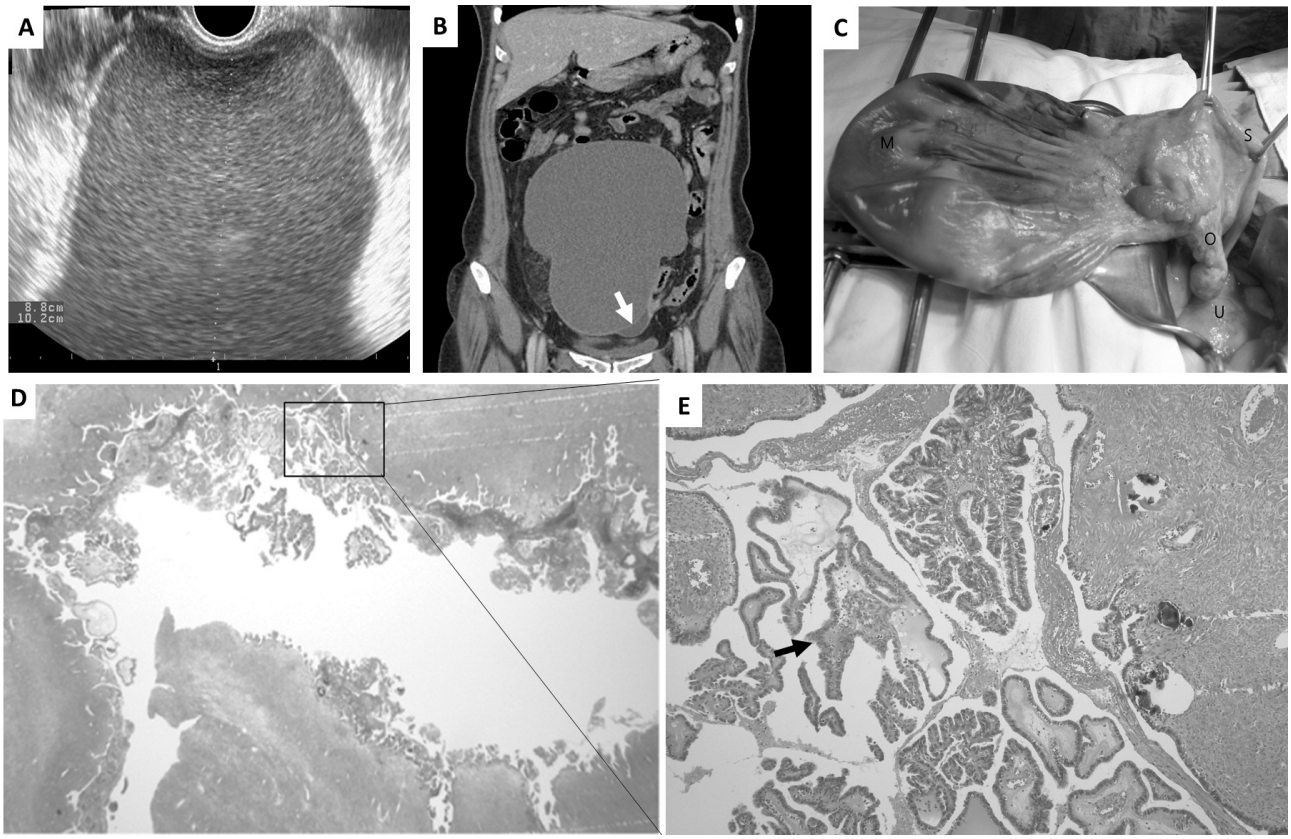

Figure 1. — Transvaginal ultrasonographic findings: a well-marginated cystic mass without a solid portion and papillary projection is observed (A). Abdominopelvic computed tomography scan findings: an approximately 20×16-cm-sized cystic mass with a septum (arrow) is noted (B). Gross appearance of the specimen: M (mass), S (salpinx), O (ovary), U (uterus) (C). Serous tumor of low malignant potential (box): HE ×1.25 magnification (D). Serous tumor of low malignant potential. The proliferating serous epithelium (arrow) shows stratification and tufting, but lacks significant atypia and does not invade the underlying stroma: HE ×10 magnification (E).

sized cystic mass. The external surface of the tumor was homogeneously brownish, smooth, whereas its internal surface had multiple papillary excrescences. Furthermore, the outside surface was evidently not involved. The microscopic examination revealed papillae covered by serous type epithelium, with the serous epithelium lining the papillae remarkable for stratification. There was no significant nuclear atypia and stromal invasion. These histological features are indicative of a serous tumor of low malignant potential confined to the left paratubal cyst.

After four weeks, the patient underwent a laparoscopic left oophorectomy and right ovarian biopsy. The pathologic evaluation of all specimens revealed no malignancy. Postoperatively, her tumor marker CA 125 was normal without adjuvant therapy. The patient has been undergoing regular follow-ups, during which serum CA 125 measurement and transvaginal ultrasonography are performed, at this outpatient clinic. The woman has lived with no evidence of recurrent disease for ten years.

Discussion

BPCs are very rare. Only nine other cases have published since Salamon *et al.*'s first report in 2005 [4]. The clinical and pathological characteristics of these patients are summarized in Table 1. The mean age of patients was 28 (range: 17–45) years. Preoperative tumor marker levels such as CA 125 and CA 19-9 in previous cases were normal, but in our case, the CA 125 level (309.5 U/mL) was elevated. In the preoperative ultrasonographic or CT finding, four cases presented papillary projection. Most cases (90%) underwent conservative surgery. The frozen-section analysis revealed that the mass was benign; however, the final diagnosis was borderline tumor in three cases, including the present. The range of observation period after surgery in previous cases was 3–24 months. In this case, the patient was followed up for ten years after conservative surgery with no recurrence. This is the longest follow-up reported in a case of BPCs.

Preoperative diagnosis for BPCs is important to properly manage the tumor, but it is difficult. Physicians usually use tumor markers, such as CA 125 and CA 19-9, to evaluate the malignancy. However, the CA 125 in most reported cases was normal, except that in the current case (Table 1), and therefore this may not be a specific marker for BPC diagnosis. In preoperative imaging findings, papillary projection that may be helpful to diagnose ma-

Table 1. — *Characteristics of reported borderline paratubal cysts.*

Author	Age	Preoperative tumor markers		Imaging finding		Pathology		Surgery	Follow-up
		CA 125 (normal,<35 U/mL)	CA 19-9 (normal,<35 U/mL)	Papillary projections	Size (cm)	Frozen section analysis	Final diagnosis		
Salamon (2005)[4]	45	*	*	Yes	3	Benign	Endometrioid BT	Conservative†	1year ,no recurrence
Seamon (2008)[5]	26	*	*	No	12	Serous BT	Serous BT	Conservative	11months, no recurrence
Kumbak (2010)[6]	39	*	*	*	6	Serous BT	Serous BT	Conservative	3months, no recurrence
Shin (2010)[3]	27	Normal	*	No	16	Serous BT	Serous BT	Conservative	20months, no recurrence
Tereck (2011)[8]	19	Normal	Normal	Yes	10	Serous BT	Serous BT	Conservative	7months, no recurrence
Im (2011)[7]	20	Normal	*	No	9	Mucinous BT	Mucinous BT	Conservative	30months, no recurrence
Kiseli (2012)[1]	17	Normal	*	Yes	7	Benign	Serous BT	Conservative	1year ,no recurrence
Alaoui (2012)[9]	38	Normal	*	No	10	*	Serous BT	Radical‡	1year, no recurrence
Lee (2016)[10]	17	Normal	Normal	Yes	19	Serous BT	Serous BT	Conservative	3month, no recurrence
Current case (2018)	40	309.5	Normal	No	16.5	Benign	Serous BT	Conservative	10 years, no recurrence

**not specified, BT: borderline tumor. †Conservative surgery indicates preservation of the uterus and at least part of one ovary. ‡Radical surgery indicatres hysterectomy and bilateral salpingo-oophorectomy.*

lignancy or borderline malignancy [11] was observed in only 40% of reported BPCs (Table 1). In addition, operators cannot easily distinguish intraoperatively whether the tumor is benign or borderline.

Frozen-section analysis can be used if the tumor is suspected to be malignant or borderline. In six of nine cases, the diagnosis indicated by frozen-section analysis was consistent with the final diagnosis (Table 1). As observed in this case, if the tumor presents as benign without papillary projection or a solid portion in the preoperative imaging study but with elevated tumor marker levels, frozen-section analysis should be performed to evaluate the possibility of a BPC.

Most previous BPCs were treated with conservative surgery and no adjuvant chemotherapy, as in this case (Table 1). Due to the rarity of BPCs, a limitation exists in understanding the clinical progress, and their optimal management has not been clearly elucidated. However, as microscopic examination is similar to that of the ovary, this can be inferred from an borderline ovarian tumor treatment [3]. The average age of patients with borderline ovarian tumors is 40 years; thus, fertility-preserving surgeries are usually performed [12]. In Park *et al.*'s study on patients with borderline ovarian tumor who underwent conservative surgery and radical surgery, the difference between disease-free and overall survival was not significant [13]. All patients reported to have BPCs were of reproductive age and had a unilateral tumor. Most of them underwent fertility-sparing surgeries, without recurrence being observed (Table 1). To obtain data on survival after conservative surgery, long-term close observation is required. Some authors have suggested that close follow-up for ten years using ultrasonography and tumor marker examination is necessary [9].

To the present authors' knowledge, this is the only reported postoperative long-term follow-up study among the reported BPC cases. They observed that this patient was free of disease recurrence for ten years after undergoing a fertility-sparing operation. This case is also the first to show that conservative surgery can be an appropriate treatment method. Therefore, the present authors believe that fertility-sparing surgery can be considered safe and used in cases of BPCs if patients desire to have children in the future. More reports of cases with long-term monitoring is crucial to establish optimal surgical management strategies for BPCs.

References

[1] Kiseli M., Caglar G.S., Cengiz S.D., Karadag D., Yilmaz M.B.: "Clinical diagnosis and complications of paratubal cysts: review of the literature and report of uncommon presentations". *Arch. Gynecol. Obstet.,* 2012, *285*, 1563.

[2] Shin E., Kang E.J., Chang E.M., Cha Y.J., Jeon S.W., Lee S.Y., *et al.*: "Two cases of paratubal cysts manifesting as huge pelvic masses in young women". *Korean Journal of Obstetrics and Gynecology,* 2008, *51*, 574.

[3] Shin Y.J., Kim J.Y., Lee H.J., Park J.Y., Nam J.H.: "Paratubal serous borderline tumor". *J. Gynecol. Oncol.,* 2011, *22*, 295.

[4] Salamon C., Tornos C., Chi D.S.: "Borderline endometrioid tumor arising in a paratubal cyst: a case report". *Gynecol. Oncol.,* 2005, *97*, 263.

[5] Seamon L.G., Holt C.N., Suarez A., Richardson D.L., Carlson M.J., O'Malley D.M.: "Paratubal borderline serous tumors". *Gynecol. Oncol.,* 2009, *113*, 83.

[6] Kumbak B., Celik H., Cobanoglu B., Gurates B.: "Paratubal borderline tumor incidentally found during cesarean section: case report and review of literature". *Eur. J. Surg. Oncol.,* 2010, *36*, 789.

[7] Im H.S., Kim J.O., Lee S.J., Lee Y.S., Park E.K.: "Borderline mucinous tumor arising in a paratubal cyst: a case report". *Eur. J. Gynaecol. Oncol.,* 2011, *32*, 206.

[8] Terek M.C., Sahin C., Yeniel A.O., Ergenoglu M., Zekioglu O.: "Paratubal borderline tumor diagnosed in the adolescent period: a case report and review of the literature". *J. Pediatr. Adolesc. Gynecol.,* 2011, *24*, e115.

[9] Alaoui F.Z., El Fatemi H., Chaara H., Melhouf M.A., Amarti A.: "Borderline paratubal cyst: a case report". *Pan. Afr. Med. J.,* 2012, *13*, 53.

[10] Lee S., Ahn K.H., Park H.T., Hong S.C., Lee Y.J., Kim I.S., *et al.*: "Paratubal Borderline Malignancy: A Case of a 17-Year-Old Adolescent Female Treated with Laparo-Endoscopic Single-Site Surgery and a Review of the Literature". *J. Pediatr. Adolesc. Gynecol.,* 2016, *29*, 74.

[11] Suzuki S., Furukawa S., Kyozuka H., Watanabe T., Takahashi H., Fujimori K.: "Two cases of paraovarian tumor of borderline malignancy". *J. Obstet. Gynaecol. Res.,* 2013, *39*, 437.

[12] Ozols R.F., Schwartz P.E., Eifel P.J.: "Ovarian cancer, Fallopian tube carcinoma, and peritoneal carcinoma". *In:* Devita V.Y., Hellman S., Rosenberg S.A. (eds). *Cancer: Principles and Practice of Oncology*. 6th ed. Philadelphia, PA: Lippincott Williams & Wilkins Publishers, 2001, 1597.

[13] Park J.Y., Kim D.Y., Kim J.H., Kim Y.M., Kim Y.T., Nam J.H.: "Surgical management of borderline ovarian tumors: The role of fertility-sparing surgery". *Gynecol. Oncol.,* 2009, *113*, 75.

Corresponding Author:
J. H. CHOI, M.D.
Department of Obstetrics and Gynecology
Seoul Medical Center
156, Sinnae-ro
Jungnang-gu, Seoul 02053 (Korea)
e-mail: harmony4@catholic.ac.kr