EJGO European Journal of Gynaecological Oncology

The performance of pre-operative MRI in service-based centers in diagnosing cervical invasion by endometrial carcinoma

J.H.S. Lee, T.H. Cheung, S.F. Yim

Department of Obstetrics and Gynaecology, Prince of Wales Hospital, The Chinese University of Hong Kong, Hong Kong (China)

Summary

Purpose of investigation: To investigate the performance of MRI and/or gross examination of specimen in detecting cervical invasion and factors that may influence MRI's performance. *Materials and Methods:* Endometrial cancer patients who had hysterectomy in Prince of Wales Hospital in Hong Kong from January 2007 to November 2014 were identified retrospectively. Those who had preoperative MRI assessment for cervical invasion were included. Patient's records were reviewed for demographic, operative, MRI, and pathological findings. The accuracy of MRI and operative findings were determined by correlating with pathological findings. *Results:* A total of 318 patients were included. The accuracy, sensitivity, specificity, positive predictive value, negative predictive value, positive likelihood ratio, and negative likelihood ratio of MRI in diagnosing cervical invasion were 86.5%, 48%, 93.7%, 58.5%, 90.6%, 7.57, and 0.56, respectively. Area under the curve was 0.71. The accuracy, sensitivity, and specificity of gross examination were 89.6%, 51.9% and 96.4%, respectively. The accuracy, sensitivity and specificity of combined assessment with MRI and gross examination were 85.8%, 56.3%, and 91.2%, respectively. *Conclusions:* MRI has high accuracy and specificity but low sensitivity in detecting cervical invasion. The performance of gross examination of specimen is comparable to MRI. MRI cannot be recommended as sole assessment method to detect cervical invasion by endometrial cancer and a higher sensitivity can be achieved by the combined assessment approach.

Key words: Endometrial cancer; Cervical invasion; MRI; Gross examination of specimen.

Introduction

Endometrial cancer is the most common gynaecological malignancy in the developed world and its incidence is on the rise in Hong Kong [1, 2]. Endometrial cancer is a surgically staged disease. Full surgical staging involves pelvic and paraaortic lymphadenectomy that carries significant morbidity [3]. There are studies showing that lymphadenectomy can be safely omitted in low-risk early stage endometrial cancer patients [4]. However, for intermediate to high risk endometrial cancer patients, lymphadenectomy is indicated to look for nodal metastasis.

Stage 2 endometrial cancer is characterized by cervical invasion and the five-year survival rate is lower than Stage 1 endometrial cancer patients (78% *vs*. 90%) [5]. This may be attributable to a high incidence of pelvic lymph node metastasis and the reported incidence was 16% in one study [6]. Radical hysterectomy has been suggested to be the treatment of choice for Stage 2 endometrial cancer because studies showed the survival outcome was better after radical hysterectomy than simple hysterectomy in Stage 2 endometrial cancer patients [7, 8]. Postoperative adjuvant radiotherapy is often recommended for Stage 2 endometrial cancer patients that had undergone simple hysterectomy as the primary surgical treatment. Identifying endometrial cancer patients with cervical involvement is therefore important so that radical hysterectomy and lymphadenectomy can be performed by trained gynae-oncologists to improve the treatment outcome.

Pre-operative assessment of cervical invasion by endometrial cancer can be achieved by MRI, transvaginal ultrasound (TVS), CT, and hysteroscopy. MRI is the most widely used investigation and its use for pre-operative assessment of endometrial cancer has increased by ten-fold in the last ten years [9]. Cervical invasion is diagnosed by MRI when the endocervical canal is widened by a tumour with same signal intensity as the endometrial lesion on T2WI, and dynamic image shows interruption of the enhancing epithelium with disruption of the low signal stroma [10]. A study performed in a tertiary centre with designated radiologists and standardized MRI protocol reported the sensitivity of MRI in diagnosing cervical involvement to be 88% [11] but another study reported a much lower sensitivity of 33% [12]. Most of these studies were performed in tertiary center with designated radiologists and standardized MRI protocol. Whether these results reflect the performance of service based centers are uncertain. Since MRI requires many resources and may delay the surgical intervention, there is a need to evaluate its performance in pre-operative assessment of endometrial cancer.

Besides performing MRI to evaluate cervical invasion, gross examination of the uterine specimen after hysterectomy for cervical invasion may also provide useful infor-

Revised manuscript accepted for publication May 24, 2016

7847050 Canada Inc.
www.irog.net

mation to guide the subsequent surgical treatment. Previous studies showed the sensitivity of intra-operative gross examination of hysterectomy specimen ranging from 29% to 89% [13, 14].

The present study aimed to investigate the performance of MRI and/or gross examination of specimen in detecting cervical invasion and factors that may influence MRI's performance.

Materials and Methods

Patients diagnosed with endometrial cancer and treated by surgery in the Prince of Wales Hospital in Hong Kong from January 2007 to November 2014 were identified retrospectively. Those with pre-operative MRI performed for cervical invasion were included in the study. The patient's records were reviewed to retrieve the demographic data and operative, MRI, and pathological findings. The standard surgical treatment for endometrial cancer included hysterectomy and bilateral salpingo-oophorectomy. Radical hysterectomy was performed if cervical invasion was suspected on pre-operative assessment. Pelvic or para-aortic lymphadenectomy may be also be performed after taking into consideration the surgical risk of the patient, tumour grade, histological type, disease stage, suspicious lymph node, and depth of myometrial invasion, as determined by preoperative MRI and intra-operative examination. Majority of the MRIs performed in the present study patients were done in six service-based MRI centres using different machine and imaging protocol. Intraoperative gross assessment of specimen for cervical invasion was performed by gynae-oncologists. All surgical specimens were sent for pathological examination after completion of surgery and the pathological findings were used as the gold standard.

MRI techniques

Center A: all MRI examinations were performed with a 3T machine. Axial images were obtained with T1 turbo spin echo (TSE), T2 TSE, T1 TSE fat saturation (FS), and gradient echo (GE) sequences. Sagittal image was obtained with T2 TSE blade sequence. Coronal image was obtained with T2 TSE short tau inversion recovery (STIR) sequence. T1 TSE blade sequence was applied perpendicular to the tumor. Post-contrast axial, coronal, and sagittal images were obtained with T1 TSE FS sequence.

Center B: MRIs were performed mainly by 3T machine. Axial images were obtained with T1 TSE and T2 TSE FS sequences. Sagittal image was obtained with T2 TSE FS sequence. Coronal image was obtained with T2 half-fourier acquisition single-shot turbo spin-echo (HASTE) and T2 3D sampling perfection with application optimized contrasts using different flip angle evolution (SPACE) sequences. Post-contrast axial image was obtained by T1 TSE FS sequence. Post-contrast coronal image was obtained with 3D gradient recalled echo sequence (GRE). Dynamic study with T1 3D GRE sequence was performed.

Center C: MRIs were performed mainly by a 3T scanner. Axial images were obtained mainly with T1, T2, and T2 FS sequences. Sagittal image was obtained with T2 sequence. Coronal image was obtained with T2 sequence. Post-contrast sagittal, oblique axial, and axial images were obtained with enhanced T1 high resolution isotropic volume excitation (eTHRIVE) sequence.

Center D: MRIs were performed by either 1.5T or 3T machines. Axial images were obtained with T1 TSE, T2 TSE, T2 FS, and T2 GE sequences. Sagittal image was obtained with T2 TSE sequence. Coronal image was obtained with T2 FS sequence. Post-contrast axial, sagittal, and coronal images were obtained with T1 FS sequence.

Table 1. — *Patient characteristics.*

		Number of patients	Percentage
Age, years (n=318)	< 30	1/318	0.3%
	30-39	11/318	3%
	40-49	45/318	14%
	50-59	172/318	55%
	60-69	59/318	19%
	≥ 70	30/318	9%
Mean age: 56, median age: 55			
Parity (n=279)	0	66/279	24%
	1	50/279	18%
	2	94/279	33%
	3	40/279	14%
	4	10/279	4%
	5	10/279	4%
	>5	9/279	3%
Missing data = 39			
Stage of endometrial cancer (n=318)	1A	201/318	63%
	1B	42/318	13%
	II	33/318	10%
	III to IV	42/318	13%
Histology (n=318)	Endometrioid	284/318	90%
	Serous adenocarcinoma	5/318	1.6%
	Clear cell carcinoma	5/318	1.6%
	Undifferentiated adenocarcinoma	4/318	1.3%
	Others	20/318	6.3%
Grade of Tumor	Grade 1	172/294	58.5%
	Grade 2	83/294	28.2%
	Grade 3	39/294	13.2%
Menopause	206/318	65%	
Presence of adenomyosis		43/318	13.5%
Presence of fibroids		14/318	44%
Time between MRI and surgery (days)			
	≤ 10 days	156/313	49.8%
	11 to ≤ 20 days	113/313	36.1%
	> 20 days	44/313	14.1%

Center E: MRIs were performed by either 1.5T or 3T machines. Axial images were obtained with T1 GE, T2 TSE, T1 GE, T1 GE FS, T2 HASTE, and T2 HASTE FS sequences. Sagittal image was obtained with T2 TSE sequence. Coronal images were obtained with T2 TSE and T2 HASTE sequences. Post-magnetvist or dotarem contrast sagittal, coronal, and axial images were obtained by T1 GE FS sequence.

Center F did not reply to the present enquiry on MRI technique: The accuracy, sensitivity, specificity, positive predictive value (PPV), negative predictive value (NPV), positive likelihood ratio (PLR), and negative likelihood ratio (NLR) of MRI in detecting cervical invasion were determined for the entire study population as well as for each of the six MRI service centres. Similarly, the performances of intra-operative gross examination of specimen in detecting cervical invasion alone and in combination with MRI were also determined.

Chi square test was used to compare categorical variables. T-test was used to compare continuous with categorical variables. Receiver operating curve (ROC) for MRI, intra-operative gross ex-

Table 2. — *MRI findings versus final histology and MRI performance in diagnosing cervical invasion.*

		Cervical invasion present on MRI	Cervical invasion absent on MRI	Accuracy	Sensitivity	Specificity	PPV	NPV	PLR	NLR
Overall (n=318)	Pathology: cervical invasion present	n=24	n=26	86.5% (275/ 318)	48% (95% CI: 33.7% to 62.6%)	93.7% (95% CI: 90% to 96.3%)	58.5% (95% CI: 42.1% to 73.7%)	90.6% (95% CI: 86.6% to 93.8%)	7.57 (95% CI: 4.4 to 13.02)	0.56 (95% CI: 0.42 to 0.73)
	Pathology: cervical invasion absent	n=17	n=251							
Center A (n=140)	Pathology: cervical invasion present	n=15	n=11	86.4% (121/140)	57.7% (95% CI: 36.9% to 76.6%)	93% (95% CI: 86.6% to 96.9%)	65.2% (95% CI: 42.7% to 83.6%)	90.6% (95% CI: 83.8% to 95.2%)	8.22 (95% CI: 3.9 to 17.32)	0.46 (95% CI: 0.29 to 0.71)
	Pathology: cervical invasion absent	n=8	n=106							
Center B (n=62)	Pathology: cervical invasion present	n=2	n=4	88.7% (55/62)	33.3% (95% CI: 5.33% to 77.32%)	94.6% (95% CI: 85.1% to 98.8%)	40% (95% CI: 6.49% to 84.6%)	93% (95% CI: 83% to 98%)	6.22 (95% CI: 1.28 to 30.17)	0.7 (95% CI: 0.4 to 1.24)
	Pathology: cervical invasion absent	n=3	n=53							
Center C (n=53)	Pathology: cervical invasion present	n=2	n=1	98.1% (52/53)	66.7% (95% CI: 11.6% to 94.5%)	100% (95% CI: 92.8% to 100%)	100% (95% CI: 19.3% to 100%)	98% (95% CI: 89.5% to 99.7%)	-	0.33 (95% CI: 0.07 to 1.65)
	Pathology: cervical invasion absent	n=0	n=50							
Center D (n=21)	Pathology: cervical invasion present	n=3	n=3	76.2% (16/21)	50% (95% CI: 12.4% to 87.6%)	86.7% (95% CI: 59.5% to 98%)	60% (95% CI: 15.4% to 93.5%)	81.25% (95% CI: 54.4% to 95.7%)	3.75 (95% CI: 0.82 to 17.12)	0.58 (95% CI: 0.25 to 1.32)
	Pathology: cervical invasion absent	n=2	n=13							
Center E (n=11)	Pathology: cervical invasion present	n=0	n=23	54.5% (6/11)	0% (95% CI: 0% to 69.5%)	75% (95% CI: 35.1% to 96.1%)	0% (95% CI: 0% to 80.7%)	66.7% (95% CI: 30.1% to 92.1%)	0	1.33 (95% CI: 0.89 to 1.99)
	Pathology: cervical invasion absent	n=2	n=6							
Center F (n=12)	Pathology: cervical invasion present	n=1	n=2	66.7% (9/12)	33.33% (95% CI: 5.5% to 88.5%)	100% (95% CI: 66.2% to 100%)	100% (95% CI: 16.6% to 100%)	81.8% (95% CI: 48.2% to 97.2%)	-	0.67 (95% CI: 0.3 to 1.48)
	Pathology: cervical invasion absent	n=0	n=9							

PPV: positive predictive value, NPV: negative predictive value, PLR: positive likelihood ratio, NLR: negative likelihood ratio.

amination of specimen and combined assessment with MRI and gross examination of specimen were drawn. Analyses were performed with the Statistical Package for Social Science version 22.0. The significance level was set at $p < 0.05$. The study was approved by the local institutional ethics committee (CRE Ref: No. 2013.439_ER).

Results

A total of 367 endometrial cancer patients with pre-operative MRI performed were identified. Among them, 318 patients were included in the study and 49 cases were excluded because cervical invasion was not commented. The age of the patients ranged from 27 to 89 years and the median age was 55 years. Sixty-five percent of patients had reached menopause. Ten percent of patients had pathological Stage 2 disease. Endometrioid type accounted for 90% and 58.5% were Grade 1 tumors. Fibroid was present in 44% of cases and adenomyosis was present in 13.5% of cases. Surgery was performed within 20 days after MRI in 86% of cases (Table 1).

Two hundred and ninety-nine contrasted MRIs were performed in six service-base centres (Centres A, B, C, D, E, and F) and the remaining 19 MRIs were performed in other centres (Table 2). The overall accuracy of MRI in detecting cervical invasion was 86.5%. MRI over-diagnosed cervical invasion in 17 cases and under-diagnosed cervical invasion in 26 cases. The sensitivity, specificity, PPV, NPV, PLR, and NLR were 48%, 93.7%, 58.5%, 90.6%, 7.57, and 0.56, respectively (Table 2). The ROC of MRI in diagnosing cervical invasion is shown in Figure 1 and the area under the curve (AUC) was 0.71 (95% CI 0.62 to 0.80). The accuracy, sensitivity, specificity, PPV, NPV, PLR, and NLR of each of the six centres were also calculated and depicted in Table 2.

Presence of lymphovascular space invasion (LVSI) was associated with decreased accuracy of MRI in detecting cervical invasion (88.3% *vs*. 75.5%, $p = 0.04$). Caseload of centre, number of days between MRI and surgery, age, menopausal status, presence of fibroid, adenomyosis, grade of tumour, and histology of tumour (endometrioid

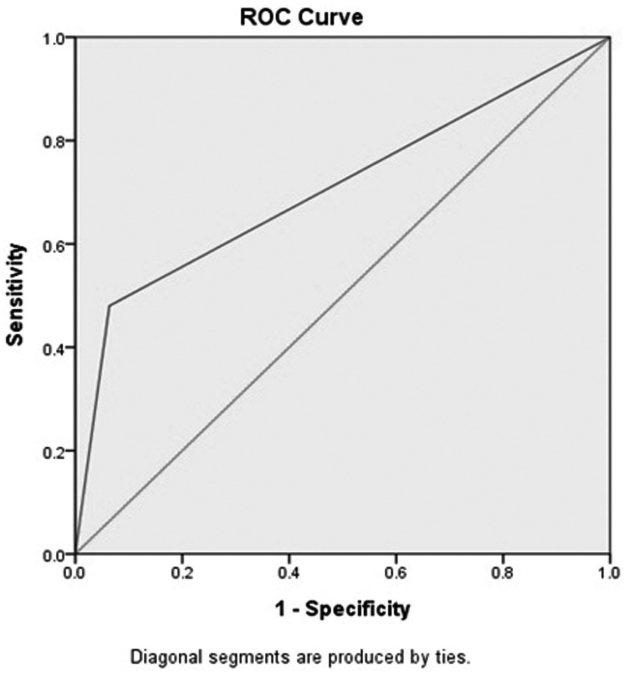

Figure 1. — ROC curve of MRI in diagnosing cervical invasion.

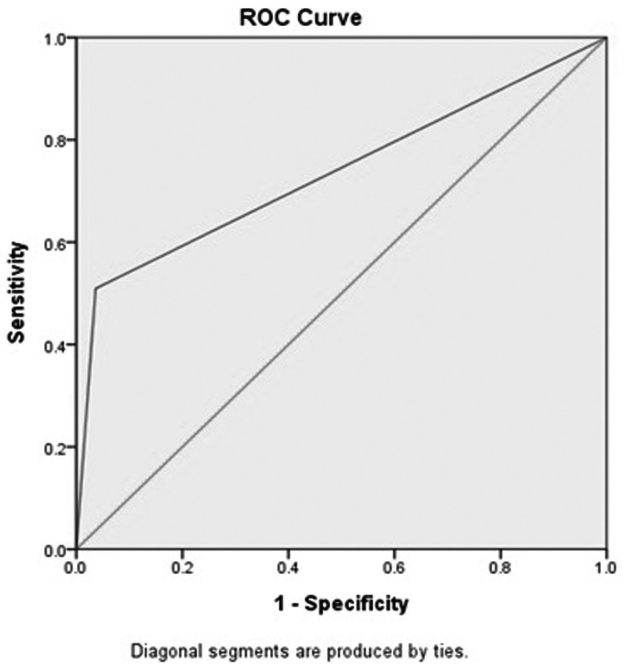

Figure 2. — ROC curve of intra-operative gross examination of specimen in diagnosing cervical invasion.

Table 3. — *Factors affecting performance of MRI in diagnosing cervical invasion.*

	Accurate	Inaccurate	*p*-value
Number of days between MRI and surgery (n=313)			
≤ 20 days	235/269 (87.4%)	34/269 (12.6%)	0.72
> 20 days	37/44 (84.1%)	7/44 (15.9%)	
Center case load (n=255)			
> 100 cases	121/140 (86.4%)	19/140 (13.6%)	0.13
50 to 100 cases	107/115 (93%)	8/115 (7%)	
Menopausal status (n=318)			
Menopause	182/206 (88.3%)	24/206 (11.7%)	0.25
Not menopause	93/112 (83%)	19/112 (17%)	
Fibroid (n=318)			
Present	119/140 (85%)	21/140 (15%)	0.6
Absent	156/178(87.6%)	22/178 (12.4%)	
Adenomyosis (n=318)			
Present	38/43 (90.7%)	4/43 (9.3%)	0.53
Absent	236/275 (85.8%)	39/275 (14.2%)	
Lymphovascular space invasion (n=233)			
Present	40/53 (75.5%)	13/53 (24.5%)	0.04*
Absent	159/180 (88.3%)	21/180 (11.7%)	
Histology of tumor (n=318)			
Endometrioid	248/284 (87.3%)	36/284 (12.7%)	0.31
Non-endometrioid	27/34 (79.4%)	7/34 (20.6%)	
Grade of tumor (n=294)			
Grade 1	153/172 (89%)	19/172 (11%)	0.2
Grade 2	70/83 (84.3%)	13/83 (15.7%)	
Grade 3	31/39 (79.5%)	8/39 (20.5%)	
Age, years	Mean 56.2 (SD: 9.51)	Mean 54.7 (SD: 8.47)	0.31

*Statistically significant.

vs. non-endometrioid) did not have any significant effect on the performance of MRI (Table 3).

Among the 367 cases, 356 cases had cervical invasion assessed clinically after hysterectomy. The accuracy of gross examination of specimen for cervical invasion was 89.6%. Gross examination over-diagnosed 11 cases and under-diagnosed 26 cases. The sensitivity, specificity, PPV, NPV, PLR, and NLR were 51.9%, 96.4%, 71.8%, 91.8%, 14.2, and 0.5 respectively (Table 4). The ROC of gross examination of specimen in diagnosing cervical invasion is shown in Figure 2 and the AUC was 0.74 (95% CI 0.65 to 0.82).

Among the 14 cases classified as having cervical invasion on MRI, but with no cervical invasion on gross examination, 12 actually had no cervical invasion on final pathology. Among ten cases with cervical invasion on gross examination of specimen but no invasion on MRI, six actually had no cervical invasion on final pathology. When combining the use of MRI with gross examination and adopting positive finding when either assessment was positive for cervical invasion, the accuracy dropped to 85.8% but the sensitivity increased to 56.3%. The specificity, PPV, NPV, PLR, and NLR was 91.2%, 54%, 91.9%, 6.38, and 0.48, respectively (Table 5). The ROC for combined assessment with MRI and gross examination of specimen in diagnosing cervical invasion is shown in Figure 3 and the AUC was 0.74 (95% CI 0.65 to 0.83).

Table 4. — *Performance of gross examination of specimen in diagnosing cervical invasion.*

		Cervical invasion present clinically	Cervical invasion absent clinically	Accuracy	Sensitivity	Specificity	PPV	NPV	PLR	NLR
Gross examination of specimen (n=356)	Pathology: cervical invasion present	n=28	n=26	89.6% (319/356)	51.9% (95% CI: 37.8% to 65.7%)	96.4% (95% CI: 93.6% to 98.2%)	71.8% (95% CI: 55.1% to 85%)	91.8% (95% CI: 88.2% to 94.6%)	14.2 (95% CI: 7.55 to 26.85)	0.5 (95% CI: 0.38 to 0.66)
	Pathology: cervical invasion absent	n=11	n=291							

Table 5. — *performance of combining MRI and gross examination of specimen in diagnosing cervical invasion.*

		Cervical invasion present	Cervical invasion absent	Accuracy	Sensitivity	Specificity	PPV	NPV	PLR	NLR
Combine MRI with gross examination of specimen (n=309)	Pathology: cervical invasion present	n=27	n=21	85.8% (265/309)	56.3% (95% CI: 41.2% to 70.5%)	91.2% (95% CI: 87.1% to 94.3%)	54% (95% CI: 39.3% to 68.2%)	91.9% (95% CI: 87.9% to 94.9%)	6.38 (95% CI: 4.02 to 10.14)	0.48 (95% CI: 0.35 to 0.66)
	Pathology: cervical invasion absent	n=23	n=238							

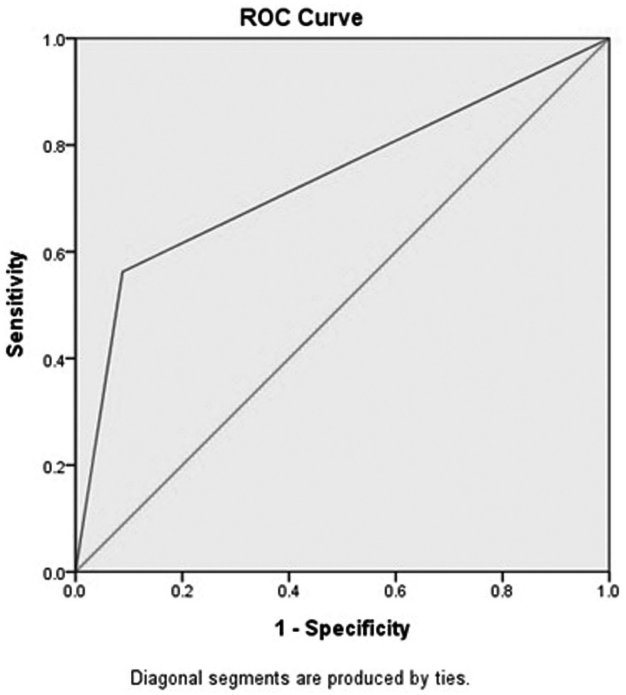

Figure 3. — ROC curve of combined assessment with MRI and gross examination of specimen in diagnosing cervical invasion.

Discussion

Pre-operative assessment of cervical invasion is important for surgical planning of endometrial cancer so that less aggressive surgical treatment can be offered to early stage disease patients, while gynae-oncologists could be involved if radical surgery and extensive lymphadenectomy are indicated.

MRI is superior to CT that has a sensitivity of only 25% in detecting cervical stromal invasion [15]. Studies have shown that TVS and MRI had comparable performance in assessing cervical stromal invasion [11, 16]. In a prospective study with 64 cases comparing MRI and TVS, the accuracy and sensitivity of TVS in diagnosing cervical invasion was 91% and 88%, respectively, while for MRI it was 92% and 88%, respectively [11]. TVS has an advantage of lower cost and being more readily available. However, it is operator dependent and does not provide information on lymph node and distant metastasis.

MRI has been increasingly used in pre-operative assessment of endometrial cancer with a ten-fold increase in use in the past ten years [9]. The sensitivity of MRI in detecting cervical invasion varies in different reports because different machines, study protocols, and expertise were involved [17]. The published sensitivity of MRI varies greatly from 33% to 88%, signifying that even in experienced hands, the sensitivity of MRI in detecting cervical invasion may be low.

The present study focused on assessing the performance of MRI in local service-base centres. The authors found a high accuracy of 85.8% but a low sensitivity of 48% and these figures are comparable to published data. The area under the curve is 0.71, indicating that MRI is only a fair test for detection of cervical invasion. MRI over-diagnosed cervical invasion in 17 cases (5.4%) and under-diagnosed cervical invasion in 26 cases (8.1%). Low sensitivity is undesirable because Stage 2 endometrial cancer patients missed by a MRI might not be attended by gynae-oncologist and sub-optimal surgical treatment

may compromise the treatment outcome.

The present finding of high specificity of 94% and high NPV of 91% in detecting cervical invasion is consistent with previous studies [11, 12, 18, 19]. Therefore if MRI showed absence of cervical invasion, it is highly likely that the patient does not have cervical invasion and radical surgery might not be indicated.

The present authors did not find menopausal status, age, stage, grade of tumour, histology of tumour, presence of fibroid, adenomyosis, centre case load, and number of days between MRI and surgery to have significant impact on the performance of MRI. The only significant factor that affected accuracy of MRI was LVSI and presence of LVSI was associated with lower accuracy of MRI. Unfortunately, the presence of LVSI could not be diagnosed preoperatively to warn the surgeon of the limitation of a negative MRI finding.

A recently published randomized controlled trial (RCT) commented that PET-CT is the best imaging modality in detecting cervical invasion by endometrial cancer [20]. The trial included 318 patients randomized to MRI, PET-CT, and TVS to investigate for cervical invasion. The sensitivity of PET-CT, MRI, and TVS was 43%, 33%, and 29%, respectively. Although PET-CT was commented to have the highest sensitivity, it is actually lower than that in the present study (43% *vs*. 48%). These results showed that until now, there is no effective imaging modality to accurately diagnose cervical invasion by endometrial cancer. Further improvements in imaging technique are required.

Published studies showed that all currently available imaging modalities have unsatisfactory performance. Other than imaging studies, diagnostic hysteroscopy has also been used to assess cervical invasion pre-operatively. A prospective study comparing the performance of hysteroscopy, MRI, and TVS in diagnosing cervical invasion by endometrial carcinoma has been recently published [21]. Hysteroscopic diagnosis of cervical involvement was made if the tumour borders reached the internal cervical ostium. Biopsies were taken from the tumour site, tumour border, and from the internal cervical os to ectocervix to investigate for cervical invasion. The study included 156 patients and hysteroscopic cervical biopsy was found to have a statistically significant higher accuracy rate (95%) than MRI (84%) and TVS (80%). The sensitivity of hysteroscopy of 73% was also higher than that of MRI (54%) and TVS (38%), but the difference was not statistically significant. However, the potential risk of intra-peritoneal dissemination of endometrial cancer cells during hysteroscopy is a concern as a meta-analysis had shown a higher rate of positive peritoneal cytology among those with hysteroscopy before definitive surgical treatment [22, 23].

Intra-operative frozen section has been shown to have a high accuracy and sensitivity in detecting cervical involvement by endometrial carcinoma and is useful in guiding the decision of lymph node dissection. The accuracy ranges from 93% to 95 % and the sensitivity ranges from 70% to 94%. [11, 24]. The false negative rate of intra-operative frozen section had been shown to be lower than MRI in a study with 122 patients (4.9% *vs*. 10.7%) [17]. The limitation of frozen section is that the assessment cannot be made before hysterectomy was performed and patients with Stage 2 endometrial cancer could not be benefited by radical hysterectomy [7]. Furthermore, quality frozen section service to provide quick and accurate assessment is not available in many hospitals.

While intra-operative frozen section is not always available, intra-operative gross examination of the uterine specimen can be readily performed. A previous study had found an accuracy of 98.5% and sensitivity of 88.5% of gross examination of specimens in detecting cervical invasion [13]. The present study found an accuracy of 90% and but a lower sensitivity of 52%. The AUC was 0.74 which is comparable to MRI. Both the sensitivity and AUC of intra-operative gross assessment of specimens are higher than MRI in the present study. Therefore intra-operative gross examination of the uterine specimen should be encouraged so that Stage 2 endometrial cancer can be diagnosed and lymph node dissection would not be omitted inadvertently because cervical invasion was not picked up in pre-operative assessment. Combining both MRI and gross examination of specimen increases the sensitivity further to 56%. Achieving a higher sensitivity at the expense of a lower specificity is acceptable because omission of lymphadenectomy in a Stage 2 patient is undesirable and postoperative radiotherapy may become necessary.

The present study had an advantage of being a single study with a large sample size. The present limitations include a retrospective design which may cause selection bias. For example some high stage cases may not have MRI performed because surgery is not planned. Both surgeons and pathologists were not blind to the imaging results and interpretation may be affected by the imaging result.

Conclusion

MRI performed in service-base centre has comparable performance to published data in diagnosing cervical invasion by endometrial cancer. The accuracy is high but the sensitivity is unsatisfactory. MRI cannot be recommended as a sole assessment method for cervical invasion by endometrial cancer because of low sensitivity. Higher sensitivity can be achieved when it is used in combination with gross examination of the uterine specimen.

References

[1] Howlader N., Noone A.M., Krapcho M., Garshell J., Miller D., Altekruse S.F., *et al.*: "SEER Cancer Statistics Review, 1975-2011, National Cancer Institute. Bethesda, MD, based on November 2013 SEER data submission, posted to the SEER web site, April 2014. Available at: http://seer.cancer.gov/csr/1975_2011/browse_csr.php?sectionSEL=7&pageSEL=sect_07_table.05.html

[2] Hong Kong Cancer Registry, Hospital Authority: "Cancer statistics, 1998-2012". Available at: http://www3.ha.org.hk/cancereg/corpus_2012.pdf

[3] Kang W.D., Kim C.H., Cho M.K., Kim J.W., Kim Y.H., Choi H.S., Kim S.M.: "Lymphadenectomy for low-risk endometrial cancer based on preoperative and intraoperative assessments". *Int. J. Gynecol. Cancer*, 2009, *19*, 657.

[4] Mariani A., Webb M.J., Keeney G.L., Haddock M.G., Calori G., Podratz K.C.: "Low-risk corpus cancer: is lymphadenectomy or radiotherapy necessary?". *Am. J. Obstet. Gynecol.*, 2000, *182*, 1506.

[5] Creasman W.T., Odicino F., Maisonneuve P., Quinn M.A., Beller U., Benedet J.L., *et al.*: "Carcinoma of the corpus uteri. FIGO 26th Annual Report on the Results of Treatment in Gynecological Cancer". *Int. J. Gynaecol. Obstet*., 2006, *95*, S105.

[6] Creasman W.T., Morrow C.P., Bundy B.N., Homesley H.D., Graham J.E., Heller P.B., *et al.*: "Surgical pathologic spread patterns of endometrial cancer: A gynecologic oncology group study". *Cancer*, 1987, *60*, 2035.

[7] Cornelison T.L., Trimble E.L., Kosary C.L.: "SEER data, corpus uteri cancer: treatment trends versus survival for FIGO stage II, 1988-1994". *Gynecol. Oncol*., 1999, *74*, 350.

[8] Cohn D.E., Woeste E.M., Cacchio S., Zanagnolo V.L., Havrilesky L.J., Mariani A., *et al.*: "Clinical and pathologic correlates in surgical stage II endometrial carcinoma". *Obstet. Gynecol*., 2007, *109*, 1062.

[9] Gien L.T., Barbera L., Kupets R., Saskin R., Paszat L.: "Utilization of preoperative imaging in uterine cancer patients". *Gynecol. Oncol*., 2009, *115*, 226.

[10] Tong T., Yajia G., Huaying W., Weijun P.: "Application of 1.5 T magnetic resonance imaging in endometrial cancer". *Arch. Gynecol. Obstet*., 2012, *285*, 1113.

[11] Celik C., Ozdemir S., Kiresi D., Emlik D., Tazegül A., Esen H.: "Evaluation of cervical involvement in endometrial cancer by transvaginal sonography, magnetic resonance imaging and frozen section". *J. Obstet. Gynaecol*., 2010, *30*, 302.

[12] Cunha T.M., Félix A., Cabral I.: "Preoperative assessment of deep myometrial and cervical invasion in endometrial carcinoma: comparison of magnetic resonance imaging and gross visual inspection". *Int. J. Gynecol. Cancer,* 2001, *11*, 130-6.

[13] Vorgias G., Hintipas E., Katsoulis M., Kalinoglou N., Dertimas B., Akrivos T.: "Intraoperative gross examination of myometrial invasion and cervical infiltration in patients with endometrial cancer: decision-making accuracy". *Gynecol. Oncol.*, 2002, *85*, 483.

[14] Sethasathien P., Charoenkwan K., Siriaunkgul S.: "Accuracy of intraoperative gross examination of myometrial invasion in stage I-II endometrial cancer". *Asian Pac. J. Cancer Prev.*, 2014, *15*, 7061.

[15] Hardesty L.A., Sumkin J.H., Hakim C., Johns C., Nath M.: "The ability of helical CT to preoperatively stage endometrial carcinoma". *AJR Am. J. Roentgenol.*, 2001, *176*, 603.

[16] Savelli L., Ceccarini M., Ludovisi M., Fruscella E., De Iaco P.A., Salizzoni E., *et al.*: "Preoperative local staging of endometrial cancer: transvaginal sonography vs. magnetic resonance imaging". *Ultrasound Obstet. Gynecol.*, 2008, *31*, 560.

[17] Haldorsen I.S., Husby J.A., Werner H.M., Magnussen I.J., Rørvik J., Helland H., *et al.*: "Standard 1.5-T MRI of endometrial carcinomas: modest agreement between radiologists". *Eur. Radiol.*, 2012, *22*, 1601.

[18] Nagar H., Dobbs S., McClelland H.R., Price J., McCluggage W.G., Grey A.: "The diagnostic accuracy of magnetic resonance imaging in detecting cervical involvement in endometrial cancer". *Gynecol. Oncol.*, 2006, *103*, 431.

[19] Sanjuán A., Escaramís G., Ayuso J.R., Román S.M., Torné A., Ordi J., *et al.*: "Role of magnetic resonance imaging and cause of pitfalls in detecting myometrial invasion and cervical involvement in endometrial cancer". *Arch Gynecol Obstet.*, 2008, *278*, 535.

[20] Antonsen S.L., Jensen L.N., Loft A., Berthelsen A.K., Costa J., Tabor A., *et al.*: "MRI, PET/CT and ultrasound in the preoperative staging of endometrial cancer - a multicenter prospective comparative study". *Gynecol. Oncol*., 2013, *128*, 300.

[21] Ørtoft G., Dueholm M., Mathiesen O., Hansen E.S., Lundorf E., Møller C., *et al.*: "Preoperative staging of endometrial cancer using TVS, MRI, and hysteroscopy". *Acta Obstet. Gynecol. Scand*., 2013, *92*, 536.

[22] Polyzos N.P., Mauri D., Tsioras S., Messini C.I., Valachis A., Messinis I.E.: "Intraperitoneal dissemination of endometrial cancer cells after hysteroscopy: a systematic review and meta-analysis". *Int. J. Gynecol. Cancer*, 2010, *20*, 261.

[23] Chang Y.N., Zhang Y., Wang Y.J., Wang L.P., Duan H.: "Effect of hysteroscopy on the peritoneal dissemination of endometrial cancer cells: a meta-analysis". *Fertil. Steril*., 2011, *96*, 957.

[24] Hahn H.S., Song H.S., Lee I.H., Kim T.J., Lee K.H., Shim J.U., *et al.*: "Magnetic resonance imaging and intraoperative frozen sectioning for the evaluation of risk factors associated with lymph node metastasis in endometrial cancer". *Int. J. Gynecol. Cancer*, 2013, *23*, 1411.

Corresponding Author:
J.H.S. LEE, M.D.
Department of Obstetrics & Gynaecology
Prince of Wales Hospital
30-32 Ngan Shing Street, Shatin
New Territories, Hong Kong
(China)
e-mail: jaclee@cuhk.edu.hk