EJGO European Journal of Gynaecological Oncology

# Predicting malignancy in breast nodules using the SONOBREAST

**L. F. Pádua Oliveira[1], R. Resende Paulinelli[1], L. Ribeiro Soares[1], R. Freitas-Junior[1,2]**

[1]*Federal University of Goiás, Goiânia, Goiás*
[2] *Hospital Araújo Jorge of the Associação de Combate ao Câncer de Goiás (ACCG), Goiânia, Goiás*
*This study was conducted by the Goiânia Mastology Research Network, Goiânia, Goiás (Brazil)*

**Summary**

*Objective:* The objective of this study was to validate the SONOBREAST statistical model in women at a private clinic with a different epidemiological profile from those in the initial study. *Materials and Methods:* This is a study to evaluate the performance of a diagnostic test (SONOBREAST) and evaluated 500 breast nodules identified on ultrasonography. Surgery was indicated in all cases. The ultrasonographic characteristics, patients' age, and family history of breast cancer were analyzed. The probability of malignancy was calculated according to the SONOBREAST model (www.sonobreast.com.br). The results were compared with the pathology findings. *Results:* A total of 274 women with a mean age of 41.92 ± 14.40 years were included. Overall, 86 (17.2%) tumors were malignant and 414 (82.8%) were benign, with 382 (76.4%) being non-palpable. The mean size of the lesions was 16.34 ± 8.73 mm. The sensitivity of SONOBREAST was 95.40%, specificity 78.69%, and accuracy 81.60%, with a positive predictive value (PPV) of 48.54% and a negative predictive value (NPV) of 98.78%. *Conclusion:* This study validates the use of SONOBREAST to evaluate the probability of malignancy in solid breast nodules identified on ultrasonography in women consulting at a private clinic.

*Key words:* Breast cancer; Diagnosis; Ultrasonography; Sensitivity and specificity; Predictive value of tests.

## Introduction

One of the classic indications for breast ultrasonography is to differentiate between solid and cystic lesions, with this indication contributing towards consolidating this diagnostic method in clinical practice [1]. Nevertheless, differentiating between benign and malignant solid lesions remains controversial, thus motivating investigators to conduct studies on the predictive capacity of each echographic characteristic [2-4].

SONOBREAST is a predictive model of malignancy for solid breast nodules that was created based on a multivariate analysis of 1,403 nodules seen at breast ultrasonography [3]. A computer program freely available on the internet is used to provide an estimate of individual risk in the form of a percentage [3].

Although the sensitivity, specificity, and accuracy of SONOBREAST have already been reported [3], the majority of the women included in that original study were clients of the public healthcare service, with palpable nodes and difficulties in accessing specialized healthcare services [5-7].

The objective of the present study was to validate the SONOBREAST model in women from a private clinic with a different epidemiological profile from that of the women in the initial study.

## Materials and Methods

This was a study to evaluate the performance of a diagnostic test and was conducted to evaluate a sample of 500 solid nodules in 274 women attending a private clinic in Goiânia, Goiás (Brazil). Surgery was indicated in all cases due to the size of the nodule, tumor growth or its appearance on mammograms, among other indications. Solid lesions associated with skin ulceration and cystic lesions were not included in this study.

All the exams were conducted between January 2010 and July 2012 by the same examiner, a specialist with more than ten years' experience in breast ultrasonography. A high-resolution scanner coupled to a 7.0-12.0 MHz linear-array real-time transducer was used.

The sample size was defined on the basis of the result from previous studies conducted within the Senology program at the Teaching Hospital of the Federal University of Goiás [2, 3]. This was defined by statistical calculation, considering an increase of at least 10% in the prevalence of malignancy in each group of nodules when no abnormal ultrasonographic features were present and when one, two, or three abnormal features were found. Based on the aforementioned criteria, sample size was defined as a minimum of 240 patients. The power of the test was defined as a probability of 80% for the detection of the aforementioned difference between the groups, with significance level established at 5%. More patients than predicted were included to increase the reliability of the analysis.

The variables used to calculate the probability of malignancy were the patient's age and her first-degree family history of breast cancer (mother, sister or daughter) associated with the morphological characteristics of the tumor visualized on ultrasonography

Revised manuscript accepted for publication December 15, 2016



7847050 Canada Inc.
www.irog.net

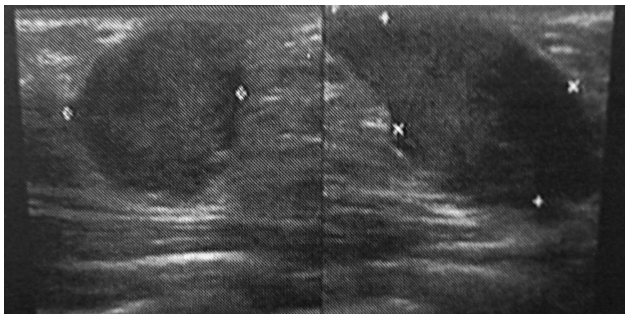

Figure 1. — This palpable nodule (2.7cm) has an irregular shape, heterogeneous echotexture, and horizontal orientation, without echogenic halo or posterior shadowing. The patient is 21 years old, without any family history, and the probability of malignancy estimated by the model was 39.1%. In the BI-RADS system, it would be in category 4, with an expected 3% to 94% probability of breast cancer. The biopsy revealed fibromatosis of the breast (immunohistochemistry).

(irregular shape, heterogeneous echotexture, posterior acoustic shadowing, echogenic halo, and vertical orientation) [2, 3] (Figure 1). In the original study, the authors attempted to include the mass size and its palpability, but these characteristics were excluded because they did not improve the accuracy of the model and lost their significance in the multivariate analysis [3].

The probability of malignancy was calculated using the SONOBREAST statistical model, available at the following website: www.sonobreast.com.br. A lesion was considered suspect when the risk of malignancy was above 2%, which is in line with that established for the American College of Radiology (ACR)'s Breast Imaging Reporting and Data System (BI-RADS).[8]

The accuracy, sensitivity, specificity, positive predictive value (PPV), and negative predictive value (NPV) were calculated according to the pathology results. The sensitivity was calculated as follows: true positive (TP)/[TP + false negative (FN)]; and the specificity was calculated as follows: true negative (TN)/[TN + false positive (FP)]. The PPV relates the TP/(TP + FP) while the NPV relates TN/(TN + FN). Next, accuracy was calculated once again using the Receiver Operator Characteristic (ROC) curve for the continuous probability values for malignancy with the SONOBREAST system.

The patients' clinical characteristics and the ultrasonographic features of the nodules were compared with the pathology findings using univariate analysis with the chi-square test. The odds ratios were calculated with a 95% confidence interval. The multivariate logistic regression was not performed because the number of positive events for some of the characteristics was insufficient for a reliable result. The Mann-Whitney U test was used for all the numerical variables, since distribution was non-normal according to the Kolmogorov-Smirnov test. The SPSS statistical software package, version 11.0.1 was used to conduct the statistical analysis.

The internal review board of the Federal University of Goiás' Teaching Hospital approved the study. It was conducted under the principles of the Helsinki Declaration. The patients were briefed on the nature of the research and agreed to participate in the study by reading and signing an informed consent form.

## Results

The mean age of the patients was 41.9 ± 14.4 years (SD). The median age of the patients with benign tumors was 39.00 (range 29.0-47.0) years, compared to 56.00 (range 48.0-64.0) years for the group of women with malignant tumors ($p < 0.01$). The median size of the benign lesions was 13.00 (range 9.95-17.85) mm compared to 20.2 (range 14.40-27.90) mm in the case of the malignant tumors ($p < 0.01$).

Overall, 382 of the nodules (76.4%) were classified as non-palpable. At pathology, 414 (82.8%) were found to be benign, including 303 (60.6%) fibroadenomas and 84 (16.8%) fibroadenosis. There were 86 cases of malignant tumors (17.2%), with 65 cases of invasive ductal carcinoma (13.0%) and six cases of invasive lobular carcinoma (1.2%).

According to SONOBREAST, the lesions were considered suspect in 171 cases (34.2%). The odds ratios for malignancy in accordance with the characteristics of the model included in the univariate analysis are shown in Table 1. For a cut-off point of 2% for a suspicion of malignancy, which is in line with that used in the BI-RADS, the sensitivity of the SONOBREAST model was 95.40%, with specificity of 78.69% and accuracy of 81.60%. The PPV was 48.54% and the NPV value was 98.78%. Considering the probability of malignancy as a continuous variable, the area under the ROC curve was 0.94 (0.92–0.97).

## Discussion

The use of breast ultrasonography is based on knowledge of the normal anatomical structure, of the variants of normality, and of the various features present in breast pathology [9]. Currently, abnormal images are evaluated and defined in accordance with their morphological characteristics [1, 10, 11]. Nevertheless, using an association of morphological features and clinical characteristics is interesting, since it creates sub-groups at a higher risk and with a greater prevalence of malignancy, which may help the attending physician define a more individualized approach.

The SONOBREAST model was developed following a prospective, multicenter study in which 1,043 breast lesions seen on ultrasonography were evaluated [3]. The use of multivariate analysis enabled a statistical model to be developed that calculated the probability of malignancy in these lesions with precision and objectivity. In that model, the most relevant morphological characteristics were taken into consideration as well as certain clinical data, such as the patient's age and family history of malignancy [3]. Although the present study also takes a family history of breast cancer into consideration, in this population sample, unlike the original study, that variable failed to reach statistical significance. This may have been a consequence of

Table 1. — *Odds ratios (OR) for malignancy according to the characteristics used in the SONOBREAST model in the univariate analysis.*

| | Malignant | Benign | OR (95%CI) | *p*-value |
|---|---|---|---|---|
| | n (%) | n (%) | | |
| Irregular/poorly circumscribed tumors | 80 (91.95%) | 76 (18.40%) | 50.58 (22.51−114.10) | < 0.01 |
| Heterogeneous echotexture | 74 (85.06%) | 64 (15.50%) | 31.04 (16.26−59.27) | < 0.01 |
| Posterior shadowing | 40 (46.98%) | 6 (1.45%) | 57.73 (23.25−143.37) | < 0.01 |
| Echogenic halo | 49 (56.32%) | 5 (12.21%) | 105.22 (39.56−279.90) | < 0.01 |
| Vertical orientation | 12 (13.79%) | 4 (0.97%) | 16.36 (5.14−52.09) | < 0.01 |
| Age > 40 years | 77 (88.51%) | 183 (44.31%) | 9.68 (4.87−19.23) | < 0.01 |
| First-degree family history of breast cancer | 8 (9.20%) | 40 (9.70%) | 0.94 (0.43−2.10) | 0.89 |

Table 2. — *Comparison between the present study (private clinic) and the SONOBREAST multi-center study.*

| SONOBREAST | | Multi-center study | Private clinic |
|---|---|---|---|
| Breast nodules | | 1,403 | 500 |
| Malignant tumors | | 343 (24.7%) | 86 (17.2%) |
| Family history of breast cancer | | 86 (6.1%) | 48 (9.6%) |
| Median age (years) | Overall | 40 (27–49) | 41.9 (27.5–56.3) |
| | Benign tumors | 36 (23–44) | 39 (29–47) |
| | Malignant tumors | 51 (44–62) | 56 (48–64) |
| Mass size (mm) | Benign tumors | 16 (14–25) | 13 (9.9–17.8) |
| | Malignant tumors | 22 (15–30) | 20.2 (14.4–27.9) |
| Nonpalpable lesions | | 348 (25.0%) | 382 (76.4%) |
| Sensibility | | 84.5% | 95.4% |
| Specificity | | 64.5% | 78.6% |
| Overall accuracy | | 74.5% | 81.6% |
| ROC curve | Area under curve | 0.94 (0.92–0.96) | 0.94 (0.92–0.97) |

the smaller sample size, since the number of individuals with a family history of breast cancer was small, both in the group with cancer and in the group without cancer.

In Brazil, the reality of patients using public healthcare services and that of those who have sufficient resources to enable them to use private healthcare is quite different [12-14]. In the Brazilian public healthcare facilities on which the population of poor socioeconomic means and with limited access to healthcare depends, breast lesions are predominantly palpable, generally measuring between 2.0 and 5.0 cm at diagnosis [3, 5, 15]. The current study evaluated patients from a private clinic, probably with better socioeconomic conditions and better access to diagnostic methods for the detection of breast lesions [12-15] .This is reflected in the identification of smaller tumors compared to those found in the initial SONOBREAST study.

In the classic study conducted by Chen *et al.*, results showed that small breast lesions of less than 1 cm in diameter may not have the same suspect characteristics as larger lesions [16]. Therefore, the evaluation of the present population sample serves to balance the previous findings obtained with the SONOBREAST model. In the initial study, most of the patients were receiving care within the Brazilian public healthcare service and in the sample analyzed 75% of the lesions were palpable at diagnosis [3]. In that study, the overall accuracy of the model was 74.50%, sensitivity 84.50%, and specificity 64.50% [3]. In the current series, in which 76.40% of the lesions were non-palpable, accuracy was 81.60%, with sensitivity of 95.40% and specificity of 78.69%, showing that the model remains reliable despite the reduction in the number of palpable lesions in the sample analyzed (Table 2).

Of the morphological characteristics, tumor size has always been considered an essential characteristic in the investigation of breast nodules, with differing results regarding the prediction of malignancy [17-19]. Nevertheless, the inclusion of tumor size and palpability did not improve the accuracy of the SONOBREAST model and was not found to be significant in the multivariate analysis; therefore, these variables were excluded from the method [3].

Improvements to screening programs have increased the proportion of cases of breast cancer that are detected at early stages involving smaller tumors [20-22]. Therefore, the better the screening and healthcare of any given population, the less important is tumor size in predicting malig-

nancy in solid breast lesions [3, 22].

The high NPV (98.2%) found in the present study for the SONOBREAST model also merits particular attention. This finding reflects the greater probability that if a result is negative, there is indeed no disease. Therefore, use of SONOBREAST for the investigation of solid breast nodules is highly reliable for estimating the possibility of malignancy, which may consequently reduce the rates of unnecessary biopsies.

The SONOBREAST model permits the probability of malignancy to be identified in a precise and continuous manner [23], thus aiding diagnostic definition and treatment management. Therefore, discussions on strategies between different types of biopsy or the possibility of following up the patient clinically can be individualized. Amongst the limitations of the present study, the ultrasonographic evaluation performed by a single examiner can be highlighted.

The present study shows that although the odds ratios for malignancy are not exactly the same for all the variables of the original study, the final accuracy is excellent in any care model, either public or private. Therefore, SONOBREAST represents an effective diagnostic model both for populations in which locally advanced tumors predominate and for those in which the majority of tumors are non-palpable.

## References


[1] Hooley R.J., Scoutt L.M., Philpotts L.E.: "Breast ultrasonography: State of the art". *Radiology*, 2013, *268*, 642.

[2] Paulinelli R.R., Freitas-Júnior R., Moreira M.A., Moraes V.A., Bernardes-Junior J.R., Vidal C.S., *et al.*: "Risk of malignancy in solid breast nodules according to their sonographic features". *J. Ultrasound Med*., 2005, *24*, 635.

[3] Paulinelli R.R., Freitas-Junior R., de Lucena C.E., Moreira M.A., de Moraes V.A., Bernardes-Júnior J.R., *et al.*: "Sonobreast: Predicting individualized probabilities of malignancy in solid breast masses with echographic expression". *Breast J*., 2011, *17*, 152.

[4] Sadigh G., Carlos R.C., Neal C.H., Dwamena B.A.: "Ultrasonographic differentiation of malignant from benign breast lesions: a meta-analytic comparison of elasticity and BI-RADS scoring". *Breast Cancer Res. Treat*., 2012, *133*, 23.

[5] Muradas R.R., Velho M.T., Riesgo I.S., Brum A.D., Rossi R.M., Piovezan J.M., *et al.*: "Clinical and mammographic profile of patients with breast cancer surgically treated". *Rev. Assoc. Med. Bras*., 2015, *61*, 220.

[6] Gonzaga C.M.R., Freitas-Junior R., Curado M.P., Sousa A.L., Souza-Neto J.A., Souza M.R.: "Temporal trends in female breast cancer mortality in Brazil and correlations with social inequalities: ecological time-series study". *BMC Public Health*, 2015, *15*, 96.

[7] Cotlear D., Gómez-Dantés O., Knaul F., Atun R., Barreto I.C., Cetrángolo O., *et al.*: "Overcoming social segregation in health care in Latin America". *Lancet*, 2015, *385*, 1248.

[8] American College of Radiology: Breast Imaging Reporting and Data System Ultrasound (BI-RADSTM - Ultrasound)". Reston: American College of Radiology, 2003.

[9] Granchi S., Vannacci E., Biagi E., Masotti L.: "Differentiation of breast lesions by use of HyperSPACE: hyper-spectral analysis for characterization in echography". *Ultrasound Med. Biol.,* 2015, *41*, 1967.

[10] Alvarenga A.V., Infantosi A.F., Pereira W.C., Azevedo C.M.: "Assessing the combined performance of texture and morphological parameters in distinguishing breast tumors in ultrasound images". *Med. Phys*., 2012, *39*, 7350.

[11] Liu H., Jiang Y., Dai Q., Zhu Q., Wang L., Zhang J., *et al.*: "Differentiation of benign and malignant sub-1-cm breast lesions using contrast-enhanced sonography". *J. Ultrasound Med*., 2015, *34*, 117.

[12] Paim J., Travassos C., Almeida C., Bahia L., Macinko J.: "The Brazilian health system: history, advances, and challenges". *Lancet*, 2011, *377*, 1778.

[13] Lee B.L., Liedke P.E., Barrios C.H., Simon S.D., Finkelstein D.M., Goss P.E.: "Breast cancer in Brazil: Present status and future goals". *Lancet Oncol*., 2012, *13*, e95.

[14] Goss P.E., Lee B.L., Badovinac-Crnjevic T., Strasser-Weippl K., Chavarri-Guerra Y., St Louis J., et al.: "Planning cancer control in Latin America and the Caribbean". *Lancet Oncol*., 2013, *14*, 391.

[15] Liedke P.E., Finkelstein D.M., Szymonifka J., Barrios C.H., Chavarri-Guerra Y., Bines J., *et al.*: "Outcomes of breast cancer in Brazil related to health care coverage: a retrospective cohort study". *Cancer Epidemiol. Biomarkers Prev*., 2014, *23*, 126.

[16] Chen S.C., Cheung Y.C., Su C.H., Chen M.F., Hwang T.L., Hsueh S.: "Analysis of sonographic features for the differentiation of benign and malignant breast tumors of different sizes". *Ultrasound Obstet. Gynecol.,* 2004, *23*, 188.

[17] Wo J.Y., Chen K., Neville B.A., Lin N.U., Punglia R.S.: "Effect of very small tumor size on cancer-specific mortality in node-positive breast cancer". *J. Clin. Oncol*., 2011, *29*, 2619.

[18] Yu K.D., Jiang Y.Z., Chen S., Cao Z.G., Wu J., Shen Z.Z., *et al.*: "Effect of large tumor size on cancer-specific mortality in node-negative breast cancer". *Mayo Clin Proc*., 2012, *87*, 1171.

[19] Sadigh G., Carlos R.C., Neal C.H., Wojcinski S., Dwamena B.A.: "Impact of breast mass size on accuracy of ultrasound elastography vs. conventional B-mode ultrasound: a meta-analysis of individual participants". *Eur. Radiol*., 2013, *23*, 1006.

[20] Rodrigues D.C.N., Freitas-Junior R., Corrêa R.S., Peixoto J.E., Tomazelli J.G., Rahal R.M.S.: "Performance of diagnostic centers in the classification of opportunistic screening mammograms from the Brazilian public health system (SUS)". *Radiol. Bras.,* 2013, *46*, 149.

[21] van Luijt P.A., Fracheboud J., Heijnsdijk E.A., den Heeten G.J., de Koning H.J., National Evaluation Team for Breast Cancer Screening in Netherlands Study Group (NETB): "Nation-wide data on screening performance during the transition to digital mammography: observations in 6 million screens". *Eur. J. Cancer,* 2013, *49*, 3517.

[22] Caetano S., Junior J.M., Finguerman F., Goldman S.M., Szejnfeld J.: "Mammographic assessment of a geographically defined population at a mastology referral hospital in São Paulo Brazil". *PLoS One*, 2013, *8*, e74270.

[23] Paulinelli R.R., Oliveira L.P., Freitas-Junior R., Soares L.R.: "The accuracy of the SONOBREAST statistical model in comparison to BI-RADS for the prediction of malignancy in solid breast nodules detected at ultrasonography". *Eur. J. Obstet. Gynecol. Reprod. Biol.,* 2016, *196*, 1.



Corresponding Author:
R. FREITAS-JUNIOR, M.D.
Programa de Mastologia
Hospital das Clínicas da
Universidade Federal de Goiás
1ª Avenida, s/n, Setor Universitário
74605-050 - Goiânia, Goiás (Brazil)
e-mail: ruffojr@terra.com.br