EJGO European Journal of Gynaecological Oncology

Caesarean scar choriocarcinoma with uterine rupture: a case report

Xiao-Man Li, Xiao-Yun Liu, Xiao-Juan Wang

Department of Gynecology. The Third Affiliated Hospital of Zunyi Medical College, Zunyi (China)

Summary

A caesarean scar choriocarcinoma is an extremely rare for its unique position. The authors report the clinical characteristics, pathologic findings, and treatments of a patient in caesarean scar choriocarcinoma with uterine rupture. The present report outlines a case of primary gestational choriocarcinoma with uterine rupture in caesarean scar misdiagnosed as a normal caesarean scar pregnancy in a 36-year-old woman. The patient underwent resection of the scar with tumor tissue and wound repair to preserve the uterus. The blood serum level of β-human chorionic gonadotropin (β-hCG) declined from > 200,000 IU/l to 49,151 IU/l the day after the operation. Finally, she received two courses of combined chemotherapy with 5-fluorouracil and actinomycin D. It is difficult to make clinical diagnosis in a primary gestational choriocarcinoma of the uterine caesarean scar. Awareness of the possibility of potentially catastrophic complications as heavy bleeding or uterine rupture, and operation to resect the scar with tumor tissue and wound repair combined with chemotherapy can become an effective alternative for the treatment of caesarean scar choriocarcinoma.

Key words: Caesarean scar; Choriocarcinoma; Treatment.

Introduction

Choriocarcinoma, a rare and highly malignant neoplasm classed among the gestational trophoblastic diseases (GTD), is a highly chemosensitive tumour type, has a very good prognosis, and it usually arises in the uterine body. Rare cases of choriocarcinoma have also been reported at multiple locations, including the ovaries [1], lungs [2], urinary bladder [3], stomach [4], fallopian tube [5], gut [6], and vulva [7]. Choriocarcinoma in a caesarean scar has been reported extremely unusual. The present report outlines a case of a caesarean scar choriocarcinoma and presents the authors' experience with the diagnosis and management of this case.

Case Report

A 36-year-old woman (gravida 3, para 2) was admitted to the present hospital with a complaint of amenorrhea for 40 days and increasingly severe pain of lower abdominal for half seven hours on March 27, 2015. Her first pregnancy ended with a full-term vaginal delivery. Her second pregnancy ended in a full-term delivery by caesarean section in 2014. Her menstrual cycle was irregular (25-55 days) with five to seven days duration. Her most recent menstrual period was on February 17, 2015. Bimanual examination was unclear because of extensive rigidity and pain of abdomin. A transvaginal sonogram showed a 6.1×5.5×4.1-cm mass implanted in the anterior wall of the uterine caesarean scar embedded in myometrium and separated from the endometrial cavity. Both the uterine cavity and the cervical canal were empty. Pulsed Doppler ultrasonography showed blood flow signals around the mass (Figures 1 and 2). There was accumulation of fluid within pelvic cavity. The urine pregnancy test was positive, and the blood level of β-human chorionic gonadotropin (β-hCG) was > 200,000 IU/l (normal value, < 5.0 IU/l) on March 27, 2015. The result of computed tomography (CT) of the chest was normal. A diagnosis of a normal caesarean scar pregnancy with uterine rupture due to acute abdomen, symptom of amenorrhea, and positive urine pregnancy test was reached, and the patient was administered with traditional laparotomy to resect lesion and wound repair to preserve the uterus. During surgery, a 10×8 cm complexes mass was bulging toward the serosa with a five-mm crevasse on the face of uterine mass. The total blood within intra-abdominal cavity was 900 ml. The patient's hemodynamic status remained stable during and after the surgery. The postoperative recovery was remarkable; the patient's serum β-hCG levels reduce to 49,151 IU/l the day after the operation. A histological examination confirmed the diagnosis of choriocarcinoma (Figure 3). The diagnosis of a caesarean scar choriocarcinoma was confirmed on the basis of all the clinic characterizes and histological examination. Subsequently, the patient was accepted as International Federation of Gynecology and Obstetrics Stage 1:10 and received two courses of combined chemotherapy (5-fluorouracil 28mg/kg and actinomycin D six μg/kg) for eight days. The β-hCG levels decreased from 49,151 IU/l (post-operation) to 4.7 IU/l after two cycles of chemotherapy on May 24, 2015. The post-chemotherapy period had some side-effects with gastrointestinal symptoms, without any major complications.

Revised manuscript accepted for publication August 17, 2016

7847050 Canada Inc.
www.irog.net

Figure 1. — Transvaginal ultrasonography of the patient. The uterine cavity and cervical canal are empty. A mass implanted in the anterior wall of the uterine caesarean scar can be seen.

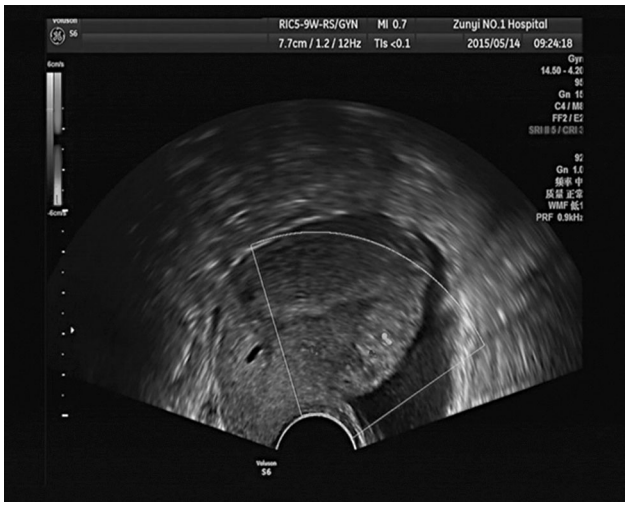

Figure 2. — Transvaginal ultrasonography of the patient. The size of the mass was 6.1×5.5×4.1 cm. Blood flow signals around the mass.

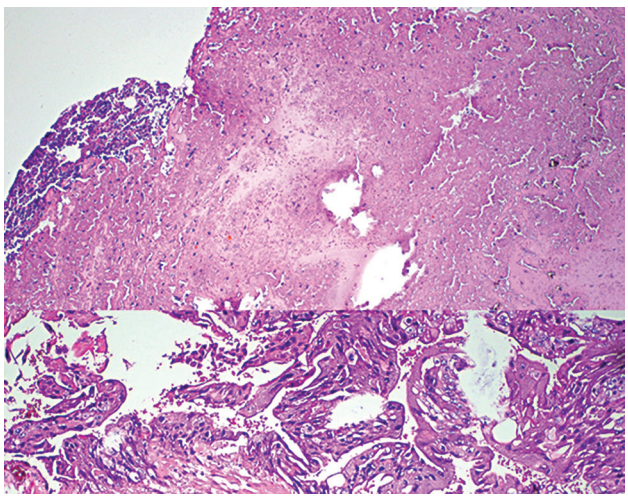

Figure 3. — Histologic section showing a choriocarcinoma.

Discussion

Choriocarcinoma is a highly malignant tumor that is classified among the gestational trophoblastic diseases. Gestational choriocarcinoma may accompany or follow any type of pregnancy, such as a hydatidiform mole, abnormal term pregnancy, an abortion or an ectopic pregnancy [8]. Cesarean scar pregnancy (CSP) is an ectopic pregnancy implanted in the myometrium at the site of a previous cesarean section scar [9]. It is a rare type of ectopic pregnancy, with the increasing rate of cesarean section, and the rate of CSP is also rising. The possible incidence of this type of ectopic pregnancy ranges from 1/1,800 to 1/2,200 pregnancies [10] and cesarean scar pregnancy rate accounts for 6% of ectopic pregnancies among women with a prior cesarean delivery [11]. There are two different types of CSP by Vial *et al.* [12].The first type (CSP-I) is caused by implantation of the amniotic sac into the previous caesarean section with progression of pregnancy toward the cervico-isthmic space and the uterine cavity. The second type (CSP-II) is caused by deep implantation of the gestational sac (GS) into myometrium and with pregnancy progress and is prone to heavy bleeding and rupture. The imaging criteria for diagnosis [13] are (i) empty uterus and empty cervical canal; (ii) development of the sac in the anterior wall of the isthmic portion; (iii) a discontinuity on the anterior wall of the uterus demonstrated on a sagittal plane of the uterus running through the amniotic sac; (iv) absent or diminished healthy myometrium between the bladder and the sac; (v) high velocity with low impedance peri-trophoblastic vascular flow clearly surrounding the sac is proposed in Doppler examination.

Caesarean scar choriocarcinoma has been reported by Qian *et al.* [8]. They presumably carry a high risk of uterine rupture and uncontrollable haemorrhage. For its unique position, the diagnosis of CSP is similar to caesarean scar choriocarcinoma without metastasis symptom. When ultrasound findings indicate a suspected CSP, abnormally elevated serum β-hCG levels could increase the suspicion of a GTD in the caesarean scar, especially choriocarcinoma [8]. Doctors need to be aware of the possibility of masses in a previous caesarean scar to avoid potentially severe complications.

Choriocarcinoma is a highly chemosensitive tumour type and has a very good prognosis. Multi-agent chemotherapy is the treatment of choice in high-risk choriocarcinoma. Currently, the most widely used combination regime is etoposide, methotrexate, actinomycin D, cyclophosphamide, and vincristine (EMACO) [14]. Medicine, embolization, surgery, or combinations are the main treatment methods of CSP, with the aim to eradicate the gestational materials, decrease possibility of bleeding, and preserve the uterus to conserve future fertility. However, the standard treatment of choice is still unknown [15].

In the present report, β-hCG level (> 200,000 IU/l) was much higher than in a normal pregnancy (50,000 to 100,000 IU/l). Moreover, the complaint of the patient was amenorrhea for 40 days and had an obvious enlarged uterine isthmus mass (6.1×5.5×4.1 cm) and blood flow signals around the mass blood flow. A transvaginal sonogram showed that both the uterine cavity and the cervical canal were empty. A strong suspicion is necessary for an early diagnosis of caesarean scar GTD. Notwithstanding, this case was not correctly diagnosed before treatment, the method of treatment was correct and timely. Caesarean scar choriocarcinoma should be included in the differential diagnosis of cervical lesions in patients in their reproductive years. It is easily misdiagnosed as a uterine cervical pregnancy, a threatened abortion, a normal CSP, a cervical polyp or another cervix neoplasm [8]. The present authors' experience suggests that surgery to resect the scar with tumor tissue and wound repair combined with chemotherapy can become an effective alternative for the treatment of caesarean scar choriocarcinoma. Of course, other methods such as a selective uterine artery embolization (UAE) doubled with chemotherapy is also an effective treatment because it also can avoid severe bleeding. The authors believe that the selection of treatment should be based on the clinic characteristics of the patient, combining the therapies of choriocarcinoma with CSP, and choosing the most effective and appropriate method to reduce the occurrence of potentially catastrophic complications.

References

[1] Exman P., Takahashi T.K., Gattás G.F., Cantagalli V.D., Anton C., Nalesso F., Diz Mdel P.: "Primary ovary choriocarcinoma: Individual DNA polymorphic analysis as a strategy to confirm diagnosis and treatment". *Rare Tumors*, 2013, *5*, 89.

[2] Di Crescenzo V., Laperuta P., Napolitano F., Carlomagno C., Garzi A., Vitale M.: "An unusual case of primary choriocarcinoma of the lung". *BMC Surg.*, 2013, *13*, S33.

[3] Gallagher L., Lind R., Oyasu R.: "Primary choriocarcinoma of the urinary bladder in association with undifferentiated carcinoma". *Hum. Pathol.*, 1984, *15*, 793.

[4] Matsunaga N., Hayashi K., Futagawa S., Fukuda T., Takahara O., Yoshida K., Maeda H.: "Primary choriocarcinoma of the stomach presenting as gastrointestinal hemorrhage: report of a case". *Radiat. Med.*, 1989, *7*, 220.

[5] Muto M.G., Lage J.M., Berkowitz R.S., Goldstein D.P., Bernstein M.R.: "Gestational trophoblastic disease of the Fallopian tube". *J. Reprod. Med.*, 1991, *36*, 57.

[6] Ravi B., Dalal A.K., Sharma U., Dhall J.C.: "Choriocarcinoma of the small gut". *Acta Obstet. Gynecol. Scand.*, 1997, *16*, 712.

[7] Weiss S., Amit A., Schwartz M.R., Kaplan A.L.: "Primary choriocarcinoma of the vulva". Int. J. Gynecol. Cancer, 2001, *11*, 251.

[8] Zhi-Da Qian, Xiao-Ming Zhu: "Caesarean scar choriocarcinoma: a case report and review of the literature". *Eur. J. Med. Res.*, 2014, *14*, 25.

[9] Herman A., Weinraub Z., Avrech O., Maymon R., Ron-El R., Bukovsky Y.: "Follow up and outcome of isthmic pregnancy located in a previous caesarean section scar". *Br. J. Obstet. Gynaecol.*, 1995, *102*, 839.

[10] Seow K.M., Hwang J.L., Tsai Y.L., Huang L.W., Lin Y.H., Hsieh B.C.: "Subsequent pregnancy outcome after conservative treatment of a previous cesarean scar pregnancy". *Acta Obstet. Gynecol. Scand.*, 2004, *83*, 1167.

[11] Rotas M.A., Haberman S., Levgur M.: "Cesarean scar ectopic pregnancies: etiology, diagnosis, and management". *Obstet. Gynecol.*, 2006, *107*, 1373.

[12] Vial Y., Petignat P., Hohlfeld P.: "Pregnancy in a cesarean scar". *Ultrasound Obstet. Gynecol.*, 2000, *16*, 592.

[13] Jurkovic D., Hillaby K., Woelfer B., Lawrence A., Salim R., Elson C.J.: "First-trimester diagnosis and management of pregnancies implanted into the lower uterine segment Cesarean section scar". *Ultrasound Obstet. Gynecol.*, 2003, *21*, 220.

[14] Milenković V., Lazović B., Mačvanski M., Jeremić K., Hrgović Z.: "Clinical outcome of a FIGO stage IV gestational choriocarcinoma". *Case Rep Oncol.*, 2013, *28*, 504.

[15] Wang H.Y., Zhang J., Li Y.N., Wei W., Zhang D.W., Lu Y.Q., Zhang H.F.: "Laparoscopic management or laparoscopy combined with transvaginal management of type II cesarean scar pregnancy". *JSLS*, 2013, *17*, 263.

Corresponding Author:
XIAO-YUN LIU, M.D.
Department of Gynecology
The Third Hospital Affiliated of Zunyi Medical College
Zunyi, Guizhou 563000 (China)
e-mail:manyunxiao@yeah.net