

“See and treat” LEEP biopsy for cervical intraepithelial neoplasia grade 2/3

A. Abe, M. Nishimura, M. Irahara

Department of Obstetrics and Gynecology, Tokushima University Hospital, Tokushima (Japan)

Summary

Purpose of investigation: To evaluate the safety and efficacy of loop electrosurgical excision procedure (LEEP) biopsy using a “see-and-treat” strategy, and compare outcomes after “LEEP biopsy, inpatient LEEP and ablation, and inpatient conization with cervical intraepithelial neoplasia (CIN) grade 2/3. *Materials and Methods:* The authors performed a retrospective study including 300 women with CIN2/3 who were followed up ≥ 6 months following outpatient LEEP/inpatient LEEP and ablation/inpatient conization. Recurrence, additional treatment for recurrence, pregnancy, and term delivery following treatment were evaluated. *Results:* During the median follow-up duration of 22 months, recurrences were significantly more common following LEEP biopsy (39%) compared to LEEP and ablation (13%) and conization (16%) and were managed by repeat LEEP. Pregnancy and full-term delivery rates following LEEP biopsy were significantly higher. *Conclusion:* “See-and-treat” LEEP biopsy was safely performed in the outpatient department. Pregnancy rates and full-term deliveries following LEEP biopsy appear favorable.

Key words: Cervical intraepithelial neoplasia; Colposcopy; Electrosurgery; Papanicolaou test; Recurrence; Uterine cervical neoplasms.

Introduction

Cervical cancer is the second most commonly diagnosed cancer and the fourth leading cause of cancer death in women worldwide, accounting for an estimated 275,000 deaths annually [1]. Cervical cancer develops over a long period, progressing from premalignant and early-stage lesions called cervical intraepithelial neoplasia (CIN) to invasive cancers. As a result, screening programs such as cytologic screening have been able to detect pre-cancerous and early-stage cervical cancer in young women. Furthermore, newer surgical options for early-stage disease have allowed successful treatment and reduced cervical cancer mortality. However, in medically underserved populations with a poor healthcare infrastructure, the lack of regular screening and effective treatment programs have resulted in a disproportionately high burden of cervical cancer [1].

Multiple treatment options exist for early-stage cervical lesions. The World Health Organization currently recommends the treatment of CIN2 or CIN3 precancerous cervical lesions using loop electrosurgical excision procedure (LEEP), conization, or hysterectomy. Of these modalities, LEEP [2] is particularly attractive in low-resource settings as it offers a “see and treat” option of simultaneously diagnosing and treating cases with abnormal Pap smear and colposcopic findings [3]. Furthermore, LEEP can be performed easily and rapidly under local anesthesia in an outpatient setting [4], and is associated with less blood loss

and fewer complications compared to conization [2]. For example, obstetric complications, such as the risk of low birth weight and preterm delivery, are increased after conization [5-8], but not after LEEP [9].

In this study, the authors evaluated the safety and efficacy of LEEP biopsy using a “see and treat” strategy and compared outcomes after “see and treat” LEEP biopsy, inpatient LEEP and ablation, and inpatient conization in a series of patients with CIN2/3 treated at a tertiary medical center in Japan.

Materials and Methods

After obtaining approval from the institutional review board, a retrospective review of medical records was performed for patients with CIN2/3 treated consecutively between April 2011 and June 2015 at the Department of Obstetrics and Gynecology in the Tokushima University Hospital, Japan. Inclusion criteria were women aged under 50 years, with CIN2/3, who had not been previously treated for CIN, and who had been followed up for six-months or longer. Exclusion criteria were women with CIN1 or invasive carcinoma at the time of primary treatment, and cases where hysterectomy was indicated as the initial treatment (Figure 1).

All cases underwent colposcopic evaluation and visualization of lesions after application of 3% acetic acid for two minutes. Based on colposcopic findings, patients were treated using one of three strategies: 1) outpatient LEEP without anesthesia using a “see and treat” strategy in patients with a narrow visible region of disease, 2) inpatient LEEP and ablation under local anesthesia in patients

Revised manuscript accepted for publication September 11, 2017

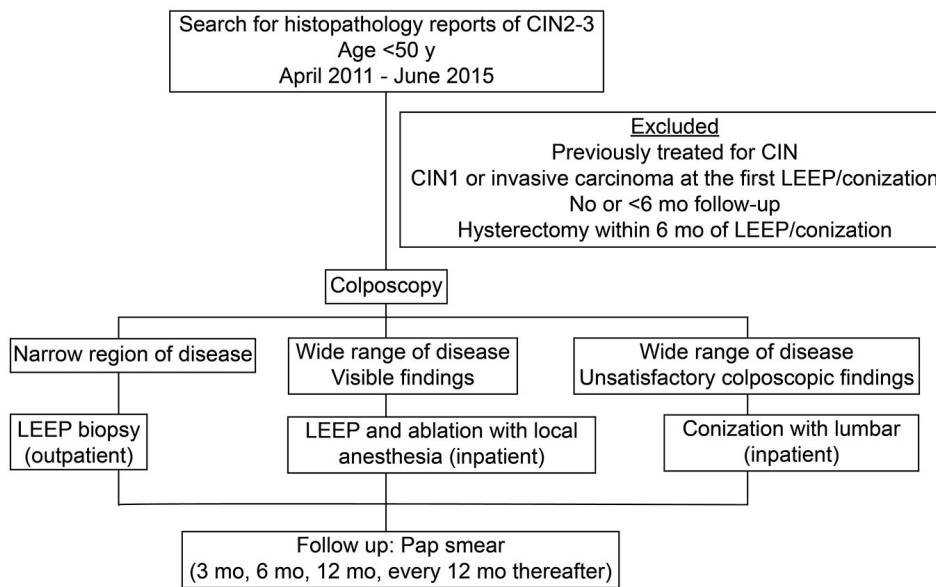


Figure 1. — Study design. CIN: cervical intraepithelial neoplasia; LEEP: loop electrosurgical excision procedure.

Table 1. — Patient demographics and operative details ($n=300$)

Age (years; median, range)	34 (19-49)
Obstetric status	0 1 2 ≥ 3 NA
Gravidity	74 72 61 82 11
Parity	110 68 78 33 11
Smoking status	
Never smoked	169 (56%)
Current smoker	90 (30%)
Past smoker	13 (4%)
Unknown	28 (10%)
CIN grade	
CIN2	116 (39%)
CIN3	184 (61%)
Primary treatment	
LEEP biopsy	169 (56%)
LEEP and ablation	99 (33%)
Conization	32 (11%)
Follow-up time (months; median, range)	22 (6-63)

Data are presented as [median, range] for continuous variables and [number (%)] for categorical variables. CIN: cervical intraepithelial neoplasia; LEEP: loop electrosurgical excision procedure.

with a wide visible region of disease, and 3) inpatient conization with lumbar anesthesia in patients with unsatisfactory colposcopic visualization and suspected wide region of disease (Figure 1). “See and treat” LEEP biopsy was performed with a six-mm diameter diathermal electrocauterizer after colposcopy without anesthesia. LEEP and ablation was performed with YAG laser under paracervical block and local anesthesia with 1% lidocaine. Conization was performed using an ultrasonic energy device under lumbar anesthesia.

Patients were followed up postoperatively at three, six, 12 months, and at 12-month intervals subsequently. Pap smear with endocervical cytobrush and liquid-based cytology (LBC) were

performed at each follow-up. In the present hospital, HPV clearance was not evaluated. When cytology showed negative findings more than twice after primary LEEP or conization, the treatment was considered to be curative. When abnormal cytological findings were detected, colposcopy and biopsy were performed. If CIN was detected, the case was defined as treatment failure.

The following data were collected during the retrospective review: patient demographics - age, marital status, parity, and smoking status, diagnosis, treatment, follow-up intervals, and outcomes. The primary outcome of interest was recurrence, which was defined as the reappearance of a lesion more than six months after LEEP or conization. Additional treatment for the recurrence, pregnancy after treatment, and term delivery were assessed as secondary outcomes of interest.

Statistical analyses were performed using R software. Differences in the frequency of the primary and secondary outcomes of interest in the three tests groups were analyzed using tests for difference in ratios (prop.test function in R software). A $p < 0.05$ was considered statistically significant.

The study was conducted under approval from the institutional review board of Tokushima University Hospital. For this type of study formal consent was not required. This article does not contain any studies with animals performed by any of the authors.

Results

A total of 300 cases with LEEP or conization procedures performed by four surgeons were included in the study. Patient characteristics are shown in Table 1. The median patient age was 34 (range, 19-49) years. One patient was a teenager, 74 patients (25%) were in their 20s, 165 patients (55%) in their 30s, and 60 patients (20%) in their 40s. Fifty-six percent (169/300) of patients were non-smokers. With regards to obstetric history, 143 patients (48%) had two or more pregnancies and 111 patients (37%) had two or more children. A total of 116 patients (39%) had CIN2, and 184

Table 2. — Treatment outcomes in the three primary treatment groups.

	LEEP biopsy (n=169)	LEEP and ablation (n=99)	Conization (n=32)
Recurrence (n=84; 28%)	66 (39%) ^{a,b}	13 (13%) ^a	5 (16%) ^b
Under 12 months	19 (11%)	5 (5%)	0 (0%)
12-24 months	15 (9%) ^c	1 (1%) ^{c,d}	4 (13%) ^d
Over 24 months	32 (19%) ^{e,f}	7 (7%) ^e	1 (3%) ^f
Additional treatment (n=89; 30%)	69 (41%) ^{g,h}	15 (15%) ^g	5 (16%) ^h
LEEP	48 (28%) ^{i,j}	1 (1%) ⁱ	1 (3%) ^j
Outpatient	33 (19%) ^{k,l}	0 (0%) ^k	0 (0%) ^l
Inpatient	15 (9%) ^m	1 (1%) ^m	1 (3%)
Conization	5 (3%)	3 (3%)	0 (0%)
Hysterectomy	1 (0.6%)	2 (2%)	2 (6%)
Observation (CIN1)	13 (8%)	6 (6%)	2 (6%)
Development of invasive carcinoma	2 (1.2%)	3 (3%)	0 (0%)
Pregnancy after treatment (n=69; 23%)	44 (26%) ^N	15 (15%) ^{N,O}	10 (31%) ^O
Term delivery	34 (20%) ^P	10 (10%) ^P	5 (16%)
Continuing pregnancy	4 (2.4%)	2 (2%)	0 (0%)
Induced abortion	1 (0.6%) ^q	1 (1%) ^r	5 (16%) ^{q,r}
Preterm delivery	3 (1.8%)	0 (0%)	0 (0%)
Spontaneous abortion	4 (2.4%)	2 (2%)	0 (0%)

Lower case letters (a, b, etc.) indicate significant differences between groups. Upper case letters (N, O) indicate a strong trend of statistical significance (N: $p = 0.054$, O: $p = 0.079$). CIN: cervical intraepithelial neoplasia; LEEP: loop electrosurgical excision procedure.

patients (61%) had CIN3. "See and treat" LEEP biopsy was performed in 169 cases (56%; CIN2, 89; CIN3, 80), LEEP and ablation in 99 cases (33%; CIN2, 23; CIN3, 76), and conization in 32 cases (11%; CIN2, 4; CIN3, 28). There were no episodes of major bleeding or major infections with any of the methods. The patients were followed-up for a median duration of 22 (range, 6-63) months.

Treatment outcomes observed during follow-up are described in Table 2. A total of 84 patients (28%) developed recurrence (Table 2). Recurrences were significantly more common after LEEP biopsy (39%) compared to LEEP and ablation (13%) and conization (16%). The majority of recurrences (19%) after LEEP biopsy occurred after 24 months of follow-up. In 15/66 patients with recurrence after LEEP biopsy, the recurrent lesion was noted in the endocervical canal and not at the external uterine orifice where the original lesion was located. Patients with recurrences were either managed conservatively (observation) or received additional treatment (LEEP/conization/hysterectomy).

Additional treatment was required in a significantly higher proportion of patients after LEEP biopsy (41%) compared to LEEP and ablation (15%) and conization (16%). Of note, additional treatment after LEEP biopsy was mostly in the form of repeat LEEP (28%) that was performed in an outpatient (19%) or inpatient (9%) setting. Indeed, additional treatment in the form of LEEP was significantly more common in the LEEP biopsy group (28%) compared to LEEP and ablation (1%) and conization groups (3%). There were no significant differences in the other modes of additional treatment among the three groups.

There were statistically significant differences in the rate

of pregnancies after treatment in the three groups. Pregnancy rates were significantly higher after LEEP biopsy (26%) and conization (31%), compared to LEEP and ablation (15%). However, induced abortions were significantly more common after conization (16%), compared to LEEP biopsy (0.6%) and LEEP and ablation (1%). In addition, term delivery rates were significantly higher after LEEP biopsy (20%) compared to LEEP and ablation (10%).

Discussion

The present authors' aim in this study was to investigate the safety and efficacy of "see and treat" LEEP biopsy and compare its outcomes with inpatient LEEP and ablation, and conization in patients with CIN2/3. In this five-year retrospective study, nearly half (53%) of CIN2/3 cases in patients under 50 years of age were treated with LEEP biopsy without anesthesia in an outpatient setting. It is important to note that "see and treat" LEEP biopsy allowed immediate diagnosis and treatment using LEEP without obtaining cervical biopsy specimens at the time of initial colposcopy [6]. Furthermore, compared to the traditional punch biopsy that can examine only a small region and excise only very small lesions less than 1 cm, LEEP could excise lesions greater than 1 cm. Similar to cases receiving LEEP and ablation or conization in an inpatient setting under anesthesia, outpatient "see and treat" LEEP had no immediate complications. These results suggest that LEEP biopsy can be safely performed for CIN2/3 lesions in an outpatient department. By avoiding anesthesia and hospitalization, LEEP biopsy potentially offers an economical alternative both in terms of time and healthcare cost. The present results are in agreement with those reported in a re-

cent meta-analysis that showed that LEEP procedures were faster, caused less intraoperative bleeding, and were associated with shorter hospital stay compared to conization [10]. However, recurrence rates in this study were higher following “see and treat” LEEP biopsy than following LEEP and ablation or conization. LEEP was performed with ablative procedures in the ectocervical and endocervical margins. Multiple fragmentation during LEEP affected the assessment and interpretation of the margins. This could potentially have resulted in the higher recurrence in this study. Nonetheless, it should be noted that the majority of the recurrences could be managed by repeat LEEP. Indeed, there were no significant differences between the three groups regarding the proportion of patients that had recurrence and required additional treatment in the form of conization, hysterectomy, or were managed by observation for CIN1 or who developed invasive carcinoma. The rates of recurrence observed in this study cohort were similar to those reported previously [4, 11, 12].

It should also be highlighted that nearly half of the recurrences after LEEP biopsy occurred beyond 24 months of follow-up. This is in contrast to conization where 80% of the recurrences occur in the first 24 months. Indeed, these results demonstrate the need for prolonged follow-up of patients after outpatient LEEP biopsy. Previous studies have provided conflicting opinions about the timing of recurrences following LEEP [13-15]. For example, Cecchini *et al.* showed that recurrences were highest in the first year (7.4%), and rare beyond the third year in a study of Italian women with a 66.5-month average follow-up [14]. Similarly, Carter *et al.* observed most recurrences occurred in the first year (3%) and only 1% beyond one year of treatment in a cohort of Australian women [15]. These differences in the rates and timing of recurrence might reflect differences in patient demographics (age, disease status), surgical procedures, or surveillance/follow-up protocols [16, 17]. For example, treatment failure and recurrence rates have been linked to the older age of patients, glandular involvement, and procedural variations, such as excision of involved excision margins [17].

Another notable observation was the location of the recurrent lesions following LEEP biopsy. In nearly one-fourth of patients with recurrence after LEEP biopsy, the recurrent lesion was noted in the endocervical canal and not at the site of the original lesion at the external uterine orifice. This suggests that the squamo-cutaneous junction (SCJ) could move into the cervical canal following LEEP and the recurrent lesions may, therefore, be missed during colposcopy. This may be especially important for cases that develop invasive carcinoma as advanced lesions were found in the endocervical canal. When conducting a cytodiagnosis on a lesion in the endocervical canal, it is necessary to properly insert a brush deeply inside.

Furthermore HPV test can be considered useful as an ancillary test.

As parity and smoking status are known to be risk factors for cervical cancer, the present authors examined the smoking and parity status of the study population. Nearly one-third of the study population had a parity ≥ 2 and current or past history of smoking. Considering the young age of the present study subjects (median age, 34 years), hysterectomies were not included as a treatment option and LEEP biopsy was preferred in most patients. Indeed, the present results show that LEEP biopsy was associated with significantly higher pregnancy rates (26%), lower induced abortions (0.6%), and higher term delivery rates (20%), compared to the other treatment options used in the study. The present results are in agreement with previous studies showing no important adverse effects of LEEP on fertility [9].

This study was not without limitations. First, this was a single-center study based on the Japanese population. Therefore, results from this study may not apply to other populations or surgical practices. Second, the authors did not monitor HPV infection and clearance status in the study since these services are not covered by insurance in Japan. Previous studies have shown that colposcopic detection of HPV satellite lesions outside the transformation zone and HPV persistence are independent factors for treatment failure [16, 17]. Some authors recommend that HPV-positive women after LEEP or conization require close monitoring with HPV and Pap smear [18]. Future studies should consider additional HPV testing as part of monitoring and surveillance following LEEP [3, 13, 16, 17].

Conclusion

In conclusion, “see and treat” LEEP biopsy could be performed safely without anesthesia in the outpatient department in women with CIN2/3 lesions. Recurrences were largely managed by repeat LEEP and rates of pregnancy and full-term deliveries following LEEP biopsy were higher than following LEEP and ablation or conization. However, higher rates of recurrences, that occurred late and often within the endocervical canal, highlights the need for prolonged and careful monitoring of patients following LEEP biopsy.

Acknowledgement

Editorial support, in the form of medical writing, assembling tables, and creating high-resolution images based according to the authors’ detailed directions, collating author comments, copyediting, fact checking, and referencing, was provided by Cactus Communications.

References

- [1] Kamangar F., Dores G.M., Anderson W.F.: "Patterns of cancer incidence, mortality, and prevalence across five continents: defining priorities to reduce cancer disparities in different geographic regions of the world". *J. Clin. Oncol.*, 2006, 24, 2137.
- [2] Prendiville W., Cullimore J., Norman S.: "Large loop excision of the transformation zone (LLETZ). A new method of management for women with cervical intraepithelial neoplasia". *Br. J. Obstet. Gynaecol.*, 1989, 96, 1054.
- [3] Wright T.C. Jr., Cox J.T., Massad L.S., Twiggs L.B., Wilkinson E.J.: "2001 Consensus Guidelines for the management of women with cervical cytological abnormalities". *JAMA*, 2002, 287, 2120.
- [4] Nogara P.R., Manfroni L.A., da Silva M.C., Consolaro M.E.: "The "see and treat" strategy for identifying cytologic high-grade precancerous cervical lesions among low-income Brazilian women". *Int. J. Gynaecol. Obstet.*, 2012, 118, 103.
- [5] Matsubara S., Usui R., Ohkuchi A.: "Controversy on another possible risk of preterm delivery after cervical conization: time interval between conization and conception". *Eur. J. Gynaecol. Oncol.*, 2014, 35, 6.
- [6] Bevis K.S., Biggio J.R.: "Cervical conization and the risk of preterm delivery". *Am. J. Obstet. Gynecol.*, 2011, 205, 19.
- [7] Nam K.H., Kwon J.Y., Kim Y.H., Park Y.W.: "Pregnancy outcome after cervical conization: risk factors for preterm delivery and the efficacy of prophylactic cerclage". *J. Gynecol. Oncol.*, 2010, 21, 225.
- [8] Kristensen J., Langhoff-Roos J., Wittrup M., Bock J.E.: "Cervical conization and preterm delivery/low birth weight. A systematic review of the literature". *Acta Obstet Gynecol Scand.*, 1993, 72, 640.
- [9] Acharya G., Kjeldberg I., Hansen S.M., Sorheim N., Jacobsen B.K., Maltau J.M.: "Pregnancy outcome after loop electrosurgical excision procedure for the management of cervical intraepithelial neoplasia". *Arch. Gynecol. Obstet.*, 2005, 272, 109.
- [10] El-Nashar S.A., Shazly S.A., Hopkins M.R., Bakkum-Gomez J.N., Famuyide A.O.: "Loop electrosurgical excision procedure instead of cold-knife conization for cervical intraepithelial neoplasia in women with unsatisfactory colposcopic examinations: a systematic review and meta-analysis". *J. Low. Genit. Tract. Dis.*, 2017, 21, 129.
- [11] Kochen M., Helmerhorst T.J., Berkhof J., Louwers J.A., Nobbenhuis M.A., Bais A.G., *et al.*: "Risk of recurrent high-grade cervical intraepithelial neoplasia after successful treatment: a long-term multi-cohort study." *Lancet Oncol.*, 2011, 12, 441.
- [12] Wilkinson E.J.: "Women with cervical intraepithelial neoplasia: requirement for active long-term surveillance after therapy". *J. Natl. Cancer. Inst.*, 2009, 101, 696.
- [13] Duesing N., Schwarz J., Choschzick M., Jaenicke F., Giesecking F., Issa R., *et al.*: "Assessment of cervical intraepithelial neoplasia (CIN) with colposcopic biopsy and efficacy of loop electrosurgical excision procedure (LEEP)". *Arch. Gynecol. Obstet.*, 2012, 286, 1549.
- [14] Cecchini S., Visioli C.B., Zappa M., Ciatto S.: "Recurrence after treatment by loop electrosurgical excision procedure (LEEP) of high-grade cervical intraepithelial neoplasia". *Tumori.*, 2002, 88, 478.
- [15] Carter J., Sim J., Land R., Dalrymple C., Abdel-Hadi M., Pather S.: "Recurrence after treatment for high-grade dysplasia: Should we modify our post-treatment surveillance protocols?" *Aust. N.Z. J. Obstet. Gynaecol.*, 2006, 46, 360.
- [16] Verguts J., Bronselaer B., Donders G., Arbyn M., Van Eldere J., Drijkoningen M., Poppe W.: "Prediction of recurrence after treatment for high-grade cervical intraepithelial neoplasia: the role of human papillomavirus testing and age at conisation". *BJOG*, 2006, 113, 1303.
- [17] Kyrgiou M., Tsoumpou I., Vrekoussis T., Martin-Hirsch P., Arbyn M., Prendiville W., *et al.*: "The up-to-date evidence on colposcopy practice and treatment of cervical intraepithelial neoplasia: the Cochrane colposcopy & cervical cytopathology collaborative group (C5 group) approach". *Cancer. Treat. Rev.*, 2006, 32, 516.
- [18] Paraskevaidis E., Lolis E.D., Koliopoulos G., Alamanos Y., Fotiou S., Kitchener H.C.: "Cervical intraepithelial neoplasia outcomes after large loop excision with clear margins". *Obstet. Gynecol.*, 2000, 95, 828.

Corresponding Author:

AKIKO ABE, M.D.

Department of Obstetrics and Gynecology

Tokushima University Hospital

3-18-15 Kuramoto, Tokushima City

Tokushima 770-8503 (Japan)

e-mail: akiko06090111@yahoo.co.jp