EJGO European Journal of Gynaecological Oncology

Squamous cell carcinoma arising from teratoma of the ovary: magnetic resonance, computed tomography, and pathological findings

F. Beyazal Çeliker[1], A. Turan[2], M. Beyazal[1], H. Temel Eroğlu[3], G. Bulut[4], N. Çölçimen[5], H. Beyazal Polat[6]

[1] *Recep Tayyip Erdoğan University Faculty of Medicine, Department of Radiology, Rize*
[2] *Muğla Yatağan State Hospital, Department of Radiology, Muğla*
[3] *Lokman Hekim Van Hospital, Department of Obstetrics and Gynecology, Van*
[4] *Yüzüncü Yıl University Faculty of Medicine, Department of Pathology, Van*
[5] *Yüzüncü Yıl University Faculty of Medicine, Department of Histology and Embryology, Van*
[6] *Recep Tayyip Erdoğan University Faculty of Medicine, Department of Internal Medicine, Rize (Turkey)*

Summary

In the present case report, the authors investigated the clinicopathological characteristics of squamous cell carcinoma (SCC) arising from teratoma of the ovary and intended to report their clinical experience. Malignant transformation of ovarian teratoma is a quite rare condition with SCC observed to be the most common form of transformation. The present case was a 43-year-old female patient and her clinical presentation was abdominal pain, abdominal distension, and abdominal mass sensation. The patient underwent ultrasonography. After detection of a mass, magnetic resonance imaging (MRI) was performed. Surgery was performed on the patient and the pathological report revealed SCC arising from teratoma. The patient was evaluated retrospectively in terms of demographic characteristics, MRI, surgical findings, and prognosis.

Key words: Magnetic resonance imaging; Neoplastic transformation; Squamous cell carcinoma; Teratoma.

Introduction

Malignant transformation of teratoma to squamous cell carcinoma (SCC) is a rare condition. This generally occurs after 40 years of age and the mean age ranges from 45 to 60 years. Since teratoma has a complex structure, it is extremely difficult to distinguish malignant transformation using imaging methods. Herein, the authors present a case of malignant transformation of teratoma to SCC in a 43-year-old female patient who presented with abdominal pain, abdominal distension, abdominal mass sensation, and diagnosed histopathologically and the case was evaluated in light of the literature.

Case Report

A 43-year-old female patient presented to the present Obstetrics and Gynecology Clinic with abdominal distension and sudden-onset of pain. The patient underwent US and abdominal CT at an external center. After detecting a pelvic mass with fatty tissue density, the patient was referred to the authors' service for MRI (Figure 1). The sections were obtained at three- to six-mm in thickness with 2.5- to three-mm gap. Sagittal T1-weighted images [repetition time (TR)/echo time (TE): 700-800/8-12] and sagittal T2-weighted images (TR/TE: 3280/78) were obtained by spin echo technique. Contrast-enhanced sagittal T1-weighted images (TR/TE: 685/l4) were also obtained. MRI revealed a well-circumscribed cystic mass (16.5 cm in size in its long axis) with a thick wall almost completely filling the left adnexal area, significantly causing com-

Figure 1. — A mass lesion with fatty tissue density that fills the pelvic region on computed tomography.

Revised manuscript accepted for publication October 12, 2015

7847050 Canada Inc.
www.irog.net

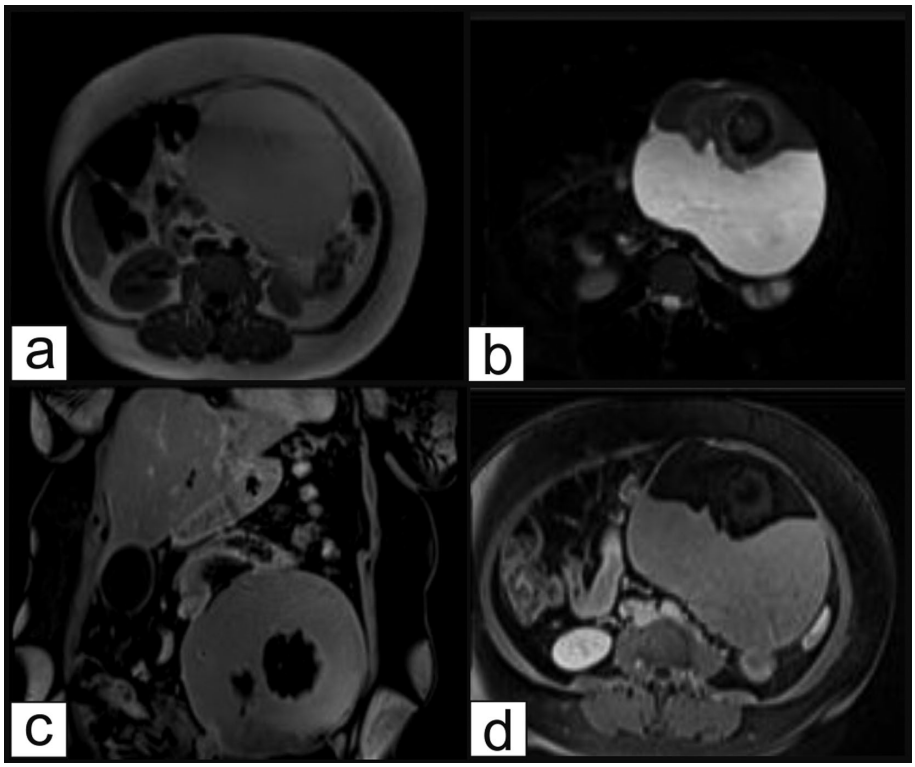

Figure 2. — (a) and (b): Teratoma showing fatty component and blood-fluid level on the T1 and STIR images; (c) and (d): solid component and contrast uptake in the wall of the cyst in the T1 images after contrast uptake.

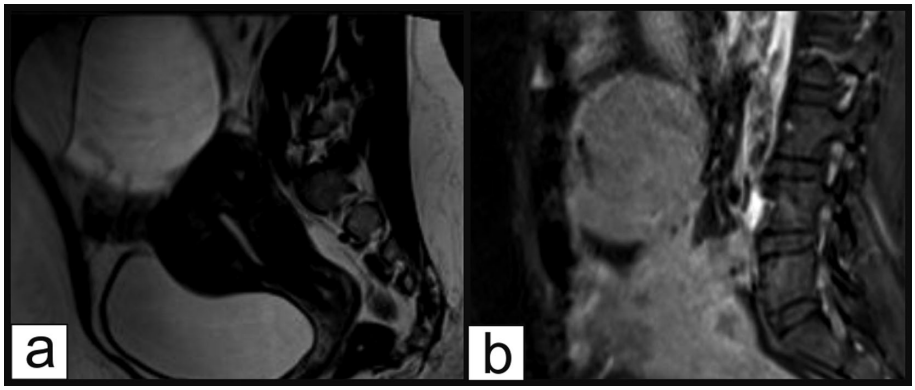

Figure 3. — a) the border between the mass and the uterus cannot be distinguished on T2 sagittal magnetic resonance imaging; b) multiple myoma nuclei in the uterine myometrium.

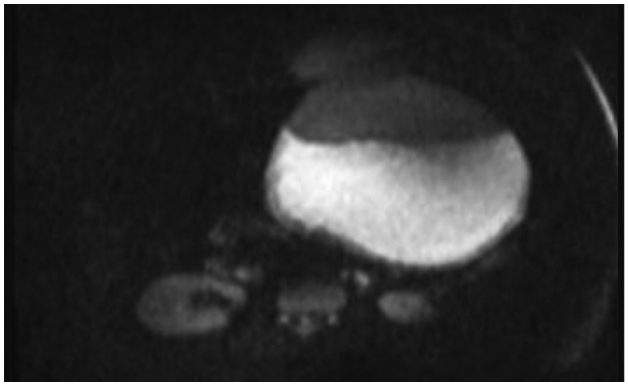

Figure 4. — Blood-fluid level in the teratoma indicating hemorrhage that showed diffusion restriction in the diffusion-weighted image.

pression of the adjacent pelvic organs, showing fluid-blood level and fat tissue signal, and having a solid component. After administration of the contrast agent, the solid component and wall of the cystic mass showed contrast uptake (Figure 2). Irregularity was observed in a small segment in the inferomedial wall of the mass and the border of the mass could not be distinguished from the uterus at this level (Figure 3a). The present patient had blood-fluid level indicating hemorrhage that showed diffusion restriction in the diffusion-weighted images (Figure 4), which has not been previously reported in the literature. In the present patient, evaluation in terms of adjacent fat plane invasion was suboptimal as the mass was extremely large and filled the abdominopelvic midline; however, not distinguishing the border of the mass from that of the uterus made malignant transformation suspicious. Moreover, there were multiple mass lesions leading to lobulated uterine contour, which was consistent with myoma (Figure 3b). The patient underwent surgery. During the surgery, it was observed that although the

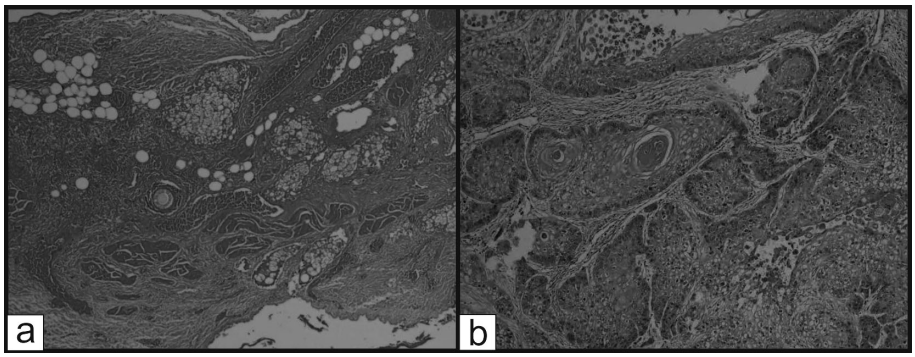

Figure 5. — (a) Mature neural and fibro-adipose tissues are observed in the lesion material from the right ovary [haematoxylin and eosin staining (H&E), X100]; (b) in addition to mature neural and fibro-adipose tissues in the lesion material, an organized tumor in the form of infiltrated islets and cords extending to the serosa are observed (H&E, ×100).

mass was localized in the left adnexal area and showed mild torsion, it originated from the right ovary. Hysterectomy and oophorosalpingectomy were performed. The surgical material was submitted for pathological examination. The pathological report revealed SCC arising from teratoma and had the following details: the lesion material from the right ovary showed mature neural and fibro-adipose tissues as well as organized tumor in the form of infiltrated islets and cords extending to the serosa (Figure 5). In tumor cells, pleomorphism was remarkable and mitotic activity was high; however, no vascular or neural invasion was observed. The patient was discharged from the hospital with full recovery after the surgery and requested follow-up visits.

Discussion

Teratoma of the ovary is the most common ovarian tumor encountered in women of adolescent and reproductive age [1, 2]. All teratomas are benign initially; not all but the majority of them show benign course. Secondary malignant transformation, although rarely, has been encountered in cases with teratomas at an incidence of 0.2%-3% reported in the literature [3-6]. Malignant transformation of teratoma is considered to occur in many tissue components; however, most teratomas are frequently identified 15 to 20 years before they transform; thus, available data on this issue are limited [7]. On the other hand, SCC arising from the ectoderm is known as the most frequently encountered secondary neoplasm constituting 80% of the malignant transformations; this may also be true for transformations of teratoma [8]. Other malignancies include adenocarcinoma, sarcoma, carcinoid, thyroid carcinoma, and melanoma [9]. Malignant transformation is frequently encountered in the postmenopausal period after the age of 55 years [10]. On the contrary, the present case was a menstruating female at the age of 43 years. Malignant transformation is also associated with the size of lesion and the risk increases in the lesions greater than 15 cm. Tumor markers such as carbohydrate antigen (CA 19-9) and SCC antigen may be elevated regardless of development of malignancy [7]. For radiological diagnosis, US is adequate for the majority of cases. However, US may be insufficient in the diagnosis, as teratomas could appear in a variety of forms. Fat content of any lesion could be measured easily by CT since it allows density measurement and has specific density values (60-100 HU) for fat. Moreover, the facts that CT is the method most sensitive to calcification, and uptake value of a lesion can be detected after administering intravenous contrast substance, have made CT the most valuable diagnostic tool for teratomas containing fat, bone, and cystic components. Fat, cystic area, and calcification are the main imaging findings of teratomas. Malignancy criteria for teratomas on imaging modalities include thick wall, solid component that uptakes contrast agent or papillary projection in the cyst, and accompanying peritoneal implant or lymphadenopathy. In the present patient, the mass met the malignancy criteria mentioned in the literature, as it was large and had solid component with contrast uptake. Unlike in the literature, the present patient had blood-fluid level indicating hemorrhage that showed diffusion restriction in the diffusion-weighted images. In the present patient, evaluation of the mass in terms of adjacent fatty plane invasion was suboptimal; however, not distinguishing the border of the mass from that of the uterus made malignant transformation suspicious. The definite diagnosis of the present patient, who underwent surgery based on the aforementioned findings, being certain malignancy according to the pathological report, suggested how important the small details in large masses could be. Recognizing the masses that are teratoma in nature and establishing their differential diagnosis are quite simple on MRI; however, it should be kept in mind that these masses, which are considered to be quite benign, may include malignant transformation, although rare. Even though it is difficult to diagnose early-stage cases based on imaging findings, evaluation from this aspect is extremely important for accurate surgical planning.

In brief, preoperative diagnosis of ovarian SCC arising from teratoma, which is usually asymptomatic, is difficult and manifests itself with non-specific abdominal pain. Radiological and intraoperative macroscopic findings are non-specific as compared to teratomas. Advanced age and relatively large ovarian masses are suspicious findings for teratomas and serum analyses may have a role in the diagnosis of SCC arising from teratoma. Multicenter studies are needed to develop further strategies in evaluating SCC arising from teratoma.

References

[1] Koonings P.P., Campbell K., Mishell D.R. Jr., Grimes D.A.: "Relative frequency of primary ovarian neoplasms: a 10-year review". *Obstet. Gynecol*., 1989, *74*, 921.

[2] Katsube Y., Berg J.W., Silverberg S.G.: "Epidemiologic pathology of ovarian tumors: a histopathologic review of primary ovarian neoplasms diagnosed in the Denver Standard Metropolitan Statistical Area, 1 July-31 December 1969 and 1 July-31 December 1979". *Int. J. Gynecol. Pathol.*, 1982, *1*, 3.

[3] Westhoff C., Pike M., Vessey M.: "Benign ovarian teratomas: a population-based case-control study". *Br. J. Cancer*. 1988, *58*, 93.

[4] Comerci J.T. Jr., Licciardi F., Bergh P.A., Gregori C., Breen J.L.: "Mature cystic teratoma: a clinicopathologic evaluation of 517 cases and review of the literature". *Obstet. Gynecol.* 1994, *84*, 22.

[5] Singh P., Yordan E.L., Wilbanks G.D., Miller A.W., Wee A.: "Malignancy associated with benign cystic teratomas (dermoid cysts) of the ovary". *Singapore. Med. J.* 1988, *29*, 30.

[6] Mekaru K., Kamiyama S., Masamoto H., Yagi C., Hirakawa M., Inamine M., *et al.*: "Squamous cell carcinoma arising in an ovarian mature cystic teratoma complicating pregnancy: a case report". *Arch. Gynecol. Obstet.* 2008, *278*, 287.

[7] Hackethal A., Brueggmann D., Bohlmann M.K., Franke F.E., Tinneberg H.R., Münstedt K.: "Squamous-cell carcinoma in mature cystic teratoma of the ovary: systematic review and analysis of published data". *Lancet. Oncol.* 2008, *9*, 1173.

[8] Kikkawa F., Nawa A., Tamakoshi K., Ishikawa H., Kuzuya K., Suganuma N., *et al.*: "Diagnosis of squamous cell carcinoma arising from mature cystic teratoma of the ovary". *Cancer.* 1998, *82*, 2249.

[9] Kelley R.R., Scully R.E.: "Cancer developing in dermoid cysts of the ovary. A report of 8 cases, including a carcinoid and a leiomyosarcoma". *Cancer.* 1961, *14*, 989.

[10] Allam-Nandyala P., Bui M.M., Caracciolo J.T., Hakam A.: "Squamous cell carcinoma and osteosarcoma arising from a dermoid cyst--a case report and review of literature". *Int. J. Clin. Exp. Pathol.* 2010, *3*, 313.

Corresponding Author:
F. BEYAZAL ÇELIKER
Sağlık Bakanlığı Recep Tayyip Erdoğan Üniversitesi
Tıp Fakültesi Eğitim Araştırma Hastanesi
Radyoloji Kliniği, Islampaşa Mahallesi
Şehitler Caddesi, No:74
53350 Rize (Turkey)
e-mail: fabece@yahoo.com