EJGO European Journal of Gynaecological Oncology

Effective therapeutic strategy for massive retroperitoneal hematoma after conization: arterial embolization and pigtail catheter insertion

Y. Jung, J.H. Ahn, R.Y. Kim, J.H. Yoon, S.J. Lee

Department of Obstetrics and Gynecology, St. Vincent's Hospital, College of Medicine, The Catholic University of Korea, Suwon (Korea)

Summary

The loop electrosurgical excision procedure (LEEP) is commonly used to remove cervical intraepithelial neoplasia (CIN) because of its safety profile and likelihood of fewer complications. The authors report a rare case of massive retroperitoneal bleeding combined with hypovolemic shock after LEEP conization. Vessel injury was detected by angiographic computed tomography (CT) and embolization of the uterine artery was successfully performed to achieve hemostasis by an intervention radiologist. A pigtail catheter was subsequently inserted for the drainage of the large retroperitoneal hematoma. The patient did not show any further hemorrhage and recovered safely from hypovolemic shock. Th present case demonstrates a successful multidisciplinary and minimal invasive approach to manage retroperitoneal bleeding with uterine artery embolization. Thus, it should be considered a potential treatment option for hemostasis.

Key words: Loop electrosurgical excision procedure (LEEP); CIN; Retroperitoneal hematoma; Pigtail catheter.

Introduction

Cervical intraepithelial neoplasia (CIN) may progress to a significant risk of developing invasive cervical cancer if not treated. Cervical cancer is the second most common cancer in women worldwide. In Korea, 3,760 new patients with cervical cancer were reported in 2013 and the mortality rate was 1.65 per 100,000 [1]. The incidence of cervical intraepithelial lesions has increased particularly in the reproductive age, a population requiring less aggressive forms of treatment. For this reason, cervical conization has been frequently used for young patients to date.

The various methods used for cervical conization include cold-knife cone biopsy, laser excisional conization, and the loop electrosurgical excision procedure (LEEP). LEEP is one of the most commonly used methods, because it is regarded as a fast and effective procedure that results in fewer complications; however, it should be carefully performed by an experienced operator [2, 3]. The most common complication is secondary hemorrhage. Other related complications include stenosis, infection, and perforation of the cervix, as well as hematometra and hematocervix [4].

In the present report, the authors describe an unusual case of massive hemorrhage and retroperitoneal hematoma after LEEP. The purpose of this case report was to emphasize the potential risks of severe intraoperative hemorrhage and the advantages of a minimal invasive approach to manage retroperitoneal bleeding with uterine artery embolization and resolution of hematoma using a pigtail catheter.

Case Report

A 29-year-old woman, gravida 2 and para 2, visited the emergency room with vaginal bleeding, wet skin, and anemic conjunctiva. She underwent LEEP for the treatment of CIN at a local clinic.The patient had severe left flank pain and very unstable blood pressure of 70/40 mmHg and pulse of 150 beats per minute. Cervix bleeding and multiple suture materials were found on the cervix through a vaginal speculum examination. The white blood cell, hemoglobin, and platelet count, activated partial thromboplastin time, and prothrombin time were 17,020/mm^3 (4,000–10,000/mm^3), 6.2 g/dL (12.0–16.0 g/dL), 82,000/mm^3 (150,000–450,000/mm^3), 72.3 seconds (22.0–37.0 seconds), and 22.4 seconds (10.0–14.0 seconds), respectively.

The present authors performed central venous catheterization of the right jugular vein with ultrasound-guided access. The vein was in a collapsed state and the central venous pressure was three cmH_2O because of hypovolemic shock. The patient was transfused with three units of packed red blood cells. The patient's hemodynamic state then stabilized: blood pressure of 100/60 mmHg and heart rate of 112 beats per minute.

Abdomen and pelvic angiographic computed tomography (CT) demonstrated active extravasation of contrast material from the branch of the intrauterine artery and retroperitoneal hematoma up to the pararenal space, about 33 × 18 cm in size (Figure 1). Injury to the cervical branch of the left uterine artery was revealed by angiographic CT (Figures 2b, c).

The emergent angiographic embolization was accessed from the femoral artery and coils were inserted at the cervical branch of the left uterine artery by an intervention radiologist. A pigtail catheter was inserted for the resolution of the large retroperitoneal hematoma two hours after embolization. The patient was closely observed in the intensive care unit for one day and was then transferred to the general ward after vital signs became sta-

Revised manuscript accepted for publication September 16, 2015

7847050 Canada Inc.
www.irog.net

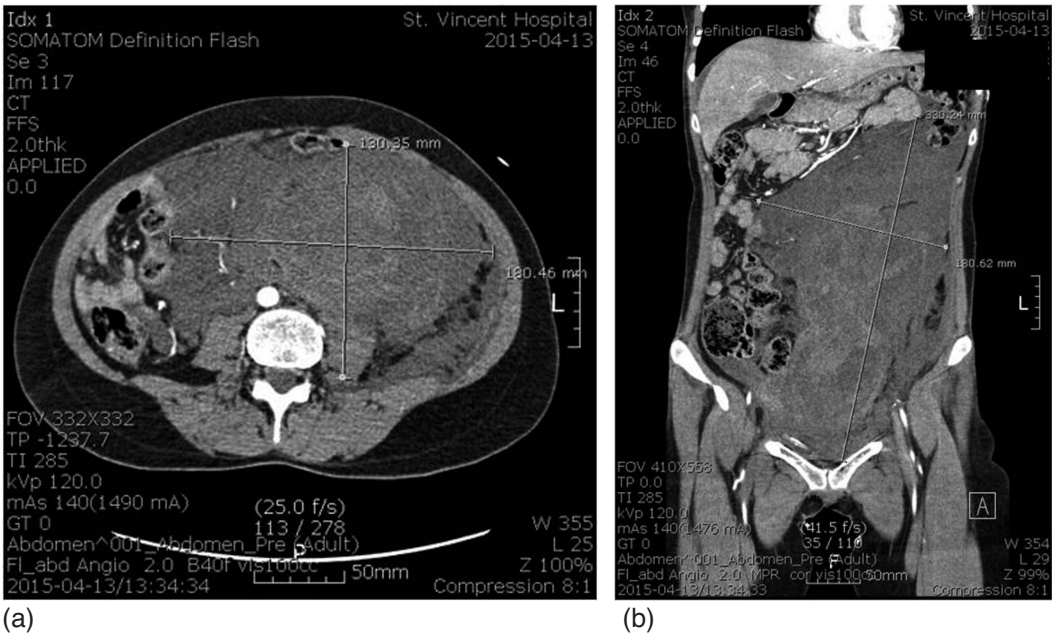

Figure 1. — Abdominal and pelvic angiographic computed tomography (CT) before treatment was used to visualize the retroperitoneal hematoma (about 33 × 18 cm in size) from both the axial (a) and coronary (b) views.

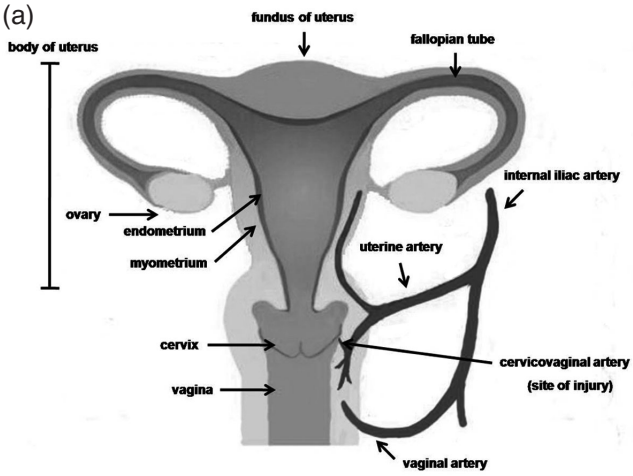

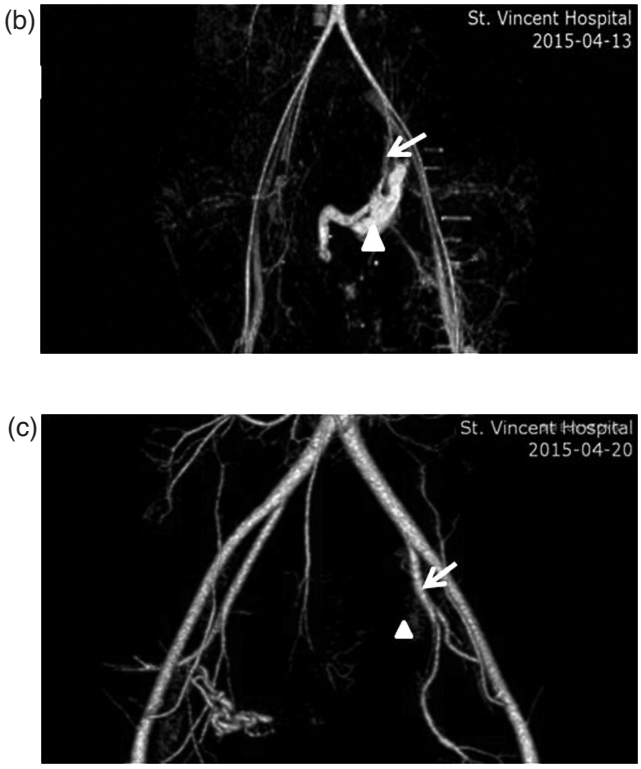

Figure 2. — A model of the injured site at the cervicovaginal artery (a). Angiographic three-dimensional reconstruction computed tomography before embolization. The arrowhead represents active extravasation at the cervicovaginal artery and the arrow shows the uterine artery (b). The arrowhead indicates the previous embolization site at the cervicovaginal artery and the arrow points to the internal iliac artery (c). a) Model for the cervicovaginal artery of uterus. b) Before treatment. c) After treatment.

bilized.

The total amount of drainage at the retroperitoneal hematoma was 3.7 L over three days. Finally, the retroperitoneal hematoma decreased to the size of 7.1 × 4.5 × 3.8 cm at transvaginal sonography (Figure 3). As a result, the patient recovered well and was subsequently discharged from hospital without any further complications.

Discussion

Life-threatening complications of post-conization have been reported as vaginal evisceration, sepsis, vesicovaginal fistula, as well as massive bleeding [5-8]. Injury at the cervical branch of the uterine artery is a rare complication of conization procedures with only three previous published cases [8-10].

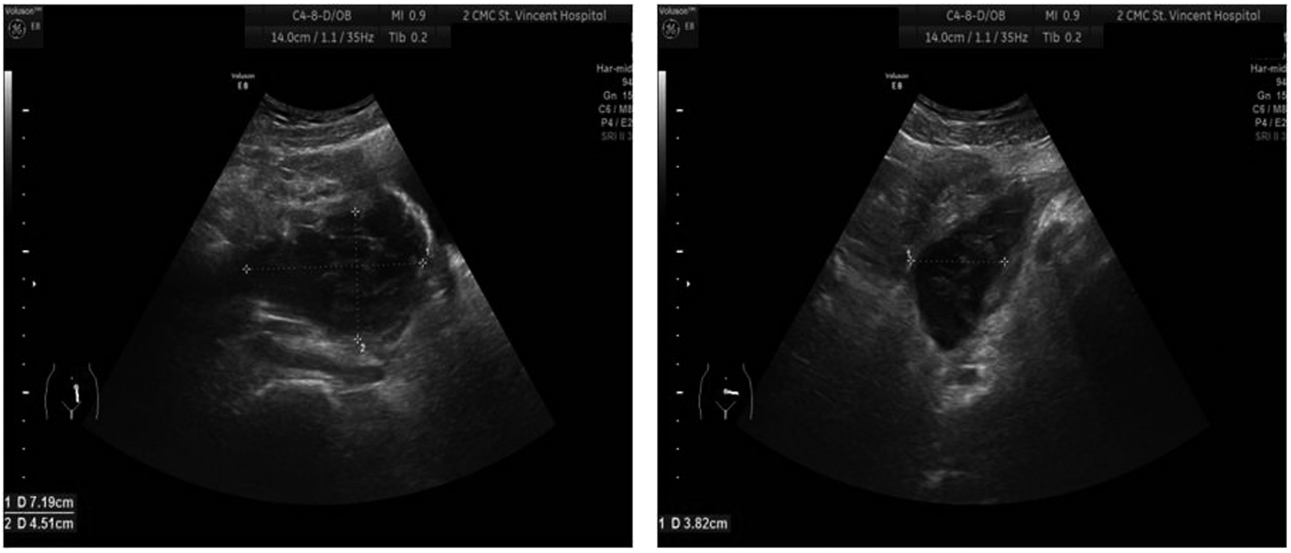

(a) (b)

Figure 3. — Ultrasonography visualizing the reduction in size of the hematoma to 7.1 × 4.5 × 3.8 cm from the sagittal (a) and axial (b) views after insertion of the pigtail catheter.

Table. 1. — *Clinical presentation and management of conization-induced bleeding.*

Author	Method	Cause	Treatment
Brown *et al.* [8]	Cold knife conization	Vaginal branch of uterine artery	Vaginal hysterectomy and celiotomy
Kurata *et al.* [9]	Laser conization	Descending branch of uterine artery	Ligation of the exposed blood vessel
Moon *et al.* [10]	Cold knife conization	Rupture of uterine arterial pseudoaneurysm	Arterial embolization
Zanati *et al*. [11]	Cold knife conization	Rupture of uterine arterial pseudoaneurysm	Arterial embolization
Jain *et al.* [12]	Cold knife conization	Rupture of uterine arterial pseudoaneurysm	Arterial embolization

Bleeding after conization can be divided into acute and delayed types (Table 1). The cause of acute bleeding is injury of the cervicovaginal branch of uterine artery during operation [8]. Most cases of delayed bleeding arise from the rupture of an arterial pseudoaneurysm at two weeks after the operation. The possibility of arterial pseudoaneurysm is closely proportional to the depth of conization. Therefore, the optimal depth of conization is generally recommended to be less than 3.0 cm [10-12].

Pseudoaneurysm is caused by inadequate sealing of a laceration or puncture of the arterial wall during conization. It is very difficult to diagnose a uterine artery pseudoaneurysm in advance. Recently, CT angiography or Doppler ultrasonography has been used to detect a pseudoaneurysm. Based on the imaging information, arterial embolization has been prophylactically performed with a success rate of 97% [10-12]. In contrast, acute bleeding has been managed with invasive treatments such as hysterectomy or vessel ligations as described in previous reports. Intraoperative bleeding in the present case was detected with CT angiography and treated with a minimal invasive arterial embolization, which is usually performed for delayed bleeding. In addition, the authors performed pigtail catheterization for the rapid drainage of the hematoma, in addition to a fast and effective embolization without any additional complications.

Angiographic CT is a very sensitive and specific examination used to diagnose arterial diseases such as hemorrhage, intimal irregularity, aneurysm, occlusion, dissection, and arteriovenous malformation. Its advantage is that it utilizes a non-invasive technique and confirms the presence of damaged vessels, collateral or variant anatomy, and can be visualized by three-dimensional reformatted images. With this information, uterine artery embolization can be efficiently performed for the treatment of postpartum hemorrhage, uterine fibroids, and uterine arteriovenous malformations [13].

Embolization access is usually achieved through a common femoral artery by the Seldinger technique and embolic agents such as gelatin sponge, coils, particles, glue, or a combination of the above can be released. Coils can control bleeding more rapidly, especially in large vessels. The coils can obstruct the vessel using proximal and distal embolization simultaneously to prevent retrograde bleeding through collateral blood flow [14]. It is considered a method that can be used with local anesthesia, minimal incision, less bleeding, and short recovery time [15]. Com-

plications after embolization are gonadal vein perforation, bladder wall necrosis, vaginal fistula, non-target embolization of the ovaries and endometrium, transient ovarian failure, ovarian vein thrombophlebitis, cardiac arrhythmia, infarction, and neurological damage [16, 17].

The internal iliac artery arises from the distal common iliac artery and leads to the uterine artery. The uterine artery is divided into a descending cervicovaginal artery and an ascending artery along the uterine margin. The cervical artery anastomoses with collateral branches, such as to the uterine artery, vaginal artery, and lower vesical artery. Approximately 67% of the blood supply of the uterine cervix is derived from uterine artery and 33% is provided by the vaginal and lower vesical artery (Figure 2a) [18]. In the present case, the cervicovaginal artery was occluded with coils at the both distal and proximal sites of the injury, to inhibit the retrograde flow from collateral vessels [14, 19].

In conclusion, angiography CT can provide accurate information about vessel injuries before embolization. The combination of arterial embolization and insertion of a hematoma-draining catheter can be suggested as an effective treatment option for LEEP-associated bleeding with minimal invasiveness and risk.

References

[1] Park Y., Vongdala C., Kim J., Ki M.: "Changing Trends in the Incidence (1999-2011) and Mortality (1983-2013) of Cervical Cancer in Republic of Korea". *Epidemiology and Health*, 2015, *37*, e2015024

[2] Chambo Filho A., Garbeloto E., Guarconi J.R., Partele M.P.: "Positive endocervical margins at conization: repeat conization or colposcopic follow-up? A retrospective study". *J. Clinical Med. Res.*, 2015, *7*, 540.

[3] Apgar B.S., Kaufman A.J., Bettcher C., Parker-Featherstone E.: "Gynecologic procedures: colposcopy, treatments for cervical intraepithelial neoplasia and endometrial assessment". *Am. Fam. Physician*, 2013, *87*, 836.

[4] Giannacopoulos K., Troukis E., Constandinou P., Rozis I., Kokonakis C., Giannikos L.: "Hematometra and extended vaginal haematoma after laser conization. A case report". *Eur.J. Gynaecol. Oncol.*, 1998, *19*, 569.

[5] Ghassani A., Andre B., Simon-Toulza C., Tanguy le Gac Y., Martinez A., Vidal F.: "Vaginal evisceration: an unexpected complication of conization". *Case Rep. Obstet. Gynecol.*, 2014, *2014*, 983682.

[6] Treszezamsky A.D., Molina Boero M.F., Mehta I.: "Cervical conization complicated by sepsis with lung and liver abscesses". *J. Low. Genit. Tract. Dis.*, 2010, *14*, 130.

[7] Wall L.L., Khan F., Adams S.: "Vesicovaginal fistula formation after cervical cerclage mimicking premature rupture of membranes". *Obstet. Gynecol.*, 2007, *109*, 493.

[8] Brown C.F., Mashini I.S., Turner W.A., Gallup D.G.: "Retroperitoneal hematoma: an unusual complication of cold knife conization of the cervix". *Obstet. Gynecol.*, 1986, *68*, 66s.

[9] Kurata H., Aoki Y., Tanaka K.: "Delayed, massive bleeding as an unusual complication of laser conization. A case report". *J. Reprod. Med.*, 2003, *48*, 659.

[10] Moon G., Jeon S., Nam K.H., Choi S., Sunwoo J., Ryu A.: "Pseudoaneurysm of uterine artery causing intra-abdominal and vaginal bleeding after cervical conization". *Obstet. Gynecol. Sci.*, 2015, *58*, 256.

[11] Zanati J., Sergent F., Clavier E., Marpeau L.: "Late post-conization hemorrhage and false aneurysm of the uterine pedicle". *J. Gynecol. Obstet. Biol. Reprod. (Paris)*, 2006, *35*, 725. [Article in French]

[12] Jain J., O'Leary S., Sarosi M.: "Uterine artery pseudoaneurysm after uterine cervical conization". *Obstet. Gynecol.*, 2014, *123*, 456.

[13] Umezu T., Iwase A., Ota T., Suzuki K., Nakagawa A., Nakahara T., *et al.*: "Three-dimensional CT angiography is useful for diagnosis of postabortion uterine hemorrhage: 3 case reports and review of the literature". *J. Minim. Invasive Gynecol.*, 2010, *17*, 246.

[14] Bauer J.R., Ray C.E.: "Transcatheter arterial embolization in the trauma patient: a review". *Semin. Intervent. Radiol.*, 2004, *21*, 11.

[15] Firouznia K., Ghanaati H., Jalali A.H., Shakiba M.: "Uterine artery embolization for treatment of symptomatic fibroids: a review of the evidence". *Iran. Red. Crescent Med. J.*, 2013, *15*, e16699.

[16] Soyer P., Dohan A., Dautry R., Guerrache Y., Ricbourg A., Gayat E., *et al.*: "Transcatheter Arterial Embolization for Postpartum Hemorrhage: Indications, Technique, Results, and Complications". *Cardiovasc. Intervent. Radiol.*, 2015.

[17] Lopera J., Suri R., Kroma G.M., Garza-Berlanga A., Thomas J.: "Role of interventional procedures in obstetrics/gynecology". *Radiol. Clin. North Am.*, 2013, *51*, 1049.

[18] Palacios Jaraquemada J.M., Garcia Monaco R., Barbosa N.E., Ferle L., Iriarte H., Conesa H.A.: "Lower uterine blood supply: extrauterine anastomotic system and its application in surgical devascularization techniques". *Acta Obstet. Gynecol. Scand.*, 2007, *86*, 228.

[19] Pinto A., Niola R., Brunese L., Pinto F., Losco M., Romano L.: "Postpartum hemorrhage: what every radiologist needs to know". *Curr. Probl. Diagn. Radiol.*, 2012, *41*, 102.

Corresponding Author:
S. J. LEE, M.D.
Department of Obstetrics and Gynecology
St. Vincent's Hospital, College of Medicine
The Catholic University of Korea
93 Jungbu-daero, Paldal-gu
Suwon, Gyeonggi-do 442-723 (Korea)
e-mail: orlando@catholic.ac.kr