EJGO European Journal of Gynaecological Oncology

Negative pressure wound treatment (NPWT) in vulva and groin wounds in gynaecologic oncology

N.A.A. Wahab, F.A. Saadeh, A. Wong, N. Gleeson

Gynaecologic Oncology Division, Gynaecology Department, St James's Hospital, Dublin (Ireland)

Summary

Secondary healing of complicated vulvar and groin wounds is a major challenge due to its moist condition and at risk of contamination by colonic flora. Vacuum assisted closure is the controlled application of sub-atmospheric pressure to the local wound environment using a sealed dressing connected to a vacuum pump. *Materials and Methods:* The NPWT consists of an open-pore polyurethane ether foam sponge, an adhesive cover, fluid collection system, and suction pump that generates negative pressure. Direct application of sponge to blood vessels, bone, nerves or intact skin is avoided. The dressing and tubing are changed every 48-72 hours. *Results:* Eight patients had NPWT following the vulva and/or groin surgery. Pain during removal of the sponge was the main adverse event requiring narcotic analgesia. All wounds healed completely. One patient is dead of disease progression. Others are alive without disease at four to 48 months. Conclusion: Wound breakdown in vulvar and groin surgery is an infrequent occurrence because of the rarity of full radical excision for vulva cancer and infralevator pelvic exenterative surgery. The present experience with NPWT was favourable.

Key words: Vulva and groin wounds; Negative pressure wound treatment.

Introduction

Secondary healing of complicated vulvar and groin wounds is a major clinical challenge. The vulva is moist and at risk of contamination by colonic flora. In gynecologic oncology practice, these wounds arise from breakdown after excision of vulvar cancers and following reconstruction of the vulvar vestibule and vagina in exenterative surgery. Slow wound healing causes pain, protracted hospitalisation and a lowering of patient and staff morale.

Wound breakdown after surgical excision of cancer of the vulva is less common since radical vulvectomy with en bloc inguinofemoral lymphadenectomy has been superseded by modified radical excision of the vulvar cancer and separate groin incisions [1-3] and more recently with the avoidance of full lymphadenectomy by substitution of sentinel lymphadenectomy in selected cases [4-6]. Full groin dissection is still standard of care for larger vulvar cancers and when lymph nodes are suspicious or confirmed to contain metastases. Flap reconstruction of large vulvar defects improves primary healing rates and various techniques have been described [7-10]. Patients with vulvar cancer are often older and may have multiple co-morbidities, making them susceptible to adverse post-operative outcomes [11]. Full groin node dissection is followed by a large outpouring of lymph into the subcutaneous space (lymphocysts). When the vulvar wound is anterior the lymph may track caudally under the skin bridge and exit through the vulvar wound. If the groin and vulvar wounds dehisce and the skin bridge undergoes necrosis, the resulting wound is similar to the butterfly of the en-bloc historical radical surgery. Reconstruction of the vagina and vestibule is a key component of pelvic exenterative surgery for genital tract and anorectal malignancies and many methods are described using skin, fascia, muscle, and bowel segments [12-17]. Reconstruction fills the pelvic floor and enhances physical, psychological, and sexual recovery. All techniques have complications specific to the donor site and risk of partial or complete flap necrosis. Separation of wound edges at the site of reconstruction can result from flap necrosis or retraction of the transposed skin away from the native vulvar labial skin.

Traditionally, secondary healing of vulvar and groin wound after breakdown was assisted by packing and debridement. Packing was with saline or methylcellulose hydrofibre to promote granulation tissue. Silver impregnation [18] of the wound pack and topical honey [19] are used for their bactericidal effect. NPWT or vacuum assisted closure is the controlled application of sub-atmospheric pressure to the local wound environment using a sealed dressing connected to a vacuum pump set at pressures (usually at 125 mmHg), which are optimal for wound healing. NPWT was first described in 1993 by Fleischmann *et al.* [20] in open fractures. Gynaecological surgeons are familiar with its application in the treatment of complicated abdominal wounds [21-24] and its emerging role in prophylaxis in high risk wounds with application after primary closure of abdominal wounds, so called incisional NPWT, which has

Revised manuscript accepted for publication May 27, 2015

7847050 Canada Inc.
www.irog.net

been shown to reduce surgical site infection and wound failure rates [25-27]. Published series on wound failure or dehiscence include its use in complicated gynecologic oncology wounds of abdomen when conventional therapy fails [21, 24]. The application of NPWT presents a special challenge in the groin where large vessels need protection and in the vulvar area where obliteration of the urethra and vagina and sometimes the anal orifice may be necessary to maintain an airtight seal. Riebe *et al.* [28] included one case report on primary application to an open groin wound following inguinofemoral lymphadenectomy. Shvartsman *et al.* [29] used NPWT to temporize on wound closure following wide skinning vulvectomy pending histopathological assessment of margins for Paget's disease and prior to split skin grafting. Narducci *et al.* [30] applied NWPT to open primary wounds in 30 women undergoing vulval excision of lesions > 40 cm^3 and found the time to cicatrisation was reduced by 16 days compared to conventional wound packing in a series on elective healing by secondary intention. Many gynecologic oncologists, the present group included, chose primary closure assisted by flap reconstruction over healing by secondary intention in women undergoing substantial vulvar excisions. The series by Schimp *et al.* [21] includes five women with complicated vulvar wound failures. Use of NPWT has not been reported previously for wound failure after vulvovaginal reconstruction in infralevator pelvic exenterative surgery. The present authors report their experience with NPWT in the secondary healing of vulval and groin wounds in women undergoing radical vulvar cancer surgery and pelvic exenteration in order to highlight its value and caveats arising.

Materials and Methods

The present authors started using use negative pressure wound therapy in 2008 at their institution, a tertiary gynecologic oncology/ pelvic surgery center with 300 new cancer referrals per annum. Their annual case work includes an average 24 vulvar cancers and nine infralevator pelvic exenterations. They introduced sentinel node mapping for vulvar cancer in 2011, but less than one-third of their patients are eligible because they function as a national referral center, so their case work includes a substantial number of locally advanced and recurrent vulvar cancers. Separate incisions for vulvar and full groin dissections are standard of care for primary surgery of lesion > four cm. Unilateral lymphadenenctomy is performed for small lateral lesions. Since 2010 the present authors have used NPWT to assist the healing of vulvar and groin wounds that dehisced. Their unit has specialist wound nurse therapists and all patients are nursed in a dedicated oncology surgical ward.

Two NPWT vacuum assisted devices are available commercially. The NPWT pack consists of an open-pore polyurethane ether foam sponge, a semiocclusive adhesive cover, fluid collection system, and suction pump. The following steps are involved in placing the device. The edges at the skin wound are protected with strips of hydrocolloid wafer. The wound is packed with a cut-to-fit ether foam sponge and overlaid with the adhesive cover. This adhesive cover is perforated at a single point over the foam sponge and a suction port with tubing is placed. The tubing extends to a disposable collection canister in the portable suction machine. The suction device generates negative pressures of 50 to 175 mmHg. Bilateral wounds are packed separately with foam sponge and two suction ports drain to a single suction pump. Direct application of foam sponge to blood vessels, bone, nerves or intact skin is avoided. The porous nature of the polyurethane foam sponge evenly distributes subatmospheric pressure to the surface of the wound, and provides a conduit for fluid removal from the wound surface to the collection system. The dressing and tubing are changed every 48-72 hours. Patient consent was received to use clinical details, photographs, radiological imaging, and histopathology for the purpose of medical education.

Results

Table 1 shows the patient demographic, disease, co-morbidities, surgery, interval to wound breakdown, description of wound, and outcomes with NPWT. Eight patients have had NPWT following the breakdown of vulvar and/or groin wounds. One patient had lymphadenenctomy alone. Seven patients had vulvar surgery, five in treatment of primary (four) or recurrent (one) squamous vulvar cancer. Two patients undergoing infralevator pelvic surgery had vestibulectomy (one) or vestibulectomy and posterior radical vulvectomy (one). Their transposed flaps separated without necrosis from the vulvar skin resulting in deep tissue deficit extending into the ischiorectal and paravaginal spaces.

At the outset, the present authors instituted NPWT only when results from conventional packing and debridement seemed suboptimal: Patients #1 and #2 had saline-soaked gauze or sodium carboxymethyl cellulose dressings for ten days each. Thereafter, NPWT was started within 24 hours of wound dehiscence when it was appropriate to do so. In the two cases with groin dehiscence, the authors were confident that there was sufficient granulation tissue or intact fascia over the femoral vessels. Patient #8 had wound disruption after reconstruction of vestibule and neovagina on postoperative day 5 at which time a space leading into the pelvis was easily palpable at the apex of the neovaginal flap. Saline soaked gauze, then carboxymethyl cellulose packing was instituted until the authors were confident that the access to the pelvic cavity was sealed by granulation tissue. Patient #7 had bilateral separation of lotus petal pudendal flaps at their lateral margin on the line of suture to skin of the posterior vestibule on postoperative day 7. The neovagina appeared well healed at the apex. She had also had omentoplasty with transposition of a bulky omental flap into her pelvis. NPWT foam sponge was inserted bilaterally, a urinary catheter placed, and vacuum applied across the vestibule. She complained of severe lower abdominal and pelvic pain and nausea immediately after the application which raised concern that the neovagina was still open into the pelvic cavity. The NPWT was revised to separate lateralised dressings (and two suction machines), thereby avoiding negative pressure to the vestibule and there was no reactivation of her symptoms.

Table 1 – *NPWT in secondary healing of wounds after excision of vulvar cancer and flap dehiscence after pelvic infralevator exenteration.*

Patient	Age (years)	Cancer diagnosis	Co-morbidities	Index surgery	Wound failure dehiscence POD	Extent of dehiscence width(w)/ depth (d)	Commenced NPWT	Healing complete	Current status
#1	72	Vulal SCC, Stage IIIC	Obesity, Type 2 diabetes, hypertension	Anterior rad vulvectomy, bilateral groin LND	Groins POD 18. skin bridge necrosis POD 22, vulva POD 23	25x6w 6.5d	POD 28	POD 60	A/NED 48 months
#2	78	Vulval SCC Stage IB	Obesiy, Type 2 diabetes, atrial Fibrillation	Rad vulvectomy, bilateral groin LND	Anterior vulva POD 4	5x4w 3.5d	POD 14	POD 36	A/NED 45 months
#3	84	Vulval SCC Stage IB Recurrent	Hypertension, peripheral vasculopathy, atrial fibrillation	Right vulvectomy	Right vulva POD5	5x9w 2d	POD 12	POD 21	A/NED 44 months
#4	42	Vulval SCC Stage IIIC, progressive disease in groin on adjuvant XRT after radical vulvectomy Bilateral Groin LND	Depression	Radical excision of groin recurrence	Right Groin POD 7	14x8w 3d	POD 8	POD 21	DOD 9 months
#5	56	Vulval SCC Stage IB	None	Rad vulvectomy, bilateral groin LND	Left vulva POD 6	8x6w 2 d	POD 6	POD 19	A/NED 30 months
#6	72	Vulval SCC Stage II	Obesity	Rad vulvectomy, bilateral groin LND	Anterior vulva POD 7	6x5w 4.5 d	POD 7	POD 20	A/NED 21 months
#7 POD 7	56 POD 48	Vaginal SCC Stage IVA, prior endometrial cancer surgery and XRT	A/NED	None exenteration/omentopexy/ flap reconstruciton of vagina and vestibule	Infralevator total pelvic 6x4w 2.5d	Bilateral flap margins POD7		3 months	6x4w 8d
#8	47	Adenocarcinoma in Crohn's fistula of perineum	Multiple sclerosis, Crohn's disease	Infralevator posterior pelvic exenteration/ posterior vulvectomy flap reconstruction	Unilateral flap margin POD 5	8x6w 12d	POD 14	POD 36	A/NED 8 months

POD: postoperative day; LND: lymphadenectomy; A/NED: alive/no evidence of disease; DOD: dead of disease.

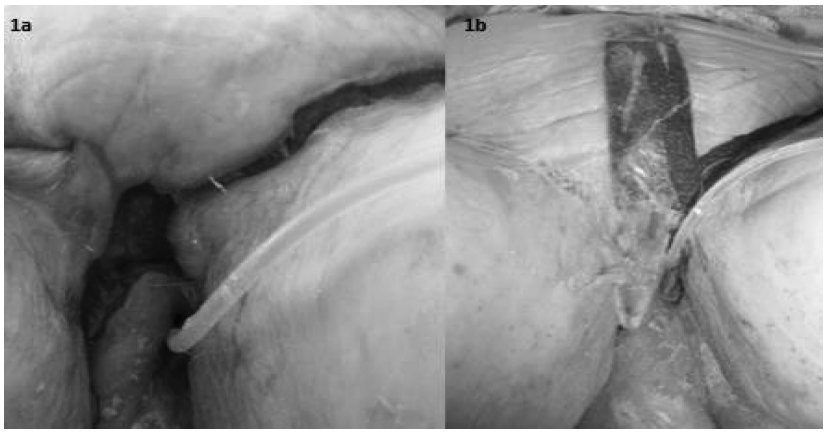

Figure 1. — (Patient #1) A: Groin and vulvar wound breakdown with skin bridge necrosis. B: NPWT in progress. The suction port, here located on the abdomen, can be placed at a distance from the wound. The additional strip of foam in the midline of the abdomen is separated from the underlying skin by a barrier membrane.

A nurse wound therapists described the vulvar dressings as "difficult" but they were successful in their dressing placements in all cases. Figure 1 shows a NPWT dressing in place for patient #1 and demonstrates a very satisfactory placement in a wound that incorporated the disruption of bilateral groins and anterior vulva. The present authors found stoma paste underneath and an overlay with strips of hydrocolloid wafer at the edges of the dressing was a useful adjunct to sealing the adhesive barrier over the vulvar wounds. All but one patient (#4) required urinary catheter as the vulvar wound dressings required application of negative pressure across the vestibule or the application was

too close to the urethral orifice (#1). Pain during removal of the foam sponge was the main adverse event reported by patients. They all required narcotic or equivalent analgesia for vulvar dressing changes. The patient with groin wound alone had acetominophen/codeine analgesia. All vulvar wounds were nursed in hospital while NPWT was in place. Patient #4 with groin wound was discharged to domiciliary nursing care with NPWT.

Patients #1 and #2 were bothered my malodorous discharge prior and were pleased that it resolved with the institution of NPWT. In the vulvar cancers (patients #1-6) vulvar wounds ranged from two to 6.5 cm deep and on average eight cm wide. Patient # 1 in whom there was a continuous disruption of wound from groins to vulva due to skin bridge necrosis had a wound disruption of 25 cm in width. The present authors observed the granulation tissue at the base and sides grows at an estimated 0.5 cm per day and the negative pressure draws the sides of the wound together.

The granulation tissue is very clean. The wounds heal to a narrow superficial sinus at which time a gauze/wick dressing can be substituted. All wounds healed completely. No lymph drained percutaneously once the groin wounds healed to a narrow sinus. Two patients had antibiotics during NPWT: one for urinary tract infection (#2) and one lower respiratory tract infection (#3). One patient is dead of disease progression: Patient #4 had salvage surgery for early, clinically aggressive groin relapse in Stage IIIC1 disease during the first week of adjuvant radiotherapy. She developed hepatic and pulmonary metastases and succumbed to her disease six weeks after starting palliative chemotherapy. All others are alive without disease at 4 to 48 months after surgery.

Discussion

Systemic disease and local wound factors contribute to delay in wound healing. Vulvar carcinoma is a disease of the elderly who often have significant multiple co-morbidities and vulvectomy has a particularly high risk of wound breakdown [6]. A triple incision technique is employed but some wounds undergo substantial breakdown. Skin bridge necrosis results in a continuous wound from groins to perineum. Patients undergoing exenterative surgery have usually had radiotherapy. Vulvar wounds are moist and in an area contaminated by colonic bacteria. The wetness is increased by retrograde lymph flow when groin or pelvic lymphadenectomy has been performed. Wound breakdown is debilitating and impacts negatively on bed usage in the present cancer institutions. Negative pressure therapy (NPWT) probably assists healing by promoting an increase in blood flow, promotion of angiogenesis, reduction in the wound surface area, modulation of the inhibitory contents in the wound fluid, and the induction of cell proliferation [22]. It prevents slough from accumulating in the wound and the granulation tissue looks clean and healthy.

Clinical experience with NPWT is expanding. Many of the published series focus its prophylactic use as incisional NPWT in the healing of at risk wounds by after primary closure [25-27]. Narducci *et al.* [30] assessed NPWT in vulvar wounds left open to heal by secondary intention. Experience with the technique in treatment of wound failure in the vulva and groin is limited [21]. Initially, the present authors instituted NPWT only when the results from conventional packing and debridement seemed suboptimal. Encouraged by successful salvage in those cases, thereafter, they intervened earlier with application of NPWT within 24 hours of wound dehiscence. They achieved closure in five vulvar and one groin wound failure with NPWT after vulvar cancer surgery in median 12.5 days when NPWT was instituted immediately and in median 27 days when NPWT was instituted only after conventional wound care was deemed to have failed. However, one patient in the latter group had the largest wound extending from the groin to the vulva. The authors recommend early NPWT in vulvar and groin wound breakdown.

Cresti *et al.* [31] described the successful use of NPWT in the healing of a perineal wound after abdomino-perineal resection of anorectal cancer in a male patient. That patient had omentoplasty and pelvic peritoneal closure at his laparotomy [32]. The negative pressure was therefore applied below the levator plate in a pelvis that was effectively sealed off from the abdominal space. By comparison, in gynecologic exenterative surgery, an omental flap may be transposed to the pelvis but there is no pelvic peritoneum left to achieve closure from the abdominal cavity. Patient #7 appeared to have healed the apex of the fasciocutaneous neovagina but she developed pelvic and abdominal pain and nausea on application of NPWT that suggest an incomplete seal. Her fasciocutaneous flaps had retracted bilaterally from the vulval skin, so separate lateral appliances worked for her. Patient #8 had a palpable tract leading to the pelvic cavity and ischorectal fossa and her application of NPWT was delayed until that tract was healed as there was no way the vacuum could be established for her without a full airtight seal across her vestibule. Both patients with vulvar wound breakdown after exenterative surgery healed completely in 22 to 41 days after application of NPWT

The challenge of placement of the NPWT on vulvar wounds is difficult to measure. As nurse wound therapists were experienced in the use of NPWT in abdominal and other body wall and limb wounds and were enthusiastic to extend their skill set to the care vulvar wounds. Difficulties with the contour and moisture of the vulvar skin were surmountable. The dressings were extended across the vestibule in order to obtain an airtight seal. Stoma paste underneath and overlaid strips of hydrocolloid wafer to reinforce the edges of the dressing were useful adjuncts to sealing the adhesive barrier onto the moist skin. Patients needed narcotic analgesia for changes of vulvar dressings.

On the other hand, the dressing changes every 48-72 hours are less frequent than with conventional packing and thereby reduce the demand on nursing time and patients' discomfort. Patient mobility was enhanced by the portability of the suction canisters. Satisfactorily, there were no wound infections and no debridements were needed.

Standard NPWT is contraindicated when blood vessels, bones or nerves are exposed and a layer of protectant of petroleum gauge or mesh is interposed between these structures and the sponge foam. Skin contact with the foam sponge beyond the edges of a wound induces growth of granulation tissue on the intact skin and the authors used a trim of hydrocolloid wafer at the wound edge successfully to avoid this. The manufacturers also counsel against its use when there is malignancy in the wound or enterocutaneous fistula. To this list the authors would add a caution that the application should avoid generating negative pressure in the cavity of the vulvar vestibule and neovagina following exenteration until the healing of the pelvic floor is complete. One of the present patients developed severe pelvic pain and gastrointestinal symptoms that the authors attributed to the transmission of negative pressure to the pelvis and abdomen. Her symptoms resolved quickly when the application was corrected.

The present authors were concerned that NPWT might promote continued lymph flow from groin wounds but found, on the contrary, that all wounds were dry at completion of healing. They had no cancer recurrences that they can relate to NPWT. The patient who died of progressive vulvar cancer developed distant metastases. She had Stage III disease (groin node metastases) at presentation and the index surgery was an attempt to salvage an apparent isolated early groin recurrence. She died of distant metastases.

Conclusion

Wound breakdown in vulvar and groin surgery is an infrequent occurrence because of the rarity of full radical excision for vulvar cancer and infralevator pelvic exenterative surgery. The present authors' experience with NPWT in this group of eight patients was favourable. They emphasise safety aspects, namely, the avoidance of direct placement of the foam sponge over vessels, nerves, bone, and intact skin. They highlight the need to ensure that the pelvic floor is fully sealed before applying negative pressure to the vestibule and neovagina after infralevator exenterative surgery.

Acknowledgement

The authors thank the nursing staff at the gynecologic oncology unit for their support.

References

[1] DiSaia P.J., Creasman W.T., Rich W.M.: "An alternative approach to early cancer of the vulva". *Am. J. Obstet. Gynecol.*, 1979, *133*, 825.

[2] Hoffman M.S., Roberts W.S., Lapollo J.P., Cavanagh D.: "Recent modifications in the treatment onf invasive squamous carcinoma of vulva". *Obstet. Gynaecol. Surv.*, 1989, *58*, 227.

[3] Ansink A.C., van Tinteren H., Aartsen E.J., Heintz A.P.: "Outcome, complications and follow-up in surgically treated squamous cell carcinoma of the vulva 1956-1982". *Eur. J. Obstet. Gynecol. Reprod. Biol.*, 1991, *42*, 137.

[4] Levenback C.: "Intraoperaive lymphatic mapping and sentinel node identification: gynecologic applications". *Cancer Res.,* 2000, *157*, 150.

[5] Van der Zee A.G., Oonk M.H., De Hullu J.A., Ansink A.C., Vergote I., Verheijen R.H., *et al.*: "Sentinel node dissection is safe in the treatment of early-stage vulvar cancer". *J. Clin. Oncol.,* 2008, *26*, 884.

[6] Wills A., Obermair A.: "A review of complications associated with the surgical treatment of vulvar cancer". Gynecol. Oncol., 2013, *131*, 467.

[7] Burke T.W., Morris M., Levenback D.M., Wharton J.T.: "Closure of complex vulvar defects using local rhomboid flaps". *Obstet. Gyneol.*, 1994, *84*, 1043.

[8] Thomas S.S., Chenoy R., Fielding J.W., Rollason T.P., Jordan J.A., Braca A.: "Vulvoperineal reconstruciton afeter excision of anogenital multifocal intraepithelial neoplasia ("MIN")". *Brit. J. Plastic Surgery*, 1996, *49*, 539.

[9] Gleeson N.C., Baile W., Roberts W.S., Hoffman M.S., Fiorica J.V., Finan M.A., *et al.*: "Pudendal thigh fasciocutaneous flaps for vaginal reconstruction in gynecologic oncology". *Gynecol. Oncol.*, 1994, *54*, 269.

[10] Argenta P.A., Lindsay R., Aldridge R.B., Siddiqui N., Burton K., Telfer J.R.C.: "Vulval reconstruction using the "lotus-petal" fasciocutaneous flap". *Gynecol. Oncol.*, 2013, *131*, 726.

[11] Barton D.P.: "The prevention and management of treatment related morbidity in vulval cancer". *Best Pract. Res. Clin. Obstet. Gynecol.*, 2003, *17*, 683

[12] Smith H.O., Genesen M.C., Runowicz C.D., Goldberg G.L.: "The rectus abdominis myocutaneous flap: modifications, complications, and sexual function". *Cancer*, 1998, *83*, 510.

[13] Mirhashemi R., Averette H.E., Lambrou N., Penalver M.A., Mendez L., Ghurani G., *et al.*: "Vaginal reconstruction at the time of pelvic exenteration: a surgical and psychosexual analysis of techniques". *Gynecol. Oncol.*, 2002, *87*, 39.

[14] Kusiak J.F., Rosenblum N.G.: "Neovaginal reconstruction after exenteration using an omental flap and split-thickness skin graft". *Plast. Reconstr. Surg.*, 1996, *97*, 775.

[15] Soper J.T., Secord A.A., Havrilesky L.J., Berchuck A., Clarke-Pearson D.L.: "Rectus abdominis myocutaneous and myoperitoneal flaps for neovaginal reconstruction after radical pelvic surgery: comparison of flap-related morbidity". *Gynecol. Oncol.*, 2005, *97*, 596.

[16] D'Souza D.N., Pera M., Nelson H., Finical S.J., Tran N.V.: "Vaginal reconstruction following resection of primary locally advanced and recurrent colorectal malignancies". *Arch. Surg.*, 2003, *138*, 1340.

[17] McArdle A., Bischof D.A., Davidge K., Swallow C.J., Winter D.C.: "Vaginal reconstruction ffollowing radical surgery for colorectal malignancies: a systematic review of the literature". *Annal. Surg. Oncol.*, 2012, *19*, 3933.

[18] Castellano J.J., Shafii S.M., Ko F., Donate G., Wright T.E., Mannari R.J., *et al.*: "Comparative evaluation of silver-containing antimicrobial dressings and drugs. Int Wound J 2007;4(2): 114-22

[19] Simon A., Traynor K., Santos K., Blaser G., Bode U., Molan P.: "Medical honey for wound care – still the "last resort"?" *Evid. Based Complement Alternat. Med.*, 2009, *6*, 165.

[20] Flesichmann W., Strecker W., Bombelli M., Kinzl L.: "Vacuum sealing as treatment of soft tissue damage in open fractures". *Unfallchirurg*, 1993, *96*, 488.

[21] Schimp V.L., Worley C., Brunello S., Levenback C.C., Wolf J.K., Sun C.C, et al.: "Vacuum-assisted closure in the treatment of gynecologic oncology wound failures". *Gynecol Oncol.*, 2004, *92*, 586.
[22] Moues C.M., Heule F., Hovius S.E.: "A review of topical negative pressure therapy in wound healing: sufficient evidence?" *Am. J. Surg.*, 2011, *201*, 54.
[23] Mullner T., Mrkonjic L., Kwasny O., Vecsei V.: "The use of negative pressure to promote the healing of tissue defects: a clinical trial using the vacuum sealing technique". *Br. J. Plast. Surg.*, 1997, *50*, 194.
[24] Argenta P.A., Rahaman J., Gretz H.F., Nezhat F., Cohen C.J.: "Vacuum-assisted closure in the treatment of complex gynecologic wound failures". *Obstet. Gynecol.*, 2002, *99*, 497.
[25] Condé-Green A., Chung T.L., Holton L.H. 3rd, Hui-Chou H.G., Zhu Y., Wang H., Zahiri H., Singh D.P.: "Incisional negative-pressure wound therapy versus conventional dressings following abdominal wall reconstruction: a comparative study". *Ann. Plast. Surg.*, 2013, *71*, 394.
[26] Vargo D.: "Negative pressure wound therapy in the prevention of wound infection in high risk abdominal wound closures". *Am. J. Surg.*, 2012, *204*, 1021.
[27] Blackham U., Farrah J., McCoy T., Schmidt B., Shen P.: "Prevention of surgical site infections in high-risk patients with laparotomy incisions using negative-pressure therapy" *Am. J. Surg.*, 2013, *205*, 647.
[28] Riebe E., Ohlinger R., Thele F., Kohler G.: "Polypropylene mesh implantation in combination with vacuum-assisted closure in the management of metastatic or locally recurrent vulvar cancer: case report and review of literature". *Int. J. Gynecol. Cancer*, 2010, *20*, 179.
[29] Shvartsman H.S., Langstein H., Worley C., Malpica A., Ramondetta L.M.: "Use of a vacuum-assisted closure device in the treatment of recurrent Paget's disease of the vulva". *Obstet. Gynecol.*, 2003, *102*, 1163.
[30] Narducci F., Samouelian V., Marchaudon V., Koenig P., Fournier C., Phalippou J., Leblanc E.: " Vacuum-assisted closure therapy in the management of patients undergoing vulvectomy". *Eur. J. Obstet. Gynecol. Reprod. Biol.*, 2012, *161*, 199.
[31] Cresti S., Ouaissi M., Sielezneff I., Chaic J.B., Pirro N., Berthet B., *et al.*: "Advantage of vacuum assisted closure on healing of wound associated with omentoplasty after abdominoperineal excision: a case report". *World J. Surg. Oncol.*, 2008, *6*, 136
[32] De Broux E., Parc Y., Rondelli F., Dehni N., Tiret E., Parc R.: "Sutured perineal omentoplasty after abdominoperineal resection for adenocarcinoma of the lower rectum". *Dis. Colon Rectum*, 2005, *48*, 476.

Address reprint requests to:
N. GLEESON M.D., MRCOG
Consultant Gynaecologic Oncologist
Gynaecologic Oncology Division
Gynaecology Department, St James's Hospital-James's Street Street, Dublin 8
Dublin (Ireland)
e-mail: noreengleeson@dubgyn.org