

REVIEW

Surgical management in the pelvis for patients with advanced ovarian cancer

Andrea Giannini^{1,2,*}, Kristina A. Butler^{1,*}

¹Department of Medical and Surgical Gynecology, Mayo Clinic, Phoenix, AZ 85054, USA

²Department of Clinical and Experimental Medicine, University of Pisa, 56126 Pisa, Italy

***Correspondence**

Butler.Kristina@mayo.edu

(Kristina A. Butler);

Giannini.Andrea@mayo.edu

(Andrea Giannini)

Abstract

In 70% of women, the diagnosis of epithelial ovarian cancer is at the advanced stage, and patient survival is negatively correlated with residual disease diameter in many series and meta-analyses. This evidence emphasizes the role of maximal cytoreduction in this particular oncologic population. In patients with disrupted pelvic anatomical conditions such as the so-called “frozen pelvis”, the surgeons are called to a significant effort to achieve the maximal cytoreduction. Unlike colorectal cancer, malignant ovarian cells tend to invade superficial abdominal surfaces disseminating within the peritoneal cavity, thus involving the peritoneum layer and the omentum in most cases. This different etiopathogenesis determines the possibility of resecting most superficial lesions by mesorectal or total peritoneal stripping, thus achieving optimal surgical outcomes. Radical surgeries to debulk high-stage ovarian cancer have been described since 1965, additionally; in the 1970s, Hudson published the rationale and the description of retrograde hysterectomy during a radical oophorectomy. During the last two decades, the technique of radical oophorectomy with en-bloc resection of rectosigmoid for the frozen pelvis has gained popularity, and different surgical steps have been standardized to ease replication and used for teaching purposes. Moreover, the reduction of bleeding and the oncologic effectiveness of this cytoreductive procedure fit well together with the concept of the complete multiorgan debulking required in advanced ovarian cancer. In this view, the use of this standardized radical surgery allows the safe and comprehensive removal of all pelvic cancer in patients with advanced ovarian disease. This manuscript is an extensive updated technical overview from the pioneering series of our retired mentors to the current evolving surgical breakthroughs. Nowadays, this complex exenterative surgery paradigm for the frozen pelvis in advanced ovarian cancer is still changing because the innovative biological, genetic knowledge is continuously growing and evolving parallel to the advanced perioperative, anesthesiologic, and radiologic care.

Keywords

Radical surgery; Epithelial ovarian cancer; Frozen pelvis; Radical oophorectomy

1. Rationale of Cytoreductive Surgery in Advanced Ovarian Cancer

Epithelial ovarian cancer (EOC) is an aggressive disease with a tendency to metastasize peritoneal, lymphatic nodes, organ parenchyma, and bowel segments. In 70% of women, the diagnosis of EOC is at the advanced (III–IV stage) FIGO (Federation of Gynecology and Obstetrics) stage. Thus, the delay in the diagnosis and the onset of the disease determines a total five-year survival rate of 38% in these patients [1]. The most significant prognostic factors are postoperative residual disease (RD), stage, general performance condition, and age. Patient survival is negatively correlated with RD diameter in many series and meta-analyses, emphasizing the role of maximal cytoreduction [2–5]. In 1975 Griffiths first investigated and hypothesized the positive prognostic value of maximal cytoreduction in patients with advanced disease

[6, 7]. In the first report of 102 patients with stage II–III EOC, Griffiths clearly described reducing residual tumor volume enhanced patient survival. Interestingly, Bertelsen analyzed the difference in five-year survival rates and disease progression rates between patients who underwent optimal cytoreductive surgery and those who received the suboptimal debulking procedure in advanced EOC. The author reported a significant improvement in five-year survival rates (46% optimal surgery and 15% suboptimal surgery, $p < 0.001$) and in disease progression rates (10% optimal surgery and 43% suboptimal surgery) in patients with optimal cytoreduction [8]. Data from literature about optimal cytoreduction are consistent for FIGO stage III disease, while data from stage IV has not been fully clarified. However, patients with stage IV seem to have significant benefit from debulking surgery with a median survival of 55–64 months [3, 9–12]. Furthermore, current

investigations from high-volume centers specify that up to 60% of patients with advanced EOC (FIGO stages III–IV) are likely to attain complete debulking procedures. Thus, the possibility of achieving complete cytoreduction is intimately linked to surgeons' expertise [13]. To date, a recent relevant phase III clinical trial confirmed that cytoreduction and subsequent adjuvant chemotherapy with platinum are regarded as the most active therapy for high stage EOC. Indeed, the report from the European Organization for Research and Treatment of Cancer (EORTC) protocol concluded that both the primary and interval debulking surgery with complete cytoreduction of all macroscopic cancer was the most relevant independent factor in the prediction of overall survival. The same group reported that neoadjuvant chemotherapy and subsequent interval cytoreduction as a therapeutic strategy for patients with stage III–IV ovarian cancer was not inferior to the primary cytoreduction procedure followed by chemotherapy [14, 15]. However, complete cytoreduction of all macroscopic cancer, both as primary and interval surgery, is the main goal whenever the debulking procedure is accomplished [16–18]. Debulking surgery is a multi-visceral procedure including pelvic and abdominal organs aimed at attaining total resection of all macroscopic cancer implants to a microscopic cellular level [5, 19], hereafter also named cytoreductive surgery. Among several surgeries for a complete debulking procedure, bowel operation has been a critical task of the cytoreductive surgery for attaining no macroscopic residual of the tumor. Ovarian malignancies are frequently onset in the advanced stage and often involve the bowel in the rectosigmoid segment, which must be excised for optimal debulking [20, 21]. In this view, it is mandatory to focus on the biology of EOC that is different from gastrointestinal tract cancers. The spreading of EOC is essentially characterized by diffusion through the peritoneal surface and mechanisms of direct infiltration. This concept is recognized as a transfer pathway, and it clarifies the diffusion of cancer cells within the intrabdominal ascites accrual. Fluid diffusion depends on the gravity and the negative pressure determined by diaphragmatic and lung movements at respiration combined with the peritoneum, omentum, and bowel across the falciform ligament in a clockwise direction. The lymphatics system is a significant route for spreading metastasis in ovarian cancer, while vascular spreading is less frequent. Consequently, dealing with the surgery of ovarian tumors requires knowledge of the possible metastatic pathways and comprehension of all relative assessments and operative tasks. Unlike colorectal cancer, malignant ovarian cells tend to invade superficial abdominal surfaces disseminating within the peritoneal cavity, thus involving the peritoneum layer and the omentum in most cases [22]. This different etiopathogenesis determines the possibility of resecting most superficial lesions by mesorectal or total peritoneal stripping, thus achieving optimal surgical outcomes. Also, ovarian cancer commonly infiltrates the bowel anteriorly, whereas the mesorectum tissue is infrequently involved posteriorly. Remarkably, circulating peritoneal metastasis are present in most FIGO stage III or IV ovarian cancer patients. In this view, the surgical strategy in ovarian cancer is centered on the complete cytoreduction with attaining no gross residual disease rather than microscopic negative margin status like in colorectal cancer [23]. Radi-

cal surgeries to debulk high-stage ovarian cancer have been described since 1965 [24]. In the '70s, the concept of en-bloc exeresis of pelvic organs and the surrounding peritoneum was introduced, thus developing the “peritoneal compartment” idea as a new surgical concept. Indeed, Hudson published the rationale and the description of retrograde hysterectomy during a radical oophorectomy [25]. Then, many authors will publish several reports about the same surgery using different denominations. The rationale of en-bloc resection is founded on the idea of ovarian cancer as a peritoneal disease. According to this concept, the peritoneum acts as a spreading channel and reduces the diffusion of cancer cells. Indeed, it is infrequent the diffusion and the involvement of the retroperitoneal anatomic structures. The en-bloc resection aims to achieve dissection planes within healthy tissue, prevent cancer manipulation, and section through malignant tissue. Rapid cancer proliferation is typically maintained by profuse angiogenesis, mainly at the cancer periphery. Therefore, there is an alteration of normal anatomy and aberrant vascularization. According to the robust finding of cancer diffusion via the peritoneal paths, this concept is not appropriate for patients with ovarian cancer. The traditional anatomical planes do not represent the planes of resection in these patients. Generally, the peritoneal sheet prevents the infiltration of malignant cells, acting as a natural barrier. The opening and development of the retroperitoneal space are critical for attaining a safe dissection plane, finding the correct anatomic landmarks, and allowing surgical devascularization, thus diminishing blood loss. In advanced ovarian cancer and the frozen pelvis, the aim is to remove all pelvic organs, except the bladder, together with the peritoneal compartment to remove the entire involved organs with clear boundaries, thus reaching the maximal cytoreduction [25]. This updated overview of technical features of pelvic ultra-radical surgery attempts to improve knowledge of the procedure among physicians when referring patients with advanced ovarian cancer. In patients with disrupted pelvic anatomical conditions such as the so-called “frozen pelvis”, the surgeons are called to a significant effort to achieve the maximal cytoreduction. In addition, the improvement of surgical knowledge in this complex multi-visceral surgery and learning about its indication and limitation may result in a more accurate comparison of outcomes results, fewer complications, and improved patients' quality of care.

2. Historical Landmarks

Ultra-radical pelvic surgery for complete excision of the pelvic viscera or pelvic exenteration is a surgery that developed in the '40s. In 1948 Brunschwig reported the intervention of complete removal of pelvic organs for advanced staged cancer of the cervix, uterus, vulva, vagina, and primary rectosigmoid cancer [26]. The radical exenterative surgeries strategy had advanced since 1965 when Barber and Brunschwig first described the outcomes and technical features of a case series of 22 women who experienced pelvic exenteration for advanced gynecologic and pelvic malignancies. The authors reported around 23% of postoperative mortality rates, though insufficient data about long-term survivors were described [24]. Interestingly, in 1968 and 1973, Hudson and Chir independently

reported a technical description of en-bloc pelvic resection of the ovarian tumor mass with rectosigmoidectomy. However, Hudson was considered the pioneer in this surgery thanks to his detailed description of the “radical oophorectomy” technique as en-bloc pelvic peritonectomy, total hysterectomy, and bilateral salpingo-oophorectomy with or without resection of the rectosigmoid colon [25, 27]. Later, this radical exenterative operation was accepted worldwide and validated by many surgeons and oncologic centers. Over the decades, this procedure has been further modified and identified with different terms: en bloc rectosigmoid colectomy [28–32], reverse hysterocolposigmoidectomy [33], complete parietal and visceral peritonectomy [34], en bloc pelvic peritoneal resection of the intrapelvic viscera [35] and modified posterior exenteration [36]. The goal of en-bloc pelvic excision for advanced EOC indications changed from a concept of palliative surgery to an operation with curative value. According to the intrinsic radicality and the high related morbidity, pelvic mega-operations are generally proposed as a curative procedure in case of advanced or recurrent central pelvic cancer in patients formerly treated with radiotherapy or with presumed low success rates of chemotherapy [37]. A frozen pelvis condition was commonly predictive of a challenging procedure and poor survival in patients with advanced ovarian cancer. Thus, the introduction, development, and validation of this extensive multi-visceral surgery seem to have changed the paradigm over time. We will focus on this exenterative technique in advanced EOC, an ultra-radical surgery eradicating en-bloc all the involved pelvic organs, including the uterus, ovaries, and vagina, the rectosigmoid colon, rarely the bladder, and the surrounding tissue according to the extension of the tumor.

3. Presurgical Evaluation and Preparation

Before assessing the surgical feasibility, the analysis of risk factors such as age, coexisting illnesses, performance status, nutrition, obesity, disease burden, location of metastatic sites, and tumor stage can permit the operators to appropriately triage patients at substantial risk of relevant morbidity to different primary cares. Patients enrolled for radical multiorgan resection should undertake accurate presurgical and diagnostic evaluation. Preoperative physical, pelvic, and rectovaginal examination and blood and biochemical analysis with CA 125 and other tumor markers are offered to all patients selected for surgery. Pelvic ultrasonography, Computer Tomography (CT) scan of the chest, abdomen, and pelvis or Magnetic Resonance Imaging (MRI), along with Positron-Emission Tomography (PET) scan, are instrumental examinations for the detection of possible metastatic lesions or evaluation of the urinary and intestinal tracts. Moreover, these examinations assess the involvement of the ureters, bowel, and pelvic sidewalls and were performed routinely to provide information about the disease burden. Cystoscopy and lower gastrointestinal endoscopy are sometimes indicated to determine pelvic organ tumor involvement accurately. Also, CT arteriography, venogram, and MRI can be helpful to plan radical pelvic surgery to achieve R0 (microscopic) cytoreduction [38]. Directed biopsies are sometimes necessary for pathologic review as well as for a compre-

hensive presurgical assessment. Considering that the preoperative evaluation about the complete resectability at the time of the primary surgery is frequently complex in women with stage IIIC or IV, some patients could be considered for a diagnostic surgical approach by laparoscopy or laparotomy to visually assess for complete cytoreduction [39]. Laparotomy is generally planned in patients who are eligible for interval debulking procedure after neoadjuvant chemotherapy, but it represents an invasive treatment. The European Society of Gynecological Oncology (ESGO), Guidelines for Ovarian Cancer Surgery, considered the diagnostic laparoscopy a crucial step in advanced ovarian cancer operations. If the surgical examination assesses the resectable disease, primary cytoreduction should be performed; neoadjuvant chemotherapy can be administered if complete resectability seems unlikely. Recent studies and a meta-analysis reported that diagnostic laparoscopy assessment of potential optimal cytoreduction is suitable for 70% of patients with a negligible number of false positives [40]. Laparoscopic criteria for resectability are developed and scored according to the presence of peritoneal carcinomatosis, diaphragmatic, mesenteric, or omental disease, bowel or stomach infiltration, and liver metastasis. This evaluation has been standardized in the Fagotti score, which is a quantitative, laparoscopy-based model for predicting the chance of optimal cytoreduction [41]. Nevertheless, the diagnostic laparoscopy is still not definitively satisfactory in assessing some cases with intra- and retroperitoneal involvement of upper abdomen sites. Furthermore, some patients could experience a suboptimal primary debulking surgery despite diagnostic laparoscopy predicting maximal cytoreduction because optimal debulking rate depends upon the patient and cancer characteristics and the advanced expertise in gynecologic oncology surgical team [42]. Despite the potential benefit of diagnostic laparoscopy, some experts prefer to proceed with neoadjuvant treatment in patients who appear to have unresectable disease or large ascites based in imaging alone. A CT-guided biopsy or cytology should be obtained prior to initiating treatment in patients who have not undergone laparoscopy. This complex multiorgan surgery often requires several surgical specialists on the surgical team for all planned surgical tasks. A lead surgeon will coordinate the multidisciplinary team with the sole intent to plan and achieve complete resection and no gross residual after treatment. In addition, patients needing exenterative procedures are often malnourished. Therefore, preoperative total parenteral nutrition might be prescribed and procrastinated in these patients to reestablish adequate bowel function and perioperative hydration [43]. According to the possible enterolysis or bowel surgical involvement, all patients should undergo preoperative bowel preparation. However, the need for mechanical bowel preparation in patients undergoing colorectal surgery is still debated, and data about the pros and cons are not conclusive. New meta-analyses confirmed the benefits of oral antibiotic bowel preparation, but it also demonstrated that mechanical bowel preparation alone did not offer any positive effects. It was also described that the performance of mechanical bowel preparation did not significantly decrease complications in planned colorectal surgery during the postoperative period. Furthermore, it has been reported that patients undertaking presurgical mechanical

bowel preparation had a higher prevalence of bowel content spillage, thus increasing the rates of postoperative complications [44]. A study investigating patients who were 75 years old or older enrolled for elective colectomy demonstrated that both oral antibiotic bowel preparation and oral antibiotics plus mechanical bowel preparation showed reduced morbidity compared to other elderly patients without bowel preparation [45]. Moreover, the frequency of surgical site infection seemed to be reduced by oral antibiotic bowel preparation in a population of patients following planned colectomy without mechanical bowel preparation [46]. The innovative enhanced recovery after surgery (ERAS) protocols do not recommend routinely mechanical bowel preparation in colon operations to avoid the concerns of dehydration, distress to patients, prolonged ileus, and lack of efficacy [47, 48]. A recent study on a national database analyzing the outcomes of a large population of women underwent hysterectomy (186,148 benign and 38,539 malignant cases), reported that the use of bowel preparation did not decrease rates of surgical site infections, anastomotic leaks, or major morbidity following benign or malignant hysterectomy. Of the total number of patients enrolled for hysterectomy with malignant indications, 87.2% underwent any preparation, 9.6% mechanical bowel preparation only, 1.8% oral antibiotics only, and 1.4% mechanical bowel preparation with oral antibiotics. Interestingly, among malignant abdominal hysterectomies, there was no difference in the rates of infectious morbidity between mechanical bowel preparation alone, oral antibiotics alone, or mechanical bowel preparation with oral antibiotics, compared to no preparation. The authors concluded that bowel preparation does not protect against surgical site infections or major morbidity following benign or malignant hysterectomy, regardless of surgical approach, and may be safely omitted [49]. High-quality evidence in a Cochrane review also indicates that oral or intravenous antibiotics covering both aerobic and anaerobic bacteria before elective colorectal procedures decrease the risk of surgical wound infection by nearly 75% [50].

In case of imaging detection of any ureter's dilatation, anatomical aberration, compression, or deviation, the preoperative ureteral catheterization may be evaluated to identify ureters, thus avoiding complications. Oncologic patients scheduled for pelvic radical debulking may generally present a high risk for pulmonary embolism. Tools for mechanical compression seem appropriate during perioperative management with no significant risk of bleeding, while operators should tailor chemical prophylaxis balancing the risk of plausible intraoperative blood loss against the significant clinical risk of pulmonary embolism. In this view, it is mandatory to advise the patient of the possible need for transfusion of red blood cells or other blood products during surgery. Intraoperatively, transfusion criteria are individualized by anesthesiologists and surgeons while monitoring vital signs, urine output, and blood loss [43]. In addition, preoperative counseling by a caregiver with an adequate formation in psychosocial and sexological issues may be of helpful for surgery-related sexual and personal changes in the postoperative period when the patient feels the impact of demolitive surgery and possible adverse events such as vaginal stenosis, discharge, vulvar pain, and dyspareunia.

Also, the possible benefits of reconstruction techniques must be elucidated at preoperative counselling [51].

4. Surgical Technique

4.1 Classification

Definition and descriptive classification of the radical oophorectomy will be used to understand the aim of this debulking surgery better. A Type I radical oophorectomy is a retrograde modified radical hysterectomy with resection of medial parametria and proximal vagina, en bloc resection of the adnexa, pelvic cul-de-sac, and involved pelvic peritoneum. In the case of previous subtotal hysterectomy or total hysterectomy, the procedure is modified, including removing the residual cervix or the vaginal apex. In addition, peritoneal or serosa stripping and limited segmental resection with primary closure of the anterior sigmoid may be included in this procedure. Type II radical oophorectomy is the most frequently performed and consists of the combination of the preceding surgery with en-bloc rectosigmoid resection below the peritoneal reflection with complete removal of parietal and visceral pelvic peritoneum to resect pelvic cancer completely. Type III radical oophorectomy represents an extension of type I or II procedure combining the partial resection of the urinary bladder or pelvic ureter with en bloc resected specimen [52] (Table 1).

4.2 Type II Radical Oophorectomy

The patient is supine lithotomy position with flexed legs surrounded by alternating-pressure boots and legs holders. Care must be taken about the legs being distributed at the sole of the feet by the correct setting of the footrest, thus avoiding weight on the calf. Indeed, the calf muscle can suffer myonecrosis if the legs are not accurately protected by foam padding. The gluteal fold must be positioned advanced to the end of the surgical table to allow complete and easy access to the perineum during the procedure. These should be operative before the start of anesthesia for maximal protection against venous thrombotic. The foley catheter and nasogastric tube are positioned within the stomach. Before paramedian or midline incision, extensive omental and intestinal adhesions are likely, but with increased risk of intestinal injury. Consider other incisions that may make it possible to find an area lateral to the original incision where the peritoneum, omentum, and intestinal tract are not adherent [53]. The abdominal entry and exposition of the surgical field are achieved with a midline xiphopubic incision and the subsequent positioning of a self-retaining Bookwalter retractor, thus assessing the spreading of the disease and the concrete possibility to cytoreduce the upper abdominal quadrants completely. After accurate examination of the abdominal retroperitoneal area and resection of lesions on the peritoneal surface, the omentum must be resected, and both ascending and descending colon must be mobilized. Type II radical oophorectomy starts with the bilateral incision of the paracolic gutters and the peritoneum on the psoas muscles to the posterior margin of the symphysis pubis in a ventromedial fashion. The rationale of the technique is to contain all pelvic diseases within this peritoneal incision. The

TABLE 1. Classification and technical features of different types of Radical Oophorectomy.

Type	Hysterectomy	Parametria	Adnexa	Pelvic cul-de-sac tumor	Pelvic peritoneum	Rectosigmoid	Bladder	Pelvic ureter
I	Modified radical retrograde	Yes	Yes	Yes	Yes	No	No	No
II	Modified radical retrograde	Yes	Yes	Yes	Yes	Yes	Yes	No
III	Modified radical retrograde	Yes	Yes	Yes	Yes	Yes	Yes	One or both

dissection of the pelvic anatomical structures continues in a centripetal fashion. The extension of the tumor infiltration of pelvic tissues can disrupt normal anatomy, thus complicating the identification of round ligaments, which can be retroperitoneally approached. After being identified, the round ligaments must be ligated and sectioned as laterally as possible. Parallel, the infundibulopelvic ligaments with ovarian vessels are identified, isolated, and secured as far above the pelvic brim for the devascularization of the central tumor. The surgery proceeds with ureter identification and mobilization from their attachments to the medial side of the broad ligament, moving from the pelvic brim to the tunnel of Wertheim. The sigmoid colon is medially mobilized to improve the visualization of the left pelvic anatomy, thus defining the extent of intestinal resection required. The proximal sigmoid colon is sectioned above the most proximal extent of the macroscopic tumor with a simultaneous ligating-dividing-stapling instrument. The mesentery of the sigmoid colon is then sectioned, ligating individual vessels, including the superior hemorrhoidal artery. The posterior dissection of the rectum proceeds bilaterally, developing the pararectal and retrorectal spaces and dissecting down to the level of the pelvic floor. In detail, the opening, and the development of the presacral space is performed caudally to the plane of pelvic floor muscles to achieve the complete mobilization of the posterior pelvis. This surgical step is completed by clamping, isolating, and securing the rectal pillars and the middle hemorrhoidal artery. With sharp and blunt dissection, the pararectal and the paravesical spaces are entered and developed (Table 2). The uterine artery and the cardinal ligament are then identified bilaterally, and uterine vessels are isolated, ligated, and sectioned at the level of the parametria and the ureter, which is further laterally displaced from the central tumor mass. The retropubic space of Retzius is opened and developed by identifying a safe plan between the muscular bladder wall and the infiltrated anterior peritoneum, which is stripped ventral-dorsally and lateral-medially from the bladder muscularis until the pubo-vesical-cervical fascia using electrocautery, argon beam coagulator, or scissor. The anterior peritoneum, comprehensive of tumor implants, remains attached to the anterior wall of the uterus. The bladder is mobilized ventrally and caudally to free the proximal 2–3 cm of the vagina, and the space between the vagina and bladder is entered and developed. Interestingly, the vesicovaginal space usually is not infiltrated by the tumor and can outline the correct boundary between bladder and cancer tissue to be dissected. However, when disease deeply involves the anterior pelvic peritoneum determining strong adhesences with the uterine cervix, the paravesical space can be accessed with a lateral-medial approach below the cervical level until the vesicovaginal space is entered. The ureteral tunnel is developed using advanced bipolar tools or

canonical right-angle clamp and ligature; after that, the ureter is detached from the bladder pillar bilaterally. Infrequently, adjunctives demolitive procedures on the bladder or ureters can be necessary according to the extension of disease and the neoplastic invasion of the bladder, thus requiring cystotomy and partial resection of the bladder ureterectomy or ureteral reimplantation by ureteroneocystostomy at the end of surgery. The bimanual examination and the use of a vaginal probe or a sponge into the anterior vaginal fornix enable the detection of the inner vagina and the suitable level of the incision. Hysterectomy is then completed in a retrograde fashion, starting with transversal anterior colpotomy. After the incision of the posterior vaginal wall, the cardinal ligament's residual attachment is bilaterally detached. The rectovaginal space is developed with an accurate caudal dissection along the anterior rectal wall up to the free lower margin of the cul-de-sac (2–3 cm) from the neoplastic tissue. The tumor mass is mobilized and retracted upward to preserve the maximal length of the proximal rectum after resection and to expose the remaining uterosacral ligament and rectal pillars, which are resected in sequence. Moreover, it is technically relevant to mobilize the proximal part of the sigmoid colon to achieve a tension-free colorectal anastomosis. The retrograde approach is concluded, and the rectum is distally sectioned using a linear dividing-staple device. The uterus with pelvic peritoneum, adnexa, and rectosigmoid colon is finally removed en bloc as a single tumor mass specimen, leaving the pelvis completely free from macroscopic cancer. The anastomosis between the colon and rectal segments is accomplished using a circular stapler [25, 52].

4.3 Technical Implications of Type I and II Modifications

Type I modification is the proper treatment in exclusive superficial involvement of the rectum by tumor mass. In this case, the anterior surface of the rectal wall and the peritoneum can be freed from the tumor. When the neoplastic lesion involves the muscularis of the rectum, and the extension is limited in diameter, the surgeon may excise and repair a wedge-shaped segmental resection. Then suturing with monofilament suture, the closure should be performed perpendicular to the major axis of the rectum to reduce a narrowed lumen. When ovarian cancer concomitantly involves the posterior cul-de-sac and rectosigmoid colon, the type II modification of radical oophorectomy is the treatment of choice. The first step is to identify the indication for bowel resection to attain an optimal cytoreduction. Next, the sigmoid is sectioned 2 to 3 cm cranially to the most proximal part of cancer involvement. Once the bowel is adequately cleared from surrounding fat 2 to 3 cm from the planned anastomotic point, a stapler can be

TABLE 2. Anatomical borders of pelvic spaces of interest for radical gynecologic surgery.

Anatomical space	Anatomical borders				
	Medial	Lateral	Anterior	Posterior	Inferior
Prevesical/Retzius (midline)	-	Levator ani, obturator internal fascia, arcus tendineus of the pelvic fascia	Pubic symphysis/levator ani	Bladder	Bladder neck/urethra
Vesicovaginal (midline)	-	Pelvic side wall, broad and cardinal ligaments	Bladder and proximal urethra	Uterus, vagina	Proximal third of the urethra
Rectovaginal (midline)	-	Uterosacral ligament	Uterus/cervix/vagina	Rectum	Levator ani muscle
Paravesical (bilateral)	Obliterated umbilical artery	External iliac artery	Pubic symphysis	Uterine artery	Fascia levator ani
Pararectal (bilateral)	Ureter	Internal iliac artery	Uterine artery	Sacrum	Pelvic diaphragm
Presacral/Retrorectal (midline)	-		Mesorectum	Waldeyer fascia	

used for sigmoid resection. The dissection continues deeply from the pararectal space to the entry of the presacral space, caudally to the sacral promontory, and in a posterior-medially fashion. The presacral space is further developed to mobilize the posterior pelvis to the plane of the pelvic floor muscles. The central pelvic cancer involving the posterior cul-de-sac and the bowel wall is freed from pelvic structures by developing the rectovaginal space, dissecting to the site of cancer invasion, and all remaining mesorectal tissues. The central tumor mass and rectosigmoid colon are then excised en-bloc, 2 to 3 cm from the most caudal part of the rectal lesion using a stapler device and a proximal rectal clamp. After the determination of adequate tension-free anastomosis, the bowel continuity is restored by using a traditional hand-sewn technique or more advanced 28–31 mm automated circular stapler. To reinforce the anastomotic point, some authors reported the use of automated stapling devices and subsequent manual hand-sewing with interrupted stitches over the staples. In addition, resection rings should be examined to ensure the presence of two complete donuts of colon tissue. Moreover, tests to evaluate the security of the anastomotic site can be performed occluding by hand the proximal part of the colon after filling the pelvis of saline solution before the insufflation of 200 to 300 cc of air in the rectum through a syringe or proctoscope. The absence of air bubbles indicates a good technical result, while the presence of air bubbles suggests anastomotic leak and needs reinforcement suture of the defect, possible diverting ileostomy, or anastomosis revision [54].

5. Role and Efficacy of en bloc Pelvic Resection and Rectosigmoidectomy in Ovarian Cancer

5.1 Effectiveness

En-bloc resection of reproductive organs in continuity with all pelvic peritoneum and segment of rectosigmoid colon is the proper surgery to achieve optimal or maximal cytoreduction in many cases of advanced EOC. New knowledge about tumor bi-

ology, genetics, and clinical evolution, identify this procedure as a highly specialized operation with specific purposes. While Hudson and Chir originally described the radical oophorectomy to define a procedure to eradicate extensive ovarian malignancies emphasizing the retroperitoneal approach to remove the reproductive organs in continuity with all tumor and pelvic peritoneum [27]; few authors evaluated the feasibility, the technical features, and clinical outcomes of this complex multiorgan surgery associated with rectosigmoid resection. In the '80s, Berek and colleagues previously reported the clinical outcomes of 24 women who underwent removal of reproductive organs in continuity with rectosigmoid resection for advanced ovarian cancer without stating the number of patients who had such procedure or were undergone radical oophorectomy with separate sigmoid resection [29]. Warton described technical details and operative plan for a retroperitoneal approach to extensive pelvic ovarian cancer, stressing that all the genitourinary or colorectal segments involved in the tumor mass may be extirpated as part of the specimen in particular surgical circumstances; however, this report did not report accurate survival and morbidity outcomes [55]. In 1991, Eisenkop first described the so-called “modified posterior pelvis exenteration” and standardized the en-bloc resection technique for advanced EOC removing the reproductive organs, the pelvic peritoneum, and a segment of rectosigmoid in a single specimen to complete pelvic tumor extirpation. This surgery was similar to the extended supra levator posterior pelvic exenteration or type one posterior, previously described and classified by Magrina to treat persistent and recurrent cervical cancer [56, 57] (Table 3). However, in the Eisenkop procedure, the uterosacral and cardinal ligaments were not excised, and vaginal length resulted in less reduction. The report described the operative and clinical outcomes of 47 patients with stage IIIC–IV EOC, with pelvic cancer involving the uterus, adnexa, and pelvic peritoneum, cul-de-sac, and sigmoid colon. All patients underwent modified posterior pelvis exenteration, 37 for primary cytoreduction and 10 for secondary surgery, and they were evaluated with a median follow up of 13.3 months (6–84 months). Interestingly, 45

(95.7%) had optimal cytoreduction (≤ 2 cm), and 18 (33.3%) had complete cytoreductive treatment. Thirty-four women ultimately preserved their defecatory function (25 primarily and nine after colostomy reversal). Nine patients (19.1%) experienced severe morbidity, and one (2.1%) postoperative death was reported. The author emphasized that modified posterior exenteration was effective in removing all visible pelvic disease with acceptable mortality because of the specific tendency of ovarian cancer to spread along peritoneal surfaces while not directly invading retroperitoneal vascular, urinary, and uterine ligaments structures. In this view, even patients with the most advanced disease may achieve optimal debulking, thus becoming eligible for adjunctive medical treatments [36]. Later, several case series were published confirming the relevance and the efficacy of this exenterative surgery for advanced ovarian cancer. However, surgeons are frequently forced to change intraoperative strategy after complete exploration due to the heterogeneity of the pelvic disease in patients with advanced EOC. This makes it difficult for the performance of randomized controlled trials (RCT). The relevance of rectosigmoid colectomy as a surgical step during debulking in stage IIIC/IV EOC has been pointed out in a retrospective report of 527 women treated for primary surgery. Interestingly, 79% of patients (458) underwent optimal cytoreductive surgery (residual < 2 cm), and 27.3% of these patients (144) needed rectosigmoid resection to achieve no gross residual disease. Of the 144 patients who had undergone rectosigmoid resection, 56.3% had only rectosigmoid resection. Indeed, the rectosigmoid represents the most frequently involved segment of bowel in patients with advanced FIGO stage EOC [21, 58]. Hertel *et al.* [59] stressed the concept that indication of rectosigmoidectomy in advanced stages EOC is related to histopathologic findings and all cytoreductive effort avoiding the underestimation of tumor invasion. He advised that when the tumor mass involves the anterior wall of rectosigmoid colon, the deperitonealization procedure is not adequate to achieve complete tumor resection. He analyzed histopathologic findings and operative outcomes of 100 cases FIGO stage IIIC ovarian cancer underwent en-bloc resection of pelvic organs with rectosigmoidectomy as a part of primary or secondary cytoreduction. In 73 patients, the rectosigmoid colon was involved by cancer. In detail, tumor infiltration involved serosa (28%), muscularis (31%), and mucosa (14%). Whereas no invasion by tumor was described in 37% of patients. Postoperative histology assessed pelvic R0 resection was successfully attained in 85 cases. The author also emphasized that in 11 cases, the resection margins were involved by cancer, and the macroscopic parametric tumor was left in situ in 4 of patients. Pelvic recurrence was reported in 4 (4.7%) of 85 complete cytoreductive surgery compared with 9 (60%) of 15 non optimally debulking surgery. According to the evidence that the most caudal part of the rectum is lying extraperitoneal and is typically not infiltrated by the disease since ovarian tumor cells generally spread along the peritoneal lining, he suggested that rectosigmoidectomy and re-anastomosis can be performed with sound margin in most instances.

5.2 Types of Resection and Ovarian Cancer Biology

After more than two decades, the debate about the relevance of free margins after debulking surgery for advanced ovarian cancer is far from being closed, and new biological and genetic findings are changing the paradigm of the surgical rationale [59]. As previously elucidated, the biology of ovarian cancer is also a key factor in understanding the role of rectosigmoid resection during cytoreduction for ovarian cancer. In EOC, ascitic fluid and its dynamic seem responsible for the primary cells' dissemination mechanism and peritoneal seeding, thus determining superficial implants that are resectable lesions with total peritonectomy or mesorectal stripping in most cases. Bowel infiltration in ovarian cancer is mainly related to anterior lesions that invade the serosa, then into the muscular layers followed by the mucosa, while the posterior mesorectal tissue is rarely involved. This biological process is opposite to the colorectal cancer mechanism of diffusion characterized by direct invasion of mesorectal tissue and opposite diffusion in the bowel wall. In this view, a positive margin status is not an absolute objective of ovarian cancer surgery [23]. Nevertheless, there are still insufficient data in the literature concerning the best strategy to perform posterior rectal dissection and rectosigmoid resection during a cytoreductive procedure in patients with EOC. The total mesorectal excision (TME) is the most usually adopted technique for rectosigmoid colon resection. According to this technique, all mesorectal tissue is removed, thus resulting in a low local recurrence rate but an increased number of local infections and anastomotic leakages in patients with colorectal cancer. On the contrary, data about the close rectal dissection (CRD) that aims to preserve the mesorectal tissue and blood supply seems related to a lower rate of leakage and better functional outcomes. Notably, TME is the most used technique by colorectal surgeons, while gynecological oncology surgeons mainly adopt CRD. An analysis of outcomes of 163 patients receiving posterior rectal dissection for colorectal resection as a part of debulking surgery for advanced EOC confirmed a higher rate of anastomotic leakage ($p = 0.045$) and prolonged ileus persisting for more than 7 days ($p = 0.055$) in patients undergone TME. To confirm the different patterns of local spreading and biology between EOC and colorectal cancer, the authors reported no differences in patient free survival (PFS) and pelvic relapses according to TME or CRD technique [20]. Recently, a multicenter Korean report retrospectively described survival outcomes of 397 patients with FIGO stage II–III EOC grossly limited to the pelvis, according to two techniques of bowel surgery for pelvic tumors: the low anterior resection (LAR) or the tumorectomy. Additionally, the report compared survival outcomes of patients who received tumorectomy and patients who did not undergo surgery. Of 92 women (23.2%) with gross tumors at the rectosigmoid colon, 68 (73.9%) underwent tumorectomy, and 24 (26.1%) LAR for rectosigmoid lesions. The authors found no significant difference in 5-years progression-free survival (PFS) and OS between patients undergone tumorectomy or LAR and more frequent postoperative ileus in patients who underwent LAR. Interestingly, the 5-years PFS and OS of patients subjected to

TABLE 3. Classification and technical features of different types of Pelvic Exenteration.

Group	Type	Viscera	Levator muscles	Urogenital diaphragm	Vulvoperineal tissue
Anterior	I. Supralevator	Above levator	None	None	None
Posterior	II. Infralevator	Below levator	Limited	Limited	Complete
Total	III. With vulvectomy	Below levator	Complete	Complete	Complete
Extended	Any of the above plus resection of additional tissues (bone, soft tissues, small bowel, or groin nodes).				

tumorectomy and those who didn't were similar [60]. These data further confirm a peculiar spread pattern of malignant ovarian cells that diverges from colorectal cancer. In this view, it is plausible to consider that the tumor that infiltrated up to the serosa and subserosa of the rectosigmoid colon can be excised by tumorectomy without gross residual tumor, thus reducing LAR in early-stage EOC. However, the rationale and the role of concomitant posterior dissection of the rectum and rectosigmoidectomy as a unique step of ovarian cancer operations need further conclusive investigations. The broad variability of anatomical findings together with the heterogeneity of the disease seem to be reasons why the planning of surgical strategy before this complex multivisceral procedure is challenging and why RCT evaluating the efficacy of en-bloc resection of rectosigmoid bowel during advanced ovarian cancer surgery are still lacking (Fig. 1).

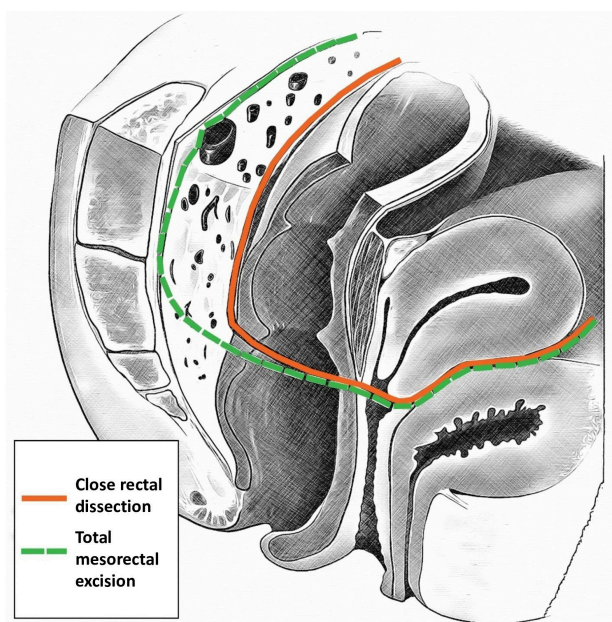


FIGURE 1. Close rectal dissection (CRD) and total mesorectal excision (TME) during radical oophorectomy and concomitant rectosigmoidectomy.

5.3 Bowel Continuity and Reanastomosis

In the past, concerns about the timing and method of restoring the intestinal continuity when performing a cytoreductive procedure involving rectosigmoidectomy were also argued. Primarily because these patients frequently presented with malnourishment, ascites, bowel partial-obstruction, or obstruction, a trend towards bowel diversion was preferred. Since the standardized procedure was described, several case

series described efficacy, safety, and survival outcomes of patients enrolled for surgery with a plan of en-bloc resection of uterus and pelvic peritoneum, adnexa, and tumor mass and rectosigmoid are reported in the literature. Barnes, in 1991, first reported data of 31 patients who underwent reverse hysterocolpectomy for extensive, symptomatic pelvic malignancies stage II–IV with a lateral retroperitoneal approach. All patients had complete resection of the pelvic tumor, and there were no perioperative deaths. However, sigmoid resection was required in 25 patients with 22 primary re-anastomosis and three end colostomies performed. Moreover, 13 and ten patients experienced early and postoperative morbidity, respectively [33]. Bridges *et al.* [32] retrospectively described perioperative outcomes of 43 cases of FIGO high stages EOC patients who underwent en-bloc resection of pelvic organs with rectosigmoidectomy, and he achieved optimal debulking in 75% of scheduled procedures without any significant compliances. Sainz de la Cuesta *et al.* [35] described the perioperative outcomes of 30 patients after en-bloc resection of the pelvic peritoneum and all pelvic organs with rectosigmoid resection and re-anastomosis in high stages ovarian cancer, thus achieving RD <1 cm in all cases. A relevant Australian report investigated the feasibility and the safety of en bloc resection of ovarian cancer and concomitant low anterior rectosigmoid resection followed by end-to-end anastomosis during primary cytoreductive surgery in a series of 65 stage II–IV consecutive patients. Postoperative residual tumour was no gross residual, residual tumor size <1 cm, and >1 cm in 14 (21.5%), 34 (52.3%), and 14 (21.5%) patients, respectively. Optimal cytoreduction was achieved in 73.8% (n: 48) of patients. Remarkably, postoperative wound complications, septicemia, and the anastomotic leak occurred in 21.5%, 13.8%, and 3.1% of patients, respectively, and were related more frequently to low preoperative levels of serum albumin (≤ 30 g/L) [31]. The same research group retrospectively analyzed the outcomes of 129 patients (stage I–IV) subjected to concomitant en bloc pelvic resection and rectosigmoidectomy. In this case series, the surgical team accomplished optimal cytoreduction (RD <2 cm) in 79.2% of cases, while suboptimal in 18.5%. Operative or postoperative complications occurred in 63 (48.8%) cases; 2.4% of patients developed complications related to bowel anastomosis, moreover perioperative mortality was 3.1%. Interestingly patients who underwent optimal cytoreduction had significantly longer median survival time (37.6 months) compared to cases after suboptimal debulking (11.6 months) [28]. Bristow *et al.* [3] reported 87.1% of optimal cytoreduction rate (≤ 1 cm) in 31 consecutive cases of radical oophorectomy with primary stapled colorectal anastomosis for stage IIIB–IV EOC with only one patient experiencing anastomotic failure and reoperation. The morbidity associated with rectosigmoid

resection by LAR technique concomitantly to primary cytoreductive surgery for FIGO Stages III–IV EOC was investigated by Mourton *et al.* [61] in a series of 70 patients. 12 (17%) of patients underwent a protective ileostomy, while 58 (83%) did not. Only 3 (5%) of patients with primary anastomosis experienced pelvic abscess, and one patient (1.7%) had anastomotic leak requiring diverting colostomy, thus concluding that primary anastomosis is safe during primary debulking surgery. In contrast, protective ileostomy should be used only in selected cases. A retrospective Korean study reporting the postoperative and survival outcomes of LAR and primary anastomosis at the time of en bloc resection for primary (n = 46) and secondary (n = 14) EOC described no surgery-related deaths among the overall 60 procedures. In detail, no visible tumor after primary and secondary surgery was attained in 43.5% and 42.9% of cases, respectively. After primary and secondary surgery, the optimal cytoreduction (RD <5 mm) rate was 89.5% and 64.3%, respectively. Among the patients who underwent primary surgery, patients with no residual disease had significantly longer DFS (30 months) than those with residual cancer (7 months). Similarly, for patients with recurrent tumors, DFS was significantly longer in patients with no visible residual disease than those with residual tumor [62]. A retrospective report on 209 patients FIGO stages IIIC/IV EOC with extensive peritoneal involvement of peritoneum of the cul-de-sac primarily operated with stripping of the pelvic peritoneum (n = 77) or rectosigmoidectomy (n = 57) or no radical treatment (n = 75), demonstrated that patients underwent stripping of the peritoneum or rectosigmoidectomy had significantly improved 5-year OS relative to those were not (stripping 37%, rectosigmoidectomy 39%, neither 6%, $p < 0.0001$). Moreover, in the subgroup of patients with cul-de-sac involvement and optimal cytoreduction, a significant survival advantage was described after maximal pelvic radical surgery (5-year OS, stripping 38%, rectosigmoidectomy 38%, neither 15%, $p < 0.02$). Remarkably, exploring the outcomes of patients with no visible residual tumor, an improved benefit in 5-year OS for patients treated with rectosigmoidectomy (89%) compared with stripping group (50%) was noted [63]. This relevant report from Mayo Clinic further supported the rationale that in presence of extensive pelvic tumor mass and frozen pelvis, the resection of pelvic organs with en bloc rectosigmoidectomy may be considered the preferable surgical strategy in such complex patients. Nowadays, consistent data from literature further confirmed that the single accepted goal of debulking surgery is “no macroscopic residual disease” thus, each effort to remove all the cancer implants should be undertaken both in the pelvis and in the abdomen at the time of surgery [4].

6. Surgical Evolution and Alternative Techniques

6.1 Technical Alternatives

Radical surgery encompassing en-bloc resection of pelvic organs and rectosigmoidectomy during ovarian cancer procedures in the case of the frozen pelvis is now broadly described and standardized. However, the onset of novel biomolecular

and genetic knowledge and innovative technologies and patient care protocols resulted in a constant evolution of surgical procedures through the last decade. An interesting technique to decrease the intraoperative spreading of malignant cells was described by Barnes [33] to reduce the occurrence of metastatic lesions to the liver by diminishing the intraoperative diffusion of colorectal cancer cells. The novel procedure was named “no-touch isolation technique” and involved early ligations of lymphovascular pedicles before manipulating the tumor mass during cancer resection. This procedure starts with the incisions and the retroperitoneal access along with the lateral peritoneal reflections medially close to the white line of Toldt, and bilaterally from paracolic sulci cephalad to the splenic and hepatic flexures of the colon. After that, the ovarian and mesenteric vessels and ovarian lymphovascular flow are centrally ligated in the retroperitoneal space. The pelvic tumor-bearing segment is not touched. This procedure first allows the isolation and the ligation of the vascular supply to the cancer mass and subsequently the assessment of lymph nodes involvement. In case of extensive disease with omental cake involvement, the procedure should continue with opening the omental bursa for the mobilization and the inspection of the entire colon, determining the involvement of upper abdominal quadrants by cancer. The final step of the procedure is the canonical approach to the intraperitoneal cancer compartment that includes the infiltrated bowel segment, surrounded from the healthy external boundaries in a centripetal fashion, including en bloc resection pelvic and bladder peritoneum, and colorectal resection with re-anastomosis. The no-touch isolation technique was preliminarily experienced in a cohort of 20 ovarian cancer patients FIGO stages IIB–IVA with 19 months of median follow-up, resulting in low blood loss and a significant rate of optimal debulking in all cases and no recurrence of pelvic disease. The mean operating time and the hospital stay were 320 min and 12 days, respectively. Thirty five percent of patients experienced significant complications most frequently related to rectosigmoid involvement; therefore, four patients required total parental nutrition, one patient experienced anastomosis dehiscence, and one died. The effect of the no-touch isolation procedure on the intraoperative diffusion of cancer cells will be difficult to argue. However, it is plausible to speculate that the proposed central vascular ligation should reduce complications such as blood loss and lymphocele accrual. Additionally, the elevation of the whole colon during the opening and development of the retroperitoneal space seems to predict optimal cytoreduction. Therefore, the authors speculated that the resection of the entire infiltrated peritoneal tissue, together with a segment without macroscopic lesions, is feasible, safe, and could be used as a different cost-effective option than the hyperthermic intraperitoneal chemotherapy [64]. Tozzi *et al.* [65] recently reported the ten steps description of the standardized technique of En-bloc resection of the pelvis (EnBRP) as a part of Visceral Peritoneal Debulking (VPD). VPD is a radical debulking surgery for advanced ovarian cancer that often includes the en-bloc resection of the pelvis (EnBRP) internal genital organs, bladder, and pelvic peritoneum, and rectosigmoid colon. He reviewed the rate of complete resection (CR) and the outcomes of 200 patients treated with VPD who underwent EnBRP

(n = 96), dividing the study population into patients who underwent upfront and interval procedures after chemotherapy. Interestingly, CR was attained in all cases. Of the total, 96 patients (46%) required EnRBRP during the VPD, 48 and 44 patients were respectively in the upfront and interval surgery groups. The mortality rate was 1%, and DFS was 20 months, 25 in the upfront group and 15 in the interval surgery group. Interestingly, a case of bowel anastomosis dehiscence was recorded in each group, both successfully treated with a bowel diversion. In 2014, the same group started performing VPD by laparoscopy (L-VPD), and they further described the technique and evaluated the feasibility, efficacy, and morbidity of the EnBRP executed by laparoscopic approach (L-EnBRP) as a part of L-VPD at time of interval surgery in 58 patients IIIC/V FIGO stage ovarian cancer and gross residual disease following neoadjuvant chemotherapy. The L-EnBRP was feasible in 26 patients (45%), the efficacy was 100%, CR was achieved in 25 of 26 cases, and morbidity rate resulted in 5.5%. Patients who underwent L-EnBRP and L-VPD had faster discharge and lower blood loss than patients who underwent L-EnBRP but completed VPD by laparotomy. Extensive high tumor involvement on the diaphragm and mesentery was the leading cause for conversion in laparotomy [66]. Some of these operations are often personalized according to the involvement of pelvic anatomy by cancer and the related impairment of different organs functions. Interestingly, Kato *et al.* [67] reported a variation of the modified posterior pelvic exenteration procedure with concomitant pelvic sidewall resection in a 55-year-old woman requiring both urinary and bowel reconstructive surgery during up-front debulking FIGO stage IIIC ovarian cancer. In this peculiar case, the tumor mass involved the left internal iliac vessels and ureter so that surgeons performed a modified posterior pelvic exenteration with concomitant resection of the pelvic sidewall and partial ureterectomy. The vesicoureteral and colorectal anastomosis was completed after the resection of the omental and pelvic cancer. The author stated that even if bladder function was preserved in this patient, difficult spontaneous voiding function is experienced by some patients in the postoperative period, thus requiring self-intermittent catheterization after this complex multivisceral surgery.

6.2 Extensive Peritoneal Procedures

The finding of extensive peritoneal involvement characterizes most advanced ovarian cancer patients. Therefore, the treatment of peritoneal carcinomatosis spreading to the upper abdominal quadrants and the pelvis is crucial for optimal cytoreductive surgery. Since the extraperitoneal dissection technique for peritonectomy and pelvic organs was described by [53]; different operations, including pelvic peritonectomy, have been used in advanced ovarian cancer with extensive peritoneal involvement, thus increasing the rate of complete cytoreduction up to 60% [68]. This trend in achieving better debulking outcomes is parallel to the knowledge on new metastatic pathways theories affirming that ovarian cancer cells typically disseminate in intraperitoneal regions where peritoneal liquid stagnates. Thus, the paracolic grooves, the diaphragmatic dome, the omentum, and the pelvic peritoneum

are mainly involved by cancer nodules. In addition, the anterior wall of the rectosigmoid colon, the peritoneal lining of the rectosigmoid colon anterior wall, and the peritoneum of the cul-de-sac are the most typical sites of transperitoneal spreading and infiltration. Some authors had recently strained to test this technique in advanced surgical settings. For example, Kim *et al.* [69] reported a case of complete total parietal peritonectomy for the treatment of advanced ovarian cancer with extensive peritoneal cancer involvement. The radical multivisceral surgery was accomplished with a complete non-interrupted peritonectomy starting from the sub-diaphragmatic and paracolic peritoneum to the pelvic parietal peritoneum with en-bloc resection of pelvic organs. However, primary debulking surgery in such extreme advanced cases should be considered only because of a high likelihood for complete cytoreduction. Recently Muallem described the outcomes of a new interesting series of 58 patients who underwent primary cytoreductive surgery with a no-touch isolation technique in a retroperitoneal space to resect en bloc the parietal peritoneum and all the infiltrated organs in advanced ovarian cancer surgery. The outcomes of Total Retroperitoneal en bloc resection of Multivisceral-Peritoneal packet (TROMP procedure) were compared with those of 150 patients who underwent conventional debulking surgery. The complete cytoreduction was attained in 87.9% of cases treated with TROMP and 61.3% with traditional technique ($p = 0.001$). Interestingly, the difference in optimal cytoreduction resulted more robust in a sub-analysis of patients FIGO stages IIIC/IV; therefore, patients treated with TROMP, and traditional cytoreduction attained no residual after surgery respectively in 85.15 and 53.1%. Remarkably, the TROMP technique resulted in 33 minutes faster than traditional surgery, while perioperative complications were similar [70]. Furthermore, a new peritoneal stripping technique during a case of cytoreductive surgery with extensive intestinal mesentery involvement has been recently described. After complete liver mobilization, the procedure started blowing an injector needle of carbon dioxide gas into the retroperitoneal space. This specific maneuver facilitates the peritoneal detachment and subsequent right diaphragmatic peritoneum stripping from the falciform ligament-separated lower and upper diaphragmatic peritoneal margins and continues along with its tendinous and muscular parts. In case of deep infiltration of the diaphragm by cancer, this procedure could involve a full-thickness partial resection of the diaphragm. The technical feature of this procedure is that the dissection and stripping of the diaphragmatic peritoneum are continuous. A blunt and sharp dissection continues laterally and down without detaching the specimen, including Morrison peritoneum, right abdominal wall, and gutter toward the right pelvic brim peritoneal surfaces and analogously in the contralateral side. The uninterrupted peritoneal stripping continues with the canonical en bloc resection of all pelvic peritoneum and reproductive organs with the central tumor mass. Following the rationale of traditional laparoscopic surgery, the gas insufflation in the retroperitoneal area resulted in a suitable exposure of retroperitoneal areolar tissue and easier detachment of the peritoneal epithelial along its anatomical line. This pioneering technique could promise minimal bleeding and few potential complications like traditional laparo-

scopic procedures such as subcutaneous emphysema and CO₂ embolization. However, care must be taken to injury vessels while inserting the needle that should be inserted under the peritoneal surface using transillumination and superficially [71]. The same group further stressed the concept of total en bloc peritonectomy and pelvic en bloc resection confirming the feasibility of the above-described technique in a small series of debulking surgeries for FIGO stage IIC/IV ovarian cancer. This systematic novel intervention defined as a bat-shaped en-bloc total peritonectomy- total hysterectomy-salpingo-oophorectomy with or without rectosigmoid resection is named Sarta-Bat approach. This strategy has been preliminary tested in 9 cases of primary cytoreduction and 4 cases of interval debulking surgery and encompassed rectosigmoid resection in three cases. Interestingly the median CO₂ insufflation time was 5 minutes (2–10 min). No macroscopical residual was achieved in all cases, and no complications related to CO₂ insufflations were reported [72].

6.3 Extreme Surgeries for Lateral Extension

If pelvic exenteration was offered almost exclusively as a palliative procedure in the past because of its high associated morbidity, the evolution of neoadjuvant therapies emphasized the putative role as a curative option for the recurrence of central pelvic tumor in selected patients previously treated with radiation or chemotherapy. However, this debate is still open among gynecologic oncologic research groups, especially in ovarian cancer disease. Regarding alternative techniques of extensive pelvic en bloc resection for advanced ovarian cancer, it is interesting to note the description of some extreme exenterative surgeries for lateral extension of gynecologic malignancies. However, according to the current guidelines' indications, it is mandatory to highlight that the lateral extension and subsequent choice of extreme surgery is a rare condition in advanced ovarian cancer patients. In this view, lateral recurrence infiltrating the pelvic sidewall (PSW) has been considered an absolute contraindication to curative surgery. However, new evidence and data from reports about out-of-the-box pelvic surgery arise even if these data are not exclusive to ovarian cancer. Like many other standard oncologic surgeries, pelvic exenteration applies the theory of wide cancer excision designed as the complete and radical resection of the malignant tumor mass with a dimensionally defined perimetral margin of tissue free of cancer cells at the microscopic exam. This rationale assumes an isotropic centrifugal local cancer diffusion. According to the most robust evidence, pelvic exenteration should be exclusively designed for the excision of central pelvic tumors so that the exclusion of cancer spread at the pelvic wall is a pathologic criterion for patients' selection. Nowadays, the debate about this paradigm is growing, and changes in this traditional concept are coming up. The clinical translation of these understandings into ontogenetic cancer staging, surgical tumor field excision, and therapeutic lymphadenectomy could significantly advance prognostic valuation and curative options. Hoekel and colleagues first reported a long-term experience with laterally extended endopelvic resection (LEER) in recurrent pelvic cancer in 140 patients, 86 of whom

received LEER as a salvage therapeutic option for relapsed cervical cancer. LEER was conceptualized by developing and applying the cancer field theory to malignant advanced gynecologic tumors with a tendency to clinical progression. LEER was designed to achieve complete cancer field resection in ontogenetic stage III and R0 tumor removal in specific cases of ontogenetic stage IV malignancies. Indeed, the rationale of LEER operation is slightly different from pelvic exenteration that aims to resect all pelvic organs en-bloc. The surgical specimen included internal iliac vessels, thus allowing complete removal of the urogenital mesentery, a significant path of locoregional tumor diffusion. Reporting oncologic outcomes of patients who underwent LEER, the authors underlined that no patient died, and exclusive pelvic cancer progression was identified in six (7%) cases at a median follow-up of 48.5 months. Extrapelvic metastasis were diagnosed in thirty-two (37%) patients, 12 with concomitant pelvic involvement. Five-year OS and recurrence-free survival probability were 59% and 54%, respectively. The sub-analysis of a specific group of 76 women with recurrence of cervical cancer proved the relevance of ontogenetic staging even for recurrency of persistence of disease. Five-year OS and recurrence-free survival probability for stage III tumors (n = 32) was 71% and 65%, and for stage IV tumors (n = 44) 46% and 39%, respectively [73].

Andykyan *et al.* [74] evaluated 22 cases of patients who underwent an even more demolitive pelvic procedure named extended pelvic resection (EPR) for cervical and uterine recurrent or persistent advanced cancer with a median follow-up time was 28 months. In EPR, the anatomical structures encompassed in extended radical excision were muscle (n = 13), nerve (n = 10), bone (n = 8), vessel (n = 5). Complete cytoreduction with microscopically negative margins was attained in 17 cases (77%). No perioperative deaths but major postoperative complications were described in 14 cases (64%). The two most frequent complications were peripheral neuropathies and pelvic abscesses. Remarkably, the 5-year OS for the entire cohort was 34%, while for the 17 patients who had an R0 resection 48%, and in patients with positive margins at histology (n = 5), 0% respectively. Vizzielli *et al.* [37] reported morbidity and oncological outcomes of 8 consecutive cases of isolated recurrence involving the pelvic sidewall (PSW), including the iliopsoas muscle treated with lateral endopelvic resection (LEPR); defined as en bloc lateral resection of a pelvic tumor with sidewall muscle, with eventual bone, major vascular and nerve as adjunctive concomitant procedures. Only three out of 8 patients had primary ovarian cancer and all attained R0 resection with LEPR after neoadjuvant therapy; no perioperative mortality and increase of PFS (24, 24 and 12 months) and OS (24, 24, and 28 months) were described. The same group reported data about 63 patients with recurrency gynecologic malignancies and PSW involvement treated with the LEPR technique. In this series, a total of 17 patients had a diagnosis of ovarian cancer. Of the total, 14 patients achieved R0 and three patients R 1–2. After accurate selection of the patients, the authors concluded that LEPR could be proposed as a therapeutic option with curative potential in recurrent or persistent gynecological cancer infiltrating PSW [75]. Different case series on alternative radical and extreme exenterative surgery techniques for frozen pelvis in gynecologic cancers

have been reported in the last five years. However, the relevance of these reports in the field of advanced ovarian cancer operations seems to be limited because among the enrolled patients, few women had a diagnosis of ovarian cancer, and reported outcomes are often heterogeneous according to the variability of the primary tumor.

6.4 The Robotic Challenge

Interestingly, there has been increasing interest in studying the role of the robotic approach in ovarian cancer. Some reports have demonstrated the feasibility of robotic-assisted surgery in the staging of early disease and the treatment of primary or secondary cytoreduction in highly selected cases [76]. In these patients, robotic surgery and conventional laparoscopic approach seem to have similar surgical and oncologic outcomes, with a faster learning curve but increased costs for robotic assistance. Nevertheless, there is no data about en-bloc resection of reproductive organs and rectosigmoid or exenterative procedures in patients with extensive ovarian cancer disease can be performed robotically. It has been hypothesized that the limitation of the first robotic platforms to reach the four quadrants of the abdomen requiring rotation of the operating table, multiple docking, and additional access could play a key role in the lack of widespread acceptance of this minimally invasive approach in multi quadrant gynecological surgery. Nowadays, the consistent use of the Xi Da Vinci platform has improved some of the limits of the past S and Si systems to reach all operative fields in all the upper abdomen. Furthermore, the possibility of interchanging the camera position in different robotic ports, thus accessing disease in all different quadrants and the 180° rotation of the robotic arms, makes it possible to reach the pelvis and upper abdominal quadrants without rotation of the operating table. Even if preliminary data on secondary cytoreductive surgery [77], complex radical procedures on the diaphragm [78], or vessels lesions [79] in selective cases of advanced ovarian cancer have been reported using different robotic platforms, data about en-block robotic resection of pelvic tumor mass on frozen pelvis are still lacking.

7. Postoperative Care and Complications

It is well known that postoperative morbidity and complications related to radical multivisceral operations is a central matter. Patients with diabetes mellitus, low hemoglobin level or albumin at preoperative exam, increased age and intraoperative blood loss, or long operating times are at increased risk of surgical complications. Complications are also related to the nutritional status of patients, thus suggesting that parenteral nutrition during the preoperative period can be beneficial for malnourished women enrolled for extensive pelvic excision of tumor mass [62]. Several associated radical exenterative operations such as diaphragmatic peritonectomy or partial resection, subtotal liver, pancreatic, colon, and multiple bowel segments resection and splenectomy are almost exclusively performed by advanced skilled gynecologic oncology surgeons for achieving complete cytoreduction even in a frozen pelvis.

Nevertheless, a significant percentage of patients who underwent debulking surgery are likely to experience minor or severe complications during the perioperative period. The most frequently reported complications in ovarian malignancies after en-bloc resection of reproductive organs and colorectal segments are postoperative febrile morbidity, hemorrhage, and bothersome prolonged ileus. More rare but potentially critical complications include leakage of anastomosis site, sutures dehiscence or rectovaginal fistula, infection, cardiovascular, renal, pulmonary, and thromboembolic events. All these severe complications increase postoperative mortality.

There are no consistent and conclusive data about complications after radical oophorectomy and en-bloc resection of rectosigmoid for the frozen pelvis. However, retrospective studies reported that patients who underwent radical oophorectomy and other extensive pelvic exenterations experience significant postoperative complications in 12% to 49% of cases. Interestingly, the use of the current intensive postoperative care protocols seems to reduce the operative mortality from 1.5% to 3.1% [52]. Aletti *et al.* [80] retrospectively reported 30-day morbidity and 3-month mortality rates of 18.4% and 4.5%, respectively, after ultraradical cytoreductive procedure for advanced ovarian cancer in three different referral centers. After applying a risk prediction model, the same authors detected risk of complication ranging from 4.5% to 54.3%, significantly influencing patients' quality of life and general costs. Patients needing extensive pelvic surgery are often malnourished. Therefore, total parenteral nutritional support might be prescribed before and after the operations until restoring a proper intestinal function. In this view, optimal preparation of patients before surgery, minimizing preoperative dehydration, and maintaining normovolemia together with an infusion of balanced crystalloid as liquid support after intestinal operations is recommended also during the postoperative period. Prolonged ileus after en bloc resection and rectosigmoidectomy for advanced EOC occurs in 4.3–9.3% of cases like colorectal surgery procedures. This frequent postoperative condition is characterized by nausea and vomiting, need for reinsertion of a nasogastric tube, inability to tolerate diet, absence or delayed return of bowel sounds or flatus, distension of the abdomen, and presence of signs of ileus on scan over seven days [20]. In this view, an adequate perioperative nutritional status and faster feeding after surgery in the absence of any intraoperative contraindications are central for a significant earlier recovery of intestinal function and faster tolerance of regular diet. Hence, several scientific societies endorsed and adopted protocols for early enteral and oral feeding according to data that demonstrated low risks of postoperative infection and no correlation with increased risk of anastomotic leakage or dehiscence [81].

Generally, the prediction of postoperative risk-averse events related to surgery is most challenging. Therefore, the management of complications starts with prevention and early identification of possible intraoperative risks that occurred during and at the end of the procedure. Accurate check of bowel segments, bladder integrity, hemostasis, and the inspection of other sites of radical excision of cancer nodules are always mandatory. Whereas the integrity of the bladder is generally simple; the monitoring of the bowel anastomotic site is complex.

After colon resection during radical pelvic surgery, one of the most severe complications is the failure of the anastomosis and the consequent clinical anastomotic leakage. This feared complication is identified as drainage of fecal liquid or extravasations of anastomosis area and can be confirmed with a CT scan and patient clinical symptoms. Also, the clinical diagnosis of anastomotic leak significantly increases morbidity and mortality rates and can negatively impact the long-term functional outcomes. Interestingly, several data from colorectal surgery reported that anastomotic leakage is strongly related to intraoperative blood loss, need for transfusion, and prolonged operative time. Nevertheless, others recommended that ileostomies be indicated for patients with low (<6 cm from the anal verge) anastomosis [82]. The inspection of proximal and distal doughnuts of the resected colon and a test with trans-anal air insufflation assess the security of the stapled colorectal anastomosis. The check for possible bleeding in the anastomotic staple site can be additionally performed rectal. The absence of tension at the stapled colorectal anastomosis can ensure passing two fingers underneath the sigmoid so that an end colostomy or rarely a protective ileostomy must be confectioned if a reliable anastomosis is not feasible. The anastomosis site could be drained using Jackson-Pratt or Robinson drains, and a drain can be inserted via the anus in doubtful cases at the end of the surgery [65]. The rationale of restoring the intestinal continuity after rectosigmoidectomy as a part of extensive cytoreduction has been largely argued in the past. The main concerns were related to the perioperative conditions of patients who frequently are malnourished, experience bowel sub-obstruction or obstruction, or have copious ascites. In the initial series of radical oophorectomy with en-bloc rectosigmoidectomy in high stages ovarian cancer, 12% to 59% of patients underwent a temporary or permanent bowel diversion. More recent studies reported that primary colorectal anastomosis using an automated stapling device resulted in 3.2% of anastomotic dehiscence needing reintervention with colostomy even though a large volume of ascites (≥ 1000 mL) was present in 71% of cases. Others have described anastomotic leakage in 0–8% of patients who underwent sigmoidectomy, and subsequent both stapled and hand-sewn anastomosis for ovarian cancer patients. Other series reported an anastomosis dehiscence rate of 0.8 to 6.8% in patients who experienced rectosigmoidectomy [83]. Interestingly, Bristow *et al.* [52] reported a 2.1% to 3.1% incidence of anastomotic leakage among patients with high volume (≥ 500 mL) ascites. The critical analysis of these data may advise that defecatory functionality can be routinely conserved in patients who underwent this complex multivisceral surgery and that preventive bowel diversion is unnecessary in most cases. However, data from Mayo Clinic reported an increased number of anastomosis dehiscences in patients with multiple extensive intestinal resections, thus determining a delay in chemotherapy program with a decrease in survival rate. Accordingly, a protective ostomy is not required in routine cases but can be planned after multiple intestinal resections, low anastomosis, or preceding radiation programs as all these circumstances increase the risk of complications in the anastomosis site [83]. Since blood loss reported among cases of radical oophorectomy may range from 800 mL to 2900

mL, postoperative transfusion criteria are individualized and determined independently by the gynecologic oncologist, pulmonologist, intensivists, and medical team [52]. The improvement of anesthesiologic and intensive care protocols and the novel interventional radiology procedures allow the treatment of most complications with good clinical outcomes. However, these adverse events are often caused by rehospitalization and reintervention, thus significantly affecting the quality of life of oncologic patients and their familiars. Consequently, comprehensive, and accurate counseling on the challenges and consequences of hospitalization is an important integrative part of oncologic care.

8. Conclusions

In many cases of primary ovarian cancer metastases extensively involve the cul-de-sac, pelvic peritoneum, rectosigmoid colon, vagina, and uterus; generally, these structures are encased in tumor mass in the so-called “frozen pelvis”. The finding of inseparable pelvic organs in cases of advanced ovarian cancer may predict a challenging operation and poor oncologic outcome. In the past, radical oophorectomy surgery for advanced ovarian cancer was performed with a retroperitoneal approach, but the rectosigmoid tumor was usually separately excised, with a sigmoid resection performed. Biological and histological data demonstrated a peculiar capacity of diffusion and infiltration of EOC. When the tumor solely involves the peritoneum on the surface of Douglas pouch, the retrograde hysterectomy technique with en block excision of the peritoneum by Hudson can be used. Nevertheless, colorectal resection is mandatory if this procedure does not entirely remove cancer from the anterior rectosigmoid wall. During the last two decades, the technique of radical oophorectomy with en-bloc resection of rectosigmoid for the frozen pelvis has gained popularity, and different surgical steps have been standardized to ease replication and used for teaching purposes. Moreover, the reduction of bleeding and the oncologic effectiveness of this cytoreductive procedure fit well together with the concept of the complete multiorgan debulking required in advanced ovarian cancer. In this view, the use of this standardized radical surgery allows the safe and comprehensive removal of all pelvic cancer in patients with advanced ovarian disease. This manuscript is an extensive updated technical overview from the pioneering series of our retired mentors to the current evolving surgical breakthroughs. Nowadays, this complex exenterative surgery paradigm for the frozen pelvis in advanced ovarian cancer is still changing because the innovative biological, genetic knowledge is continuously growing and evolving parallel to the advanced perioperative, anesthesiologic, and radiologic care. Therefore, this document offers an additional tool in the portfolio of the young surgeons approaching this challenging multiorgan surgery that could encompass multidisciplinary specialists in selected cases but is mostly dominated by gynecologic oncologic surgeons.

AUTHOR CONTRIBUTIONS

AG and KB reviewed literature and wrote the manuscript, edited the manuscript and participated to contents analysis and

implementation. All authors contributed to editorial changes in the manuscript. All authors read and approved the final manuscript.

ETHICS APPROVAL AND CONSENT TO PARTICIPATE

Not applicable.

ACKNOWLEDGMENT

We would like to express our gratitude to all those who helped us during the writing of this manuscript. Thanks to all the peer reviewers for their opinions and suggestions.

FUNDING

This research received no external funding.

CONFLICT OF INTEREST

AG is serving as one of the Review Board members of this journal. We declare that AG had no involvement in the peer review of this article and has no access to information regarding its peer review. Full responsibility for the editorial process for this article was delegated to Enrique Hernandez. The other author declares no conflict of interest.

REFERENCES

- [1] Heintz AP, Odicino F, Maisonneuve P, Quinn MA, Benedet JL, Creasman WT, *et al.* Carcinoma of the fallopian tube. FIGO 26th Annual Report on the Results of Treatment in Gynecological Cancer. *International Journal of Gynecology & Obstetrics.* 2006; 95: S145–S160.
- [2] du Bois A, Reuss A, Pujade-Lauraine E, Harter P, Ray-Coquard I, Pfisterer J. Role of surgical outcome as prognostic factor in advanced epithelial ovarian cancer: a combined exploratory analysis of 3 prospectively randomized phase 3 multicenter trials. *Cancer.* 2009; 115: 1234–1244.
- [3] Bristow RE, Tomacruz RS, Armstrong DK, Trimble EL, Montz FJ. Survival Effect of Maximal Cytoreductive Surgery for Advanced Ovarian Carcinoma during the Platinum Era: a Meta-Analysis. *Journal of Clinical Oncology.* 2002; 20: 1248–1259.
- [4] Chang S, Hodeib M, Chang J, Bristow RE. Survival impact of complete cytoreduction to no gross residual disease for advanced-stage ovarian cancer: a meta-analysis. *Gynecologic Oncology.* 2013; 130: 493–498.
- [5] Eisenkop SM, Spirtos NM, Friedman RL, Lin WM, Pisani AL, Peticucci S. Relative influences of tumor volume before surgery and the cytoreductive outcome on survival for patients with advanced ovarian cancer: a prospective study. *Gynecologic Oncology.* 2003; 90: 390–396.
- [6] Griffiths CT. Surgical resection of tumor bulk in the primary treatment of ovarian carcinoma. *Journal of the National Cancer Institute. Monographs.* 1975; 42: 101–104.
- [7] Hacker NF, Berek JS, Lagasse LD, Nieberg RK, Elashoff RM. Primary cytoreductive surgery for epithelial ovarian cancer. *Obstetrics & Gynecology.* 1983; 61: 413–420.
- [8] Bertelsen K. Tumor reduction surgery and long-term survival in advanced ovarian cancer: a DACOVA study. *Gynecologic Oncology.* 1990; 38: 203–209.
- [9] Winter WE, Maxwell GL, Tian C, Sundborg MJ, Rose GS, Rose PG, *et al.* Tumor residual after surgical cytoreduction in prediction of clinical outcome in stage IV epithelial ovarian cancer: a Gynecologic Oncology Group Study. *Journal of Clinical Oncology.* 2008; 26: 83–89.
- [10] Horowitz NS, Miller A, Rungruang B, Richard SD, Rodriguez N, Bookman MA, *et al.* Does Aggressive Surgery Improve Outcomes? Interaction between Preoperative Disease Burden and Complex Surgery in Patients with Advanced-Stage Ovarian Cancer: an Analysis of GOG 182. *Journal of Clinical Oncology.* 2015; 33: 937–943.
- [11] Chi DS, Eisenhauer EL, Zivanovic O, Sonoda Y, Abu-Rustum NR, Levine DA, *et al.* Improved progression-free and overall survival in advanced ovarian cancer as a result of a change in surgical paradigm. *Gynecologic Oncology.* 2009; 114: 26–31.
- [12] Ataseven B, Grimm C, Harter P, Heitz F, Traut A, Prader S, *et al.* Prognostic impact of debulking surgery and residual tumor in patients with epithelial ovarian cancer FIGO stage IV. *Gynecologic Oncology.* 2016; 140: 215–220.
- [13] Bristow RE, Chang J, Ziogas A, Campos B, Chavez LR, Anton-Culver H. Impact of National Cancer Institute Comprehensive Cancer Centers on ovarian cancer treatment and survival. *Journal of the American College of Surgeons.* 2015; 220: 940–950.
- [14] Vergote I, Tropé CG, Amant F, Kristensen GB, Ehlen T, Johnson N, *et al.* Neoadjuvant Chemotherapy or Primary Surgery in Stage IIIC or IV Ovarian Cancer. *New England Journal of Medicine.* 2010; 363: 943–953.
- [15] Kehoe S, Hook J, Nankivell M, Jayson GC, Kitchener H, Lopes T, *et al.* Primary chemotherapy versus primary surgery for newly diagnosed advanced ovarian cancer (CHORUS): an open-label, randomised, controlled, non-inferiority trial. *Lancet.* 2015; 386: 249–257.
- [16] Armstrong DK, Alvarez RD, Bakkum-Gamez JN, Barroilhet L, Behbakht K, Berchuck A, *et al.* Ovarian Cancer, Version 2.2020, NCCN Clinical Practice Guidelines in Oncology. *Journal of the National Comprehensive Cancer Network.* 2021; 19: 191–226.
- [17] Colombo N, Sessa C, du Bois A, Ledermann J, McCluggage WG, McNeish I, *et al.* ESMO-ESGO consensus conference recommendations on ovarian cancer: pathology and molecular biology, early and advanced stages, borderline tumours and recurrent disease[†]. *Annals of Oncology.* 2019; 30: 672–705.
- [18] Ramirez PT. Standardizing ovarian cancer surgery and peri-operative care: a European Society of Gynecological Oncology (ESGO) consensus statement. *International Journal of Gynecological Cancer.* 2021; 31: 1207–1208.
- [19] Chang S, Bristow RE. Evolution of surgical treatment paradigms for advanced-stage ovarian cancer: redefining ‘optimal’ residual disease. *Gynecologic Oncology.* 2012; 125: 483–492.
- [20] Son J, Kim J, Shim J, Kong T, Paek J, Chang S, *et al.* Comparison of posterior rectal dissection techniques during rectosigmoid colon resection as part of cytoreductive surgery in patients with epithelial ovarian cancer: Close rectal dissection versus total mesorectal excision. *Gynecologic Oncology.* 2019; 153: 362–367.
- [21] Hoffman MS, Griffin D, Tebes S, Cardosi RJ, Martino MA, Fiorica JV, *et al.* Sites of bowel resected to achieve optimal ovarian cancer cytoreduction: implications regarding surgical management. *American Journal of Obstetrics and Gynecology.* 2005; 193: 582–588.
- [22] Lengyel E. Ovarian cancer development and metastasis. *The American Journal of Pathology.* 2010; 177: 1053–1064.
- [23] Orosco RK, Tapia VJ, Califano JA, Clary B, Cohen EEW, Kane C, *et al.* Positive Surgical Margins in the 10 most Common Solid Cancers. *Scientific Reports.* 2018; 8: 5686.
- [24] Barber HR, Brunschwig A. Pelvic exenteration for locally advanced and recurrent ovarian cancer. Review of 22 cases. *Surgery.* 1965; 58: 935–937.
- [25] Hudson CN. A radical operation for fixed ovarian tumours. *The Journal of Obstetrics and Gynaecology of the British Commonwealth.* 1968; 75: 1155–1160.
- [26] BRUNSCHWIG A. Complete excision of pelvic viscera for advanced carcinoma; a one-stage abdominoperineal operation with end colostomy and bilateral ureteral implantation into the colon above the colostomy. *Cancer.* 2008; 1: 177–183.
- [27] Hudson CN, Chir M. Surgical treatment of ovarian cancer. *Gynecologic Oncology.* 1973; 1: 370–378.
- [28] Clayton RD, Obermair A, Hammond IG, Leung YC, McCartney AJ. The Western Australian experience of the use of en bloc resection of ovarian cancer with concomitant rectosigmoid colectomy. *Gynecologic Oncology.* 2002; 84: 53–57.

- [29] Berek JS, Hacker NF, Lagasse LD. Rectosigmoid colectomy and reanastomosis to facilitate resection of primary and recurrent gynecologic cancer. *Obstetrics and Gynecology*. 1984; 64: 715–720.
- [30] Soper JT, Couchman G, Berchuck A, Clarke-Pearson D. The role of partial sigmoid colectomy for debulking epithelial ovarian carcinoma. *Gynecologic Oncology*. 1991; 41: 239–244.
- [31] Obermair A, Hagenauer S, Tamandl D, Clayton RD, Nicklin JL, Perrin LC, *et al.* Safety and efficacy of low anterior en bloc resection as part of cytoreductive surgery for patients with ovarian cancer. *Gynecologic Oncology*. 2001; 83: 115–120.
- [32] Bridges JE, Leung Y, Hammond IG, McCartney AJ. En bloc resection of epithelial ovarian tumors with concomitant rectosigmoid colectomy: the KEMH experience. *International Journal of Gynecological Cancer*. 2013; 3: 199–202.
- [33] Barnes W, Johnson J, Waggoner S, Barter J, Potkul R, Delgado G. Reverse hysterocolposigmoidectomy (RHCS) for resection of panpelvic tumors. *Gynecologic Oncology*. 1991; 42: 151–155.
- [34] Sugarbaker PH. Complete parietal and visceral peritonectomy of the pelvis for advanced primary and recurrent ovarian cancer. *Cancer Treatment and Research*. 1996; 81: 75–87.
- [35] Sainz de la Cuesta R, Goodman A, Halverson SS. En bloc pelvic peritoneal resection of the intraperitoneal pelvic viscera in patients with advanced epithelial ovarian cancer. *The Cancer Journal from Scientific American*. 2006; 2: 152–157.
- [36] Eisenkop SM, Nalick RH, Teng NN. Modified posterior exenteration for ovarian cancer. *Obstetrics and Gynecology*. 1991; 78: 879–885.
- [37] Vizzielli G, Chiantera V, Tinelli G, Fagotti A, Gallotta V, Di Giorgio A, *et al.* Out-of-the-box pelvic surgery including iliopsoas resection for recurrent gynecological malignancies: does that make sense? a single-institution case-series. *European Journal of Surgical Oncology*. 2017; 43: 710–716.
- [38] Vanderpuye VD, Clemenceau JRV, Temin S, Aziz Z, Burke WM, Cevallos NL, *et al.* Assessment of Adult Women with Ovarian Masses and Treatment of Epithelial Ovarian Cancer: ASCO Resource-Stratified Guideline. *JCO Global Oncology*. 2021; 3: 1032–1066.
- [39] Salani R, Bristow RE. Surgical management of epithelial ovarian cancer. *Clinical Obstetrics and Gynecology*. 2012; 55: 75–95.
- [40] van de Vrie R, Rutten MJ, Asseler JD, Leeftang MM, Kenter GG, Mol BWJ, *et al.* Laparoscopy for diagnosing resectability of disease in women with advanced ovarian cancer. *Cochrane Database of Systematic Reviews*. 2019; 3: CD009786.
- [41] Fagotti A, Ferrandina G, Fanfani F, Garganese G, Vizzielli G, Carone V, *et al.* Prospective validation of a laparoscopic predictive model for optimal cytoreduction in advanced ovarian carcinoma. *American Journal of Obstetrics and Gynecology*. 2008; 199: 642.e1–642.e6.
- [42] Chi DS, Musa F, Dao F, Zivanovic O, Sonoda Y, Leitao MM, *et al.* An analysis of patients with bulky advanced stage ovarian, tubal, and peritoneal carcinoma treated with primary debulking surgery (PDS) during an identical time period as the randomized EORTC-NCIC trial of PDS vs neoadjuvant chemotherapy (NACT). *Gynecologic Oncology*. 2012; 124: 10–14.
- [43] Grimes WR, Stratton M. Pelvic Exenteration. 2021 Oct 9. In *StatPearls*. StatPearls Publishing: Treasure Island (FL). 2022.
- [44] Cao F, Li J, Li F. Mechanical bowel preparation for elective colorectal surgery: updated systematic review and meta-analysis. *International Journal of Colorectal Disease*. 2012; 27: 803–810.
- [45] Dolejs SC, Guzman MJ, Fajardo AD, Robb BW, Holcomb BK, Zarzaur BL, *et al.* Bowel Preparation is Associated with Reduced Morbidity in Elderly Patients Undergoing Elective Colectomy. *Journal of Gastrointestinal Surgery*. 2017; 21: 372–379.
- [46] Atkinson SJ, Swenson BR, Hanseman DJ, Midura EF, Davis BR, Rafferty JF, *et al.* In the Absence of a Mechanical Bowel Prep, does the Addition of Pre-Operative Oral Antibiotics to Parental Antibiotics Decrease the Incidence of Surgical Site Infection after Elective Segmental Colectomy? *Surgical Infections*. 2015; 16: 728–732.
- [47] Dowdy SC. Enhanced recovery after surgery for ovarian cancer. *Clinical Advances in Hematology & Oncology*. 2019; 17: 217–219.
- [48] Gustafsson UO, Scott MJ, Hubner M, Nygren J, Demartines N, Francis N, *et al.* Guidelines for Perioperative Care in Elective Colorectal Surgery: Enhanced Recovery After Surgery (ERAS®) Society Recommendations: 2018. *World Journal of Surgery*. 2019; 43: 659–695.
- [49] Kalogera E, Van Houten HK, Sangaralingham LR, Borah BJ, Dowdy SC. Use of bowel preparation does not reduce postoperative infectious morbidity following minimally invasive or open hysterectomies. *American Journal of Obstetrics and Gynecology*. 2020; 223: 231.e1–231.e12.
- [50] Nelson RL, Gladman E, Barbateskovic M. Antimicrobial prophylaxis for colorectal surgery. *Cochrane Database of Systematic Reviews*. 2009; (1): CD001181.
- [51] Carter J, Chi DS, Abu-Rustum N, Brown CL, McCreath W, Barakat RR. Brief report: Total pelvic exenteration—a retrospective clinical needs assessment. *Psycho-Oncology*. 2004; 13: 125–131.
- [52] Bristow RE, del Carmen MG, Kaufman HS, Montz FJ. Radical oophorectomy with primary stapled colorectal anastomosis for resection of locally advanced epithelial ovarian cancer. *Journal of the American College of Surgeons*. 2003; 197: 565–574.
- [53] Sugarbaker PH. Peritonectomy procedures. *Surgical Oncology Clinics of North America*. 2003; 12: 703–27, xiii.
- [54] Kim M, Noh JJ, Lee Y. En bloc pelvic resection of ovarian cancer with rectosigmoid colectomy: a literature review. *Gland Surgery*. 2021; 10: 1195–1206.
- [55] Warton B. Technical advances in treatment of gynaecological malignancy. *Australian Family Physician*. 1983; 12: 413–414, 416.
- [56] Magrina JF. Types of pelvic exenterations: a reappraisal. *Gynecologic Oncology*. 1990; 37: 363–366.
- [57] Magrina JF, Stanhope CR, Weaver AL. Pelvic Exenterations: Suprlevator, Infralevator, and with Vulvectomy. *Gynecologic Oncology*. 1997; 64: 130–135.
- [58] Gillette-Cloven N, Burger RA, Monk BJ, McMeekin DS, Vasilev S, DiSaia PJ, *et al.* Bowel resection at the time of primary cytoreduction for epithelial ovarian cancer. *Journal of the American College of Surgeons*. 2001; 193: 626–632.
- [59] Hertel H, Diebolder H, Herrmann J, Köhler C, Kühne-Heid R, Possover M, *et al.* Is the decision for colorectal resection justified by histopathologic findings: a prospective study of 100 patients with advanced ovarian cancer. *Gynecologic Oncology*. 2001; 83: 481–484.
- [60] Kim M, Suh DH, Park JY, Paik ES, Lee S, Eoh KJ, *et al.* Survival impact of low anterior resection in patients with epithelial ovarian cancer grossly confined to the pelvic cavity: a Korean multicenter study. *Journal of Gynecologic Oncology*. 2018; 29: e60.
- [61] Mourton SM, Temple LK, Abu-Rustum NR, Gemignani ML, Sonoda Y, Bochner BH, *et al.* Morbidity of rectosigmoid resection and primary anastomosis in patients undergoing primary cytoreductive surgery for advanced epithelial ovarian cancer. *Gynecologic Oncology*. 2005; 99: 608–614.
- [62] Park J, Seo S, Kang S, Lee KB, Lim SY, Choi HS, *et al.* The benefits of low anterior en bloc resection as part of cytoreductive surgery for advanced primary and recurrent epithelial ovarian cancer patients outweigh morbidity concerns. *Gynecologic Oncology*. 2006; 103: 977–984.
- [63] Aletti GD, Podratz KC, Jones MB, Cliby WA. Role of rectosigmoidectomy and stripping of pelvic peritoneum in outcomes of patients with advanced ovarian cancer. *Journal of the American College of Surgeons*. 2006; 203: 521–526.
- [64] Sznurkowski JJ. En bloc pelvic resection for advanced ovarian cancer preceded by central ligation of vessels supplying the tumor bed: a description of surgical technique and a feasibility study. *World Journal of Surgical Oncology*. 2016; 14: 133.
- [65] Tozzi R, Hardern K, Gubbala K, Garruto Campanile R, Soleymani majd H. En-bloc resection of the pelvis (EnBRP) in patients with stage IIIC–IV ovarian cancer: a 10 steps standardised technique. Surgical and survival outcomes of primary vs. interval surgery. *Gynecologic Oncology*. 2017; 144: 564–570.
- [66] Tozzi R, Gubbala K, majd HS, Campanile RG. Interval Laparoscopic En-Bloc Resection of the Pelvis (L-EnBRP) in patients with stage IIIC–IV ovarian cancer: Description of the technique and surgical outcomes. *Gynecologic Oncology*. 2016; 142: 477–483.
- [67] Kato K, Omi M, Fusegi A, Takeshima N. Modified posterior pelvic exenteration with pelvic side-wall resection requiring both intestinal and urinary reconstruction during surgery for ovarian cancer. *Gynecologic Oncology*. 2019; 155: 172–173.

- [68] Chang SJ, Bristow RE. Surgical technique of en bloc pelvic resection for advanced ovarian cancer. *Journal of Gynecologic Oncology*. 2015; 26: 155.
- [69] Kim HS, Bristow RE, Chang S. Total parietal peritonectomy with en bloc pelvic resection for advanced ovarian cancer with peritoneal carcinomatosis. *Gynecologic Oncology*. 2016; 143: 688–689.
- [70] Muallem MZ, Sehouli J, Miranda A, Richter R, Muallem J. Total retroperitoneal en bloc resection of multivisceral-peritoneal packet (TROMP operation): a novel surgical technique for advanced ovarian cancer. *International Journal of Gynecological Cancer*. 2020; 30: 648–653.
- [71] Khatib G, Guzel AB, Gulec UK, Vardar MA. A novel technique: Carbon dioxide gas-assisted total peritonectomy, diaphragm and intestinal meso stripping in open surgery for advanced ovarian cancer (Çukurova technique). *Gynecologic Oncology*. 2017; 146: 674–675.
- [72] Khatib G, Seyfettinoglu S, Guzel AB, Gulec UK, Unlugenc H, Vardar MA. Feasibility and rationale of a novel approach in advanced ovarian cancer surgery: Bat- shaped en-bloc total peritonectomy and total hysterectomy salpingo-oophorectomy with or without rectosigmoid resection (Sarta-Bat approach). *Gynecologic Oncology*. 2021; 161: 97–103.
- [73] Höckel M. Long-term experience with (laterally) extended endopelvic resection (LEER) in relapsed pelvic malignancies. *Current Oncology Reports*. 2015; 17: 435.
- [74] Andikyan V, Khoury-Collado F, Sonoda Y, Gerst SR, Alektiar KM, Sandhu JS, *et al.* Extended pelvic resections for recurrent or persistent uterine and cervical malignancies: an update on out of the box surgery. *Gynecologic Oncology*. 2012; 125: 404–408.
- [75] Vizzielli G, Naik R, Dostalek L, Bizzarri N, Kucukmetin A, Tinelli G, *et al.* Laterally Extended Pelvic Resection for Gynaecological Malignancies: a Multicentric Experience with out-of-the-Box Surgery. *Annals of Surgical Oncology*. 2019; 26: 523–530.
- [76] Zanagnolo V, Garbi A, Achilarré MT, Minig L. Robot-assisted Surgery in Gynecologic Cancers. *Journal of Minimally Invasive Gynecology*. 2017; 24: 379–396.
- [77] Magrina JF, Zanagnolo V, Noble BN, Kho RM, Magtibay P. Robotic approach for ovarian cancer: perioperative and survival results and comparison with laparoscopy and laparotomy. *Gynecologic Oncology*. 2011; 121: 100–105.
- [78] Magrina JF, Magtibay PM. Robotic Resection of Diaphragm Metastases in Ovarian Cancer: Technical Aspects. *Journal of Minimally Invasive Gynecology*. 2020; 27: 1417–1422.
- [79] Mutlu L, Khadraoui W, Khader T, Menderes G. Robotic Tumor Debulking off External Iliac Vessels for the Management of Recurrent Ovarian Cancer. *Journal of Minimally Invasive Gynecology*. 2020; 27: 1021–1022.
- [80] Aletti GD, Santillan A, Eisenhauer EL, Hu J, Aletti G, Podratz KC, *et al.* A new frontier for quality of care in gynecologic oncology surgery: multi-institutional assessment of short-term outcomes for ovarian cancer using a risk-adjusted model. *Gynecologic Oncology*. 2007; 107: 99–106.
- [81] Lewis SJ, Egger M, Sylvester PA, Thomas S. Early enteral feeding versus “nil by mouth” after gastrointestinal surgery: systematic review and meta-analysis of controlled trials. *British Medical Journal*. 2001; 323: 773–776.
- [82] Tozzi R, Casarin J, Garruto-Campanile R, Majd HS, Morotti M. Morbidity and reversal rate of ileostomy after bowel resection during Visceral-Peritoneal Debulking (VPD) in patients with stage IIIC-IV ovarian cancer. *Gynecologic Oncology*. 2018; 148: 74–78.
- [83] Kalogera E, Dowdy SC, Mariani A, Weaver AL, Aletti G, Bakkum-Gomez JN, *et al.* Multiple large bowel resections: potential risk factor for anastomotic leak. *Gynecologic Oncology*. 2013; 130: 213–218.

How to cite this article: Andrea Giannini, Kristina A. Butler. Surgical management in the pelvis for patients with advanced ovarian cancer. *European Journal of Gynaecological Oncology*. 2022; 43(3): 9-24. doi: 10.22514/ejgo.2022.003.