EJGO European Journal of Gynaecological Oncology

Isolated axillary nodal swelling and cancer of unknown primary

S. Bertozzi[1], A.P. Londero[2], R. Petri[1], S. Bernardi[1]

[1] *Department of Surgery, Azienda Ospedaliero-Universitaria "Santa Maria della Misericordia", Udine*
[2] *Clinic of Obstetrics and Gynecology, Azienda Ospedaliero-Universitaria "Santa Maria della Misericordia", Udine (Italy)*

Summary

Introduction: The literature reports rare cases of isolated axillary lymph node metastasis from cancer of unknown primary (CUP). The authors reviewed the prevalence and outcome of patients with isolated axillary nodal swelling suspicious for malignancy affected or not by isolated axillary node metastasis from CUP. *Materials and Methods:* The authors collected data about 65 patients presented with isolated axillary lymph node swelling who underwent axillary lymph node excisional biopsy for malignancy suspicion, between January 2005 and December 2011, in the absence of any specific diagnosis. *Results:* Histological examination revealed a metastatic infiltration by an occult solid cancer in 16 cases (24%), ten of which were occult breast cancers. Histological patterns and molecular markers allowed in all cases of occult cancer a probable identification of the primary tumor site, while a definitive diagnosis was possible only in the 56.25% of cases (9/16). The prognosis of these patients was very poor with a five-year overall survival of 28%, and thus very similar to patients affected by Stage IV overt breast cancer. *Conclusions:* Among occult malignancies presenting with sole axillary lymph node metastasis, breast cancer remains the more probable primary cancer, but many other sites should be taken into consideration by negative breast imaging. Positron-emission tomography computed tomography (PET-CT) resulted helpful in the primary site detection, but has nonetheless a margin of failure. Occult breast cancers behave very similar to Stage IV overt breast cancers, and should be treated accordingly.

Key words: CUP syndrome; Cancer of unknown primary; Axillary lymph node metastasis; Occult tumor; Breast cancer.

Introduction

Cancer of unknown primary (CUP) is defined when cancer is found in one or more metastatic sites but the primary site is unknown. These cancers are characterized by early dissemination and unpredictable metastatic pattern coupled to dormancy or regression of the primary tumor and aggressive biologic behavior [1]. For its rarity, axillary node metastasis from CUP represents a diagnostic and therapeutic challenge being mostly, but not exclusively, the sole clinical symptom of non-palpable breast cancers.

Occult breast cancer accounts for less than 0.5% of all breast cancers, is located in the upper-outer quadrant in the 50% of cases and in the lower outer one in the 20% [2, 3]. Also lymphoma, melanoma, adenocarcinomas of the lung or gastrointestinal tract are known to metastasize to the axilla [1].

Determination of the occult primary tumor site is essential to lead the treatment and usually requires a multidisciplinary approach. Many molecular markers can be useful to investigate tumoral tissue properties in order to state its probable origin. In particular, estrogen receptor (ER) expression results a helpful marker in case of occult breast cancer [4, 5], but also gross cystic disease fluid protein 15 (GCDFP-15) and mammaglobin have been tested with the same target [6, 7].

The radiodiagnostic approach in metastasis from CUP with the target of finding the primary site and staging the patient consists of bilateral mammography, computed tomography (CT) of chest/abdomen/pelvis supplemented by additional imaging or endoscopic studies [1]. Although mammography is still considered the gold standard among breast diagnostic tools, its ability to detect occult breast tumors is disappointing [8], and despite the progresses of modern imaging techniques that enable to find and biopsy many early non-palpable breast lesions [9], there are many limiting factors such as radiologist's inexperience, small lesion size, and lesion localization [9–11]. Most of the imaging techniques, such as CT, magnetic resonance imaging (MRI), and positron-emission tomography (PET), had their sensitivity and specificity strongly limited by the lesion size [12].

Finally, it is important to remember that only the histopathological examination of the surgical specimen allows a definitive diagnosis. Unfortunately, if the tumor size is smaller than the pathological section interval the primary tumor escapes the histological detection and this may justify the fact that in approximately the 30% of cases undergoing mastectomy the tumor is not found [13–16].

The authors reviewed their cases with isolated axillary nodal swelling suspicious for malignancy and affected or not by isolated axillary node metastasis from CUP, focusing on their diagnostic and therapeutic management.

Materials and Methods

The authors collected retrospective data about all patients who underwent an axillary lymph node excisional biopsy for isolated axillary nodal swelling suspicious for malignancy, in their De-

Revised manuscript accepted for publication March 6, 2014

7847050 Canada Inc.
www.irog.net

Table 1. — *Population characteristics.*

Mean age at surgery (years)	53.75 (±19.33)
Female gender (prevalence)	63% (41/65)
Median follow up (months)	30 (16-49)
Histology	
Hematologic malignancy	58% (38/65)
Breast cancer	15% (10/65)
Ovarian cancer	3% (2/65)
Malignant melanoma	3% (2/65)
Other occult solid cancer	3% (2/65)
Benign/Reactive	17% (11/65)
Axilla side	
Bilateral	14% (9/65)
Right	51% (33/65)
Left	35% (23/65)

partment of Surgery, between January 2005 and December 2011, in the absence of any specific diagnosis. Exclusion criteria was the presence of multiple site localization of nodal swelling, in particular, they took into consideration patients age and gender, histological, and imaging findings.

Axillary lymph node biopsy was indicated in any case of positive (C5) or suspicious (C4) fine-needle aspiration cytology, and in case of strongly suspicious lymph node ultrasound characteristics (U5) even by the absence of cytology. All biopsies were performed under local anesthesia. No intraoperative frozen section histological examination was performed, due to our institutional policy, thus the specimens were evaluated in the authors' Department of Pathology with hematoxilin-eosin staining, and in case of metastasis also immunohistochemical markers were tested in order to define primary cancer origin. For the purpose of this study, the authors have defined CUP all solid cancers found by isolated axillary node metastasis even if the staging work up in a second time found a possible primary tumor.

By the presence of a metastatic axillary node, in both genders, mammography and breast ultrasound examination were always performed, because of the supposed high probability of the occult cancer to originate from the breast. In case of a negative finding, some selected cases underwent additional breast MRI. Chest-abdominal CT scan and total-body PET-CT scan were also performed in every case of occult non-breast cancer and was also performed in some cases of occult breast cancer when no primary site was discovered by the traditional breast imaging techniques or with a staging intent.

The majority of women were regularly screened for breast cancer. Women were screened before 2007 according to their initiative endorsed by general practitioner or specialist doctor and after 2007 according to a bi-annual mammographic and ultrasonographic breast cancer screening program [17]. The cases of breast CUP were compared with breast cancer cases of TNM Stages II, III, and IV occurred during the same period (2005-2011).

Data was analyzed by R (version 2.13.1), considering significant $p < 0.05$. Univariate analysis was performed by t-test in case of continuous variables and chi-square test or Fisher exact test in case of categorical variables. The overall survival (OS) expressed in months was calculated from the date of axillary intervention which corresponds with the diagnosis time. The five-year survival rates were also computed. The study was approved by the local ethics committee.

Results

During the considered period, 65 patients underwent axillary node excisional biopsy for malignancy suspicion. Mean patients age was 53.75 years (±19.33), and 63% of them were females. The right axilla was seized with illness in more than half cases (51%, 33/65), while 23 patients had a left axillary lymphoadenomegaly (35%), and in the remaining nine (14% of cases) there was a bilateral involvement of axillary lymph nodes (Table 1).

Histological examination was negative for neoplastic infiltration in 11 cases (17%, including reactive and granulomatous adenosis and a case angioleiomyoma), whereas it revealed a hematologic malignancy in 38 cases (59%) and a metastatic infiltration by an occult solid cancer in 16 cases (24%). In particular, there were ten cases of occult breast carcinoma, two occult malignant melanomas, two ovarian carcinomas, one bladder urothelial carcinoma, and one bronchus neuroendocrinous cancer. The diagnostic and therapeutic management of these 11 patients is summarized in Table 2.

Table 2. — *Patients with occult solid malignancies.*

Primary site	Gender	Age at op.	Side	Mx	Us	MRI	CT	PET-CT	Adjuvant therapies	Follow up	ER	PR	Mib1 (%)	Her-2
Breast	F	78	left	pos	pos	–	neg	pos	–	Died within 1 month	pos	pos	30	neg
Breast	F	77	bilat	neg	neg	neg	neg	neg	RT	Alive	pos	pos	–	pos
Breast	F	84	left	neg	neg	–	neg	pos	RT, CHT	Died after 4 years	pos	neg	10	neg
Breast	F	61	right	pos	pos	neg	neg	pos	RT	Alive	pos	pos	5	neg
Breast	F	46	left	neg	neg	–	neg	neg	RT, CHT	Alive	neg	neg	70	pos
Breast	F	61	right	neg	neg	neg	–	–	RT, CHT	Alive	pos	pos	–	pos
Breast	F	53	left	neg	neg	neg	–	–	RT	Alive	pos	neg	70	neg
Breast	F	59	right	neg	neg	neg	neg	–	RT, CHT	Died after 4 years	neg	neg	80	neg
Breast	F	48	left	neg	neg	neg	–	–	RT, CHT	Alive	pos	pos	25	neg
Breast	F	87	left	pos	pos	–	–	–	–	Alive	pos	pos	–	neg
Ovary	F	56	right	neg	neg	–	pos	pos	CHT	Died after 2 years	pos	neg	–	–
Ovary	F	50	right	neg	neg	–	pos	pos	CHT	Alive	pos	neg	–	–
Skin	M	71	right	neg	neg	–	neg	neg	–	Alive	neg	neg	5	–
Skin	M	59	left	neg	neg	–	neg	neg	–	Died after 2 years	neg	neg	50	–
Bladder	F	71	bilat	neg	neg	–	pos	pos	CHT	Died after 2 years	neg	neg	–	–
Bronchus	F	59	right	neg	neg	–	neg	pos	CHT	Alive	neg	neg	70	–

Table 3. — *Diagnostic tools used in the group of patients with occult solid malignancies.*

	Breast	Non breast
Mammography		
Not performed	0% (0/10)	0% (0/6)
Negative	70% (7/10)	100% (6/6)
Positive	30% (3/10)	0% (0/6)
Breast ultrasound		
Not performed	0% (0/10)	0% (0/6)
Negative	70% (7/10)	100% (6/6)
Positive	30% (3/10)	0% (0/6)
Breast magnetic resonance		
Not performed	40% (4/10)	100% (6/6)
Negative	60% (6/10)	0% (0/10)
Positive	0% (0/10)	0% (0/10)
Chest-abdominal CT scan		
Not performed	40% (4/10)	0% (0/6)
Negative	60% (6/10)	50% (3/6)
Positive	0% (0/10)	50% (3/6)
Total-body PET-CT scan		
Not performed	50% (5/10)	0% (0/6)
Negative	20% (2/10)	33% (2/6)
Positive	30% (3/10)	67% (4/6)

CUP syndrome represented the 3% of all patients receiving an axillary lymphoadenectomy in the study period, and breast cancer axillary metastasis from an occult primary site were 0.48% of all breast cancers operated in the same period. Histological patterns and molecular markers allowed in all cases of occult cancer a probable identification of the primary tumor site, while a certain diagnosis on the primary cancer specimen was possible only in the 56% of cases (9/16). The authors found ER positivity to have, respectively, a sensitivity and a specificity of 80% (CI.95 49-94%) and 67% (CI.95 30-90%) for identification of a CUP as originating from a breast cancer primary. Furthermore, they found progesterone receptor (PR) positivity to have a sensitivity and a specificity of 60% (CI.95 31-83%) and 100% (CI.95 61-100%).

Taking into consideration only occult breast cancers, mammography and breast ultrasound examination showed always according findings, but succeeded in detecting the occult primary site only in three women with breast cancer (30%, 3/10) (Table 3). Moreover, 80% (8/10) of women affected by breast cancer had a previous regular screening and the last screening examination was performed at a median of 12 months (9-16) before finding CUP. A fourth case of occult breast cancer was detected only by PET-CT scan, while additional breast MRI was not routinely performed, and in any case never detected the occult breast primary site. Finally, a fifth case was found out only by the histological examination of the breast surgical specimen, and in only one of 103 histological sections.

The 80% of women with occult breast cancer underwent quadrantectomy for a suspected mass, but in only three cases it resulted to be a primary tumor. Two patients underwent mastectomy and in both cases the primary tumor was successfully found. Five patients underwent further ipsilateral breast irradiation and chemotherapy (50%), three underwent only adjuvant radiation therapy (30%), and the two remaining cases did not receive any adjuvant therapy (20%). In addition, five patients also received lymph node radiation therapy.

Considering together patients with occult solid breast and non-breast cancers, chest-abdominal CT scan and total-body PET-CT scan found the occult primary site in respectively, the 25% (3/12) and 64% (7/11) of cases.

Comparing patients with an hematologic malignancy and those with an occult solid cancer, mean age of these last results significantly higher (63.75 *vs* 55.50) (Table 4). Moreover, considering only patients who died for cancer during the follow up, they are significantly older in the group of patients with an occult solid tumor ($p = 0.239$). No significant difference was observed according to gender and the axilla side.

The OS at two years for patients with an axillary metastasis from an occult solid primary tumor was 70% (CI.95 50-100%), and thus lower ($p = 0.192$) if compared to that of patients affected by hematologic malignancies who developed an axillary isolated lymphoadenopathy (79%, CI.95 67-94%). Furthermore, the 70% (CI.95 55%-90%) of patients affected by hematologic malignancies resulted alive at five years, whereas the five-year OS in patients with an occult solid primary tumor diagnosis resulted in only 28% (CI.95 9-87%) (Figure 1A).

Table 4. — *Comparison among patients with negative axillary findings, axillary manifestation of a hematologic malignancy, and axillary metastasis from an occult solid primary malignancy.*

	Hematologic malignancy	Occult solid cancer	Benign/Reactive	*p*
Mean age at surgery (ys)	55.5 (±18.33)	63.75 (±12.77)	33.18 (±16.35)	<0.05
Median follow up (months)	28 (15-48)	30 (14-44)	40 (24-62)	0.310
Mean age at surgery (pts dead for cancer)	59 (±22.43)	69.14 (±11.13)		0.239
Median follow up (pts dead for cancer)	16 (7-26)	21 (17-45)		0.282
Female gender	55% (21/38)	88% (14/16)	55% (6/11)	0.066
Axilla side				
Bilateral	16% (6/38)	12% (2/16)	9% (1/11)	0.838
Right	50% (19/38)	44% (7/16)	64% (7/11)	0.591
Left	34% (13/38)	44% (7/16)	27% (3/11)	0.661

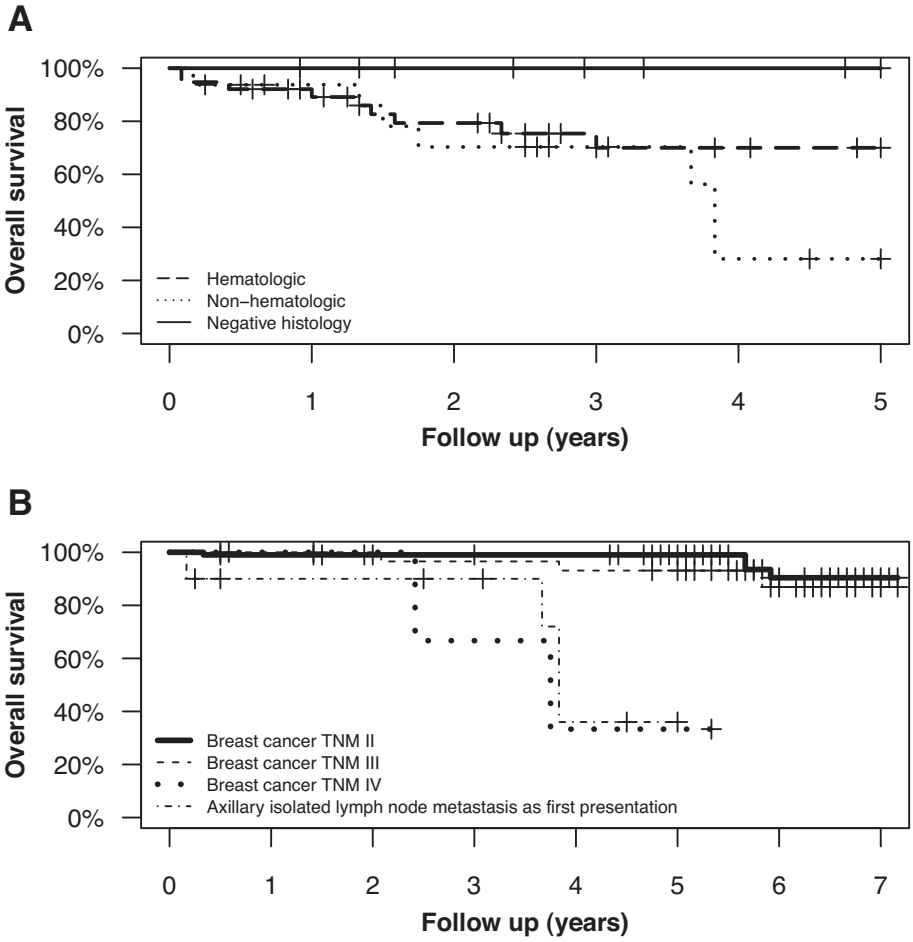

Figure 1. — A) Overall survival of patients with negative axillary findings, axillary manifestation of a hematologic malignancy, and axillary metastasis from an occult solid primary malignancy. B) Breast cancer TNM stage, breast cancer found by axillary isolated lymph node metastasis, and survival.

Table 5. — *Characteristics of breast cancer and breast cancer found by axillary isolated lymph node metastasis.*

	TNM II	TNM III	TNM IV	Axillary isolated lymph node metastasis as first presentation	*p*
Woman age (years)	61.53 (±12.99)	59.8 (±14.56)	64 (±12.12)	65.4 (±14.98)	0.610
Histological type					
Ductal invasive carcinoma	82% (193/235)	85% (47/55)	100% (3/3)	90% (9/10)	0.723
Lobular invasive carcinoma	13% (30/235)	13% (7/55)	0% (0/3)	0% (0/10)	0.596
Ductal and lobular invasive carcinoma	3% (6/235)	2% (1/55)	0% (0/3)	0% (0/10)	0.934
Other invasive carcinoma	3% (6/235)	0% (0/55)	0% (0/3)	0% (0/10)	0.621
Ductal in situ carcinoma	0% (0/235)	0% (0/55)	0% (0/3)	10% (1/10)	<0.05
ER positivity	89% (196/221)	79% (41/52)	67% (2/3)	80% (8/10)	0.183
PgR positivity	77% (171/222)	71% (37/52)	33% (1/3)	60% (6/10)	0.167
Ki-67/Mib-1 >30	21% (43/207)	39% (20/51)	33% (1/3)	43% (3/7)	<0.05
Her-2 positivity	7% (16/217)	18% (9/51)	67% (2/3)	30% (3/10)	<0.05

Comparing patients with breast CUP and those with overt breast cancers at the same stage, the majority of histological types were ductal invasive carcinoma in both cases (Table 5). Furthermore, the authors found hormonal status to be similar to TNM II and III, while Her-2 positivity was significantly higher in CUP compared to TNM II breast cancer ($p < 0.05$), and Mib-1 was not significantly higher in CUP compared to TNM II. TNM stage at diagnosis of breast CUP was in 50% of cases TNM II and in 50% TNM III. In Figure 1B the authors found CUP to have a significantly lower OS than TNM II and III of other breast cancers. Moreover, the survival pattern of CUP was similar to TNM Stage IV of other breast cancers (Figure 1B).

Discussion

Among 65 patients operated for a suspicious axillary metastasis from an occult primary cancer, 16 (24%) presented a metastatic infiltration by an occult solid cancer: ten breast cancers, two malignant melanomas, two ovarian cancers, one bladder urothelial cancer, and one bronchus neuroendocrinous cancer. Histological patterns and molecular markers allowed in all cases of occult cancer a probable identification of the primary tumor site, while certain diagnosis was possible only in the 56% of cases (9/16). The prognosis of these patients was very poor with an OS at five years of 28%.

According to the literature, isolated axillary nodal mass represented the sole presentation of metastatic cancer in about 0.3-1% of cases [2, 7, 18]. If the authors consider, for example, the 2,097 women operated for breast cancer in their Department of General Surgery in the study period, occult breast carcinoma presenting with sole axillary node metastasis represented the 0.48% of cases (about one case every 200).

Even by the presence of an axillary specimen strongly suggestive for a breast origin, and independently from imaging findings, the histological examination succeeded in finding the primary localization of the occult breast carcinoma in only five cases (50%), and in one of them only in one section to 103. Actually, many studies demonstrate that if the tumor size is smaller than the pathological sections interval, primary tumor usually escapes detection by histology [2, 6, 7, 13–16]. Hence this is regarding small tumors that have already metastasized axilla and axillary nodal status in breast cancer is one of the most important prognostic factors for patient survival [19].

Although the breast cancer is the most common cancer among women in Western countries [20] and represents the most frequent site of occult primary tumor in case of isolated axillary node metastasis, many cancers have the potential to spread to the axilla, such as lung, thyroid, gastrointestinal, and gynecological carcinomas [1]. Therefore, despite the rarity of this condition, it is important to exclude a primary tumor other than breast.

The literature reports some cases of ovarian and peritoneal serous carcinoma metastatic to the breast and/or to the axillary lymph nodes [21–27], and sometimes very difficult to diagnose while mimicking inflammatory breast cancer [28–30]. The authors also reported one case of occult ovarian cancer presenting with an axillary mass, accompanied by a suspicious lymphangitis carcinomatosa of the breast.

Also malignant melanoma has a recognized tendency to early lymph-mediated distant dissemination [31], which seems to be more aggressive from the axilla than from the groin [32, 33]. In some cases, the absence of a visible primary site may be explained by a progressive physiological depigmentation during the natural history of melanoma [34], as well as by its mis-recognition and involuntary previous excision.

The most likely mechanism for axillary nodes involvement by lung cancer is intercostal lymphatics pathway spread from mediastinal lymph node metastasis [35]. Instead, it results more difficult to explain the lymphatic dissemination to the axilla in case of solid intra-abdominal malignancies.

Among women with occult breast cancer, mammography and breast ultrasound examination resulted false negative in the 70% of cases (7/10). Actually, although mammography represents the current gold standard of breast imaging, and together with breast ultrasound examination has a very high accuracy for lesions of at least five mm, in the present group of patients, its ability in detecting breast occult tumor remains disappointing, mainly depending on tumor size [8], and in some cases requires many years of regular follow up in order to identify the primary tumor location [36].

Although some experiences in the literature demonstrate that MRI successfully detected occult breast cancers in about 70-83% of cases [37, 38], in other studies breast MRI resulted very weak in the detection of an occult breast primary tumor site [39], and in the present population it could not find any primary tumor site in all the cases where it was performed.

According to other recent studies, PET-CT results to be the more helpful imaging technique in identifying the primary tumor [40–43], but its diagnostic performance should be maximized by its appropriate use and interpretation [44]. Moreover, a recent meta-analysis assessed FDG-PET/CT sensitivity and specificity to be respectively, 84% (CI.95 77-88%) and 84% (CI.95 78-89%) [45]. In the present population, it succeeded in finding the primary tumor in the 64% of cases, with a diagnostic gain of the 12% (2/16). In fact, it detected one more case among occult breast cancers and one more case among non-breast occult cancers (the primary lung cancer site). Moreover, it confirmed CT finding in the patient affected by ovarian cancer, but was useless in both cases of malignant melanoma, the primary localization of which remained unknown.

In accordance with the literature, the OS of patients affected by hematologic malignancies at two and five years was respectively, 79% and 70% [46], showing a stabilization of the curve after the third follow up year. On the other hand, the prognosis of patients with an occult solid cancer was very poor, with an OS of 70% at two years and 28% at five years from the diagnosis, and a median survival of 20 months (14-44). In the current literature, CUP represents the seventh to eighth most frequent type of cancer, but the fourth most common cause of cancer-related death; it is characterized by a very aggressive natural history, early dissemination, and metastatic pattern unpredictability [47–50], with a median survival of 16 months with 10% five-year survival [49, 50].

Treatment and prognosis of occult cancer mainly depends on its histological type and clinical pathological stage [18, 51], remaining particularly controversial in case of occult breast location, because outcome are not significantly different between radical mastectomy and conservative

treatments such as quadrantectomy and radiation [18, 27, 52–58]. In the present population, all women with a suspicion of occult breast cancer were operated in their breasts: eight received a breast-conserving intervention, while two had a mastectomy performed. Then, five patients underwent further ipsilateral breast irradiation and chemotherapy, three underwent only adjuvant breast radiation therapy, five received also additional lymph node radiation therapy as appropriate, and two underwent a watchful policy (one for personal choice and the second because of her advanced age and bad general conditions).

Also in these cases of breast cancer presenting as isolated axillary swelling, biological characteristics represented an important predictive factor for axillary metastasis [59]. In fact, cancers that presented as isolated axillary swelling had high proliferation index and high prevalence of Her2 positivity. Generally the more axillary lymph node involvement is associated with high T [60] in these cases small non-palpable breast cancers or unknown primary breast cancers were so aggressive to give overt axillary metastasis as first sign.

Finally, breast cancer axillary metastasis from unknown primary site resulted associated in the literature with similar presentation, biology, and outcome to node-positive overt breast cancer, and should be treated accordingly [1]. Nonetheless in the authors' opinion, although a recent review compares breast CUP with Stage II overt breast cancer [61], occult breast cancers with axillary metastasis behave more similarly to stage IV overt breast cancers than to stage II or III.

Conclusions

In case of an occult primary tumor presenting with a sole axillary node metastasis, breast cancer should always be excluded, before taking into consideration other possible primary malignancies. In this perspective, immunohistochemistry could be helpful with a detailed portrait of the cancer molecular expression, in order to detect the occult primary site and identify some favorable therapeutic targets. In addition, the modern imaging diagnostic tools may support primary site suspicion, although with an insufficient accuracy. PET-CT seems to be the more helpful imaging technique in this particular group of patients, but has however a margin of failure.

In the authors' opinion, focusing on occult primary breast cancers, there may be a particular type of cancer with an important lymphatic tropism, and a very poor prognosis, which do not depend on the primary tumor growth. Moreover, along with the very low imaging detection rate of the primary breast cancer, and its even lower detection rate with histological examination of the specimen, even by radical breast surgery, it is very discouraging that many of the women included in this report were regularly undergoing the suggested screening for breast cancer and in this group of patients was completely helpless.

References

[1] Pentheroudakis G., Lazaridis G., Pavlidis N.: "Axillary nodal metastases from carcinoma of unknown primary (CUPAx): a systematic review of published evidence". *Breast Cancer Res. Treat.*, 2010, *119*, 1.

[2] Kyokane T., Akashi-Tanaka S., Matsui T., Fukutomi T.: "Clinicopathological characteristics of non-palpable breast cancer presenting as axillary mass". *Breast Cancer*, 1995, *2*, 105.

[3] Patel J., Nemoto T., Rosner D., Dao T.L., Pickren J.W.: "Axillary lymph node metastasis from an occult breast cancer". *Cancer*, 1981, *47*, 2923.

[4] Yirmibeolu E., Tekin E., Memi L., Yamaç D., Taneri F., Erkal H.S.: "A patient with occult breast cancer presenting with an axillary lymph node metastasis and a synchronous contralateral breast cancer". *Breast*, 2005, *14*, 157.

[5] Kaufmann O., Deidesheimer T., Muehlenberg M., Deicke P., Dietel M.: "Immunohistochemical differentiation of metastatic breast carcinomas from metastatic adenocarcinomas of other common primary sites". *Histopathology*, 1996, *29*, 233.

[6] Yamaguchi H., Ishikawa M., Hatanaka K., Uekusa T., Ishimaru M., Nagawa H.: "Occult breast cancer presenting as axillary metastases". *Breast*, 2006, *15*, 259.

[7] Matsuoka K., Ohsumi S., Takashima S., Saeki T., Aogi K., Mandai K.: "Occult breast carcinoma presenting with axillary lymph node metastases: follow-up of eleven patients". *Breast Cancer*, 2003, *10*, 330.

[8] Leibman A.J., Kossoff M.B.: "Mammography in women with axillary lymphadenopathy and normal breasts on physical examination: value in detecting occult breast carcinoma". *AJR Am. J. Roentgenol.*, 1992, *159*, 493.

[9] Bernardi S., Bertozzi S., Londero A.P., Gentile G., Giacomuzzi F., Carbone A.: "Incidence and risk factors of the intraoperative localization failure of nonpalpable breast lesions by radio-guided occult lesion localization: a retrospective analysis of 579 cases". *World J. Surg.*, 2012, *36*, 1915.

[10] Bernardi S., Bertozzi S., Londero A.P.: "Incidence and risk factors of the intraoperative localization failure of nonpalpable breast lesions by radio-guided occult lesion localization: a retrospective analysis of 579 cases: reply". *World J. Surg.*, 2013, *37*, 478.

[11] Postma E.L., Verkooijen H.M., van den Bosch M.A.A.J., van Hillegersberg R.: "Incidence and risk factors of the intraoperative localization failure of nonpalpable breast lesions by radio-guided occult lesion localization: a retrospective analysis of 579 cases: reply". *World J. Surg.*, 2013, *37*, 476.

[12] Pasqual E., Bertozzi S., Bacchetti S., Londero A.: "Effektive Therapie bei peritonealen Neoplasmen mit niedrigem Peritoneal Cancer Index: Die Schwierigkeit der Diagnosesicherung". *Interdisziplinäre Onkologie*, 2012, *4*, 26.

[13] Tamiolakis D., Antoniou C.: "Axillary nodal metastasis of occult breast primary cancer". *Chirurgia (Bucur).*, 2008, *103*, 467.

[14] Lloyd M.S., Nash A.G.: "Occult breast cancer". *Ann. R. Coll. Surg. Engl.*, 2001, *83*, 420.

[15] Abe H., Naitoh H., Umeda T., Shiomi H., Tani T., Kodama M., *et al.*: "Occult breast cancer presenting axillary nodal metastasis: a case report". *Jpn. J. Clin. Oncol.*, 2000, *30*, 185.

[16] Ashikari R., Rosen P.P., Urban J.A., Senoo T.: "Breast cancer presenting as an axillary mass". *Ann. Surg.*, 1976, *183*, 415.

[17] Driul L., Bernardi S., Bertozzi S., Schiavon M., Londero A.P., Petri R.: "New surgical trends in breast cancer treatment: conservative interventions and oncoplastic breast surgery". Minerva Ginecol., 2013, *65*, 289.

[18] Baron P.L., Moore M.P., Kinne D.W., Candela F.C., Osborne M.P., Petrek J.A.: "Occult breast cancer presenting with axillary metastases. Updated management". *Arch. Surg.*, 1990, *125*, 210.

[19] Bernardi S., Bertozzi S., Londero A.P., Angione V., Petri R., Giacomuzzi F.: "Prevalence and risk factors of intraoperative identification failure of sentinel lymph nodes in patients affected by breast cancer". *Nucl. Med. Commun.*, 2013, *34*, 664.

[20] Bernardi S., Londero A.P., Bertozzi S., Driul L., Marchesoni D., Petri R.: "Breast-feeding and benign breast disease". *J. Obstet. Gynaecol.*, 2012, *32*, 58.

[21] Wolff E.F., Martel M., Gwin K., Lannin D.: "Synchronous primary breast and ovarian cancer with ovarian cancer metastases to a breast sentinel lymph node". *Breast J.*, 2009, *15*, 203.
[22] Recine M.A., Deavers M.T., Middleton L.P., Silva E.G., Malpica A.: "Serous carcinoma of the ovary and peritoneum with metastases to the breast and axillary lymph nodes: a potential pitfall". *Am. J. Surg. Pathol.*, 2004, *28*, 1646.
[23] Kayikçiolu F., Boran N., Ayhan A., Güler N.: "Inflammatory breast metastases of ovarian cancer: a case report". *Gynecol. Oncol.*, 2001, *83*, 613.
[24] Ozsaran A.A., Dikmen Y., Terek M.C., Ulukus M., Ozdemir N., Orgüc S., *et al.*: "Bilateral metastatic carcinoma of the breast from primary ovarian cancer". *Arch. Gynecol. Obstet.*, 2000, *264*, 166.
[25] Manini C., Pietribiasi F., Sapino A., Donadio S.: "Serous cystadenocarcinoma of the ovary with simultaneous breast metastases. Description of a case". *Pathologica*, 1998, *90*, 152.
[26] Yamasaki H., Saw D., Zdanowitz J., Faltz L.L.: "Ovarian carcinoma metastasis to the breast case report and review of the literature". *Am. J. Surg. Pathol.*, 1993, *17*, 193.
[27] Ibach J.R.: "Carcinoma of the ovary metastatic to breast. a case report and review of the literature". *Arch. Surg.*, 1964, *88*, 410.
[28] Khalifeh I., Deavers M.T., Cristofanilli M., Coleman R.L., Malpica A., Gilcrease M.Z.: "Primary peritoneal serous carcinoma presenting as inflammatory breast cancer". *Breast J.*, 2009, *15*, 176.
[29] Ozgüroğlu M., Ersavaşti G., Ilvan S., Hatemi G., Demir G., Demirelli F.H.: "Bilateral inflammatory breast metastases of epithelial ovarian cancer". *Am. J. Clin. Oncol.*, 1999, *22*, 408.
[30] Krishnan E.U., Phillips A.K., Randell A., Taylor B., Garg S.K.: "Bilateral metastatic inflammatory carcinoma in the breast from primary ovarian cancer". *Obstet. Gynecol.*, 1980, *55*, 94S.
[31] Shenoy B.V., Fort L., Benjamin S.P.: "Malignant melanoma primary in lymph node. The case of the missing link". *Am. J. Surg. Pathol.*, 1987, *11*, 140.
[32] Kobayashi G., Cobb C.: "A case of amelanotic spindle-cell melanoma presenting as metastases to breast and axillary lymph node: diagnosis by FNA cytology". *Diagn. Cytopathol.*, 2000, *22*, 246.
[33] Karakousis C.P., Balch C.M., Bartolucci A., Driscoll D.L.: "Is the capacity for lymph node-mediated distant dissemination the same for all nodal groups in malignant melanoma?" *Melanoma Res.,* 1998, *8*, 419.
[34] Malafronte P., Sorrells T.: "Lymph node melanosis in a patient with metastatic melanoma of unknown primary". *Arch. Pathol. Lab. Med.*, 2009, *133*, 1332.
[35] Satoh H., Ishikawa H., Kagohashi K., Kurishima K., Sekizawa K.: "Axillary lymph node metastasis in lung cancer". *Med. Oncol.,* 2009, *26*, 147.
[36] Frattaroli F.M., Carrara A., Conte A.M., Pappalardo G.: "Axillary metastasis as first symptom of occult breast cancer: a case report". *Tumori*, 2002, *88*, 532.
[37] Ko E.Y., Han B.K., Shin J.H., Kang S.S.: "Breast MRI for evaluating patients with metastatic axillary lymph node and initially negative mammography and sonography". *Korean J. Radiol.*, 2007, *8*, 382.
[38] Orel S.G., Weinstein S.P., Schnall M.D., Reynolds C.A., Schuchter L.M., Fraker D.L., *et al.*: "Breast MR imaging in patients with axillary node metastases and unknown primary malignancy". *Radiology*, 1999, *212*, 543.
[39] Buchanan C.L., Morris E.A., Dorn P.L., Borgen P.I., Zee K.J.V.: "Utility of breast magnetic resonance imaging in patients with occult primary breast cancer". *Ann. Surg. Oncol.*, 2005, *12*, 1045.
[40] Stella G.M., Senetta R., Cassenti A., Ronco M., Cassoni P.: "Cancers of unknown primary origin: current perspectives and future therapeutic strategies". *J. Transl. Med.*, 2012, *10*, 12.
[41] Beckers M.M.J., Verzijlbergen J.F., van Buul M.M.C., Prins M.H., Biesma D.H.: "The potential role of positron emission tomography in the detection of occult cancer in 25 patients with venous thromboembolism". *Ann. Oncol.*, 2008, *19*, 1203.
[42] Kwee T.C., Basu S., Alavi A.: "PET and PET/CT for unknown primary tumors". *Methods Mol. Biol.*, 2011, *727*, 317.
[43] Takabatake D., Taira N., Aogi K., Ohsumi S., Takashima S., Inoue T., *et al.*: "Two cases of occult breast cancer in which PET-CT was helpful in identifying primary tumors". *Breast Cancer*, 2008, *15*, 181.
[44] Kwee T.C., Basu S., Cheng G., Alavi A.: "FDG PET/CT in carcinoma of unknown primary". *Eur. J. Nucl. Med. Mol. Imaging*, 2010, *37*, 635.
[45] Kwee T.C., Kwee R.M.: "Combined FDG-PET/CT for the detection of unknown primary tumors: systematic review and meta-analysis". *Eur. Radiol.*, 2009, *19*, 731.
[46] American Cancer Society: "Cancer Facts & Figures 2010". Available at: http://www.cancer.org/acs/groups/content/@nho/documents/document/acspc-024113.pdf
[47] Thöm I., Rogers C., Andritzky B., Witzel I., Schuch G., Hossfeld D.K., *et al.*: "Single-center management of 136 patients with cancer of unknown primary site (CUP syndrome) over a period of 10 years". *Onkologie*, 2009, *32*, 741.
[48] Pavlidis N., Pentheroudakis G.: "Cancer of unknown primary site: 20 questions to be answered". *Ann. Oncol.*, 2010, *21*, vii303.
[49] Pavlidis N., Fizazi K.: "Carcinoma of unknown primary (CUP)". *Crit. Rev. Oncol. Hematol.*, 2009, *69*, 271.
[50] Pavlidis N., Briasoulis E., Hainsworth J., Greco F.A.: "Diagnostic and therapeutic management of cancer of an unknown primary". *Eur. J. Cancer*, 2003, *39*, 1990.
[51] Cisneros-Reig I., Sastre M.L., Sánchez M.A., Guinot J.N., Giner R.L.G., Salvador-Sanchis J.L., *et al.*: "Bilateral occult breast carcinoma: a second primary tumour or contralateral tumour metastasis?" *Eur. J. Surg.*, 2001, *167*, 312.
[52] Masinghe S.P., Faluyi O.O., Kerr G.R., Kunkler I.H.: "Breast radiotherapy for occult breast cancer with axillary nodal metastases–does it reduce the local recurrence rate and increase overall survival?" *Clin. Oncol. (R. Coll. Radiol.)*, 2011, *23*, 95.
[53] Yang T.I.J., Yang Q., Haffty B.G., Moran M.S.: "Prognosis for mammographically occult, early-stage breast cancer patients treated with breast-conservation therapy". *Int. J. Radiat. Oncol. Biol. Phys.*, 2010, *76*, 79.
[54] Barton S.R., Smith I.E., Kirby A.M., Ashley S., Walsh G., Parton M.: "The role of ipsilateral breast radiotherapy in management of occult primary breast cancer presenting as axillary lymphadenopathy". *Eur. J. Cancer*, 2011, *47*, 2099.
[55] Varadarajan R., Edge S.B., Yu J., Watroba N., Janarthanan B.R.: "Prognosis of occult breast carcinoma presenting as isolated axillary nodal metastasis". *Oncology*, 2006, *71*, 456.
[56] Brill K.L., Brenin D.R.: "Occult breast cancer and axillary mass". *Curr. Treat. Options Oncol.*, 2001, *2*, 149.
[57] Vlastos G., Jean M.E., Mirza A.N., Mirza N.Q., Kuerer H.M., Ames F.C., *et al.*: "Feasibility of breast preservation in the treatment of occult primary carcinoma presenting with axillary metastases". *Ann. Surg. Oncol.*, 2001, *8*, 425.
[58] Ellerbroek N., Holmes F., Singletary E., Evans H., Oswald M., McNeese M.: "Treatment of patients with isolated axillary nodal metastases from an occult primary carcinoma consistent with breast origin". *Cancer*, 1990, *66*, 1461.
[59] Bernardi S., Bertozzi S., Londero A.P., Giacomuzzi F., Angione V., Dri C., et al.: "Nine years of experience with the sentinel lymph node biopsy in a single Italian center: a retrospective analysis of 1,050 cases". *World J. Surg.*, 2012, *36*, 714.
[60] Bertozzi S., Londero A.P., Giacomuzzi F., Angione V., Carbone A., Petri R., Bernardi S.: "Applicability of two different validated models to predict axillary non-sentinel lymph node status by sentinel node biopsy in a single Italian center". *Breast Cancer*, 2013, Jul 6. [Epub ahead of print].
[61] Pavlidis N., Pentheroudakis G.: "Cancer of unknown primary site". *Lancet*, 2012, *379*, 1428.

Address reprint requests to:
S. BERTOZZI, M.D.
Department of Surgery,
AOU "SM della Misericordia",
Piazzale SM della Misericordia, 15
33100 Udine (Italy)
e-mail: sere_d.estate@libero.it