EJGO European Journal of Gynaecological Oncology

# The differences of phyllodes and acoustic attenuation in breast lesions diagnosed with Breast Imaging-Reporting and Data System for Ultrasonography (BI-RADS-US) category 4C

**Y.Y. Li[1], C. Liu[1], J. Geng[1], J.G. Li[2], F. Jin[2], X.M. Wang[1]**

[1] *Department of Ultrasound Diagnosis, the First Affiliated Hospital of China Medical University, Shenyang*
[2] *Department of Breast Surgery, the First Affiliated Hospital of China Medical University, Shenyang (China)*

**Summary**

*Objective:* This study aimed to discuss the differences of malignant findings in breast lesions diagnosed with Breast Imaging-Reporting and Data System for Ultrasonography (BI-RADS-US) category 4C to determine which malignant findings are more important. *Materials and Methods:* A total of 159 cases of breast lesions diagnosed with BI-RADS-US category 4C were analyzed retrospectively. All patients got pathological results (81 cases of benign; 78 cases of breast cancer). Two doctors scanned and diagnosed the patients, with another doctor recording ultrasonographic findings retrospectively. The differences were compared by means of the Chi-square ($\chi^2$) test. *Results:* Phyllodes and acoustic attenuation had statistical differences in the comparison of breast lesions ($p < 0.05$). Irregular shape, indistinct boundary, poorly-defined margin, penetrating or tortuous surrounding vessels, RI $\geq$ 0.7, and microcalcification had no statistical differences in the comparison of benign and malignant breast lesions. *Conclusions:* Phyllodes and acoustic attenuation are the more important malignant ultrasonographic findings of breast cancer. The malignant ultrasonographic findings are not unique for breast cancer.

*Key words:* Malignant ultrasonographic findings of breast; BI-RADS-US; Differential diagnosis of breast lesions.

## Introduction

Breast cancer is one of the common malignant tumors in the female. The incidence of breast cancer is the third in the malignances [1]. At present, the diagnosis of breast cancer is mainly dependent on mammography in America and Asia [2, 3]. However, with the improvement of ultrasonic resolution and the development and application of new ultrasonic technology, breast ultrasonography has gained widespread acceptance as a diagnostic tool for the evaluation of human breast disorders [4].

As reported and found by the present authors' daily work, some of the breast lesions diagnosed with Breast Imaging-Reporting and Data System for Ultrasonography (BI-RADS-US) category 3 were diagnosed as malignant by pathology after biopsy or surgery [5, 6] and some of the breast lesions diagnosed with BI-RADS-US category 4C were diagnosed as benign by pathology after surgery [7, 8]. Sonographers make a diagnosis promptly according to the ultrasonographic findings of breast, but it is not clear which one is more important when the decision is made.

The present authors will discuss the differences of ultrasonographic findings in breast lesions diagnosed with BI-RADS-US category 4C in this work to determine which malignant findings are more important.

## Materials and Methods

*Patients*

All patients in inpatient departments underwent surgery (January 2009- December 2009), including 81 cases of benign breast lesions (age range 18-79 years, mean 47.23 ± 10.80; 47 cases of adenosis, 21 cases of intraductal papilloma; 13 cases of fibroadenoma), and 78 cases of malignant breast lesions randomly selected (age range 26-73, mean 47.5 ± 8.93 years). All female patients were examined by department of ultrasonic diagnosis and diagnosed with BI-RADS-US category 4C. The American College of Radiology BI-RADS-US lexicon (ACR BI-RADS-US) was used. This study was conducted in accordance with the declaration of Helsinki and with approval from the Ethics Committee of the First Affiliated Hospital of China Medical University. Written informed consent was obtained from all participants.

*Sonographic equipment and the scanning method*

A color ultrasound diagnostic system was used with the linear probe at the frequency of 7-14 MHz.

All patients took supine position. Two arms were placed on both sides of the head; bilateral breast and axillaries were fully exposed. Two doctors (with more than ten years of experience) scanned and diagnosed the patients, with another doctor (more than ten years experience) recorded the ultrasonographic findings retrospectively.

*Malignant findings in BI-RADS-US category 4C*

The authors defined malignant findings in BI-RADS-US category 4C: A-Irregular shape, B-indistinct boundary, C-phyllodes,

Revised manuscript accepted for publication March 5, 2014



7847050 Canada Inc.
www.irog.net

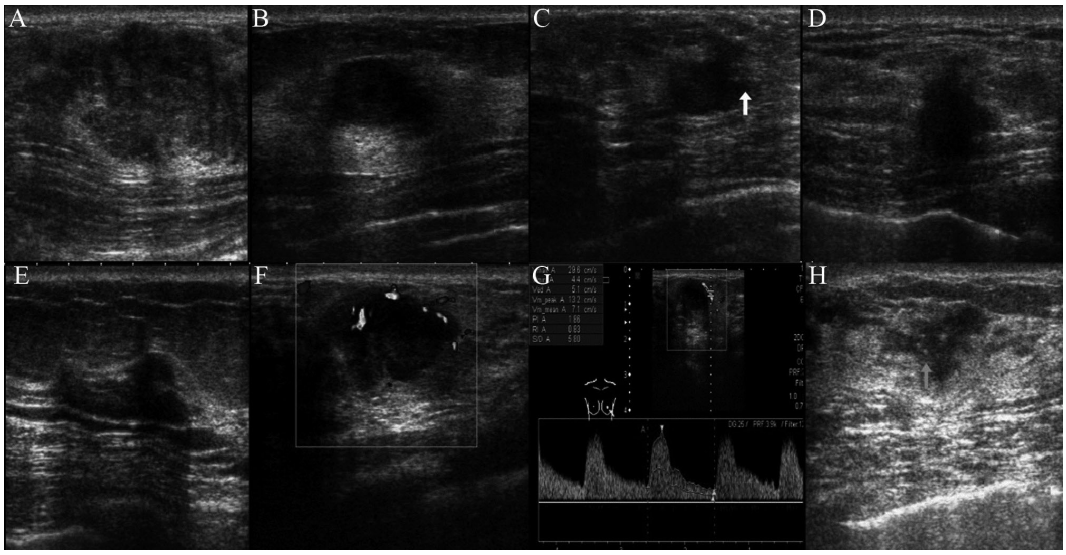


Figure 1. — Malignant findings in benign breast lesions diagnosed BI-RADS-US category 4C: A-Irregular shape, B-indistinct boundary, C-phyllodes, D-poorly-defined margin, E-acoustic attenuation, F-penetrating or tortuous surrounding vessels, G-RI ≥ 0.7, H-microcalcification.

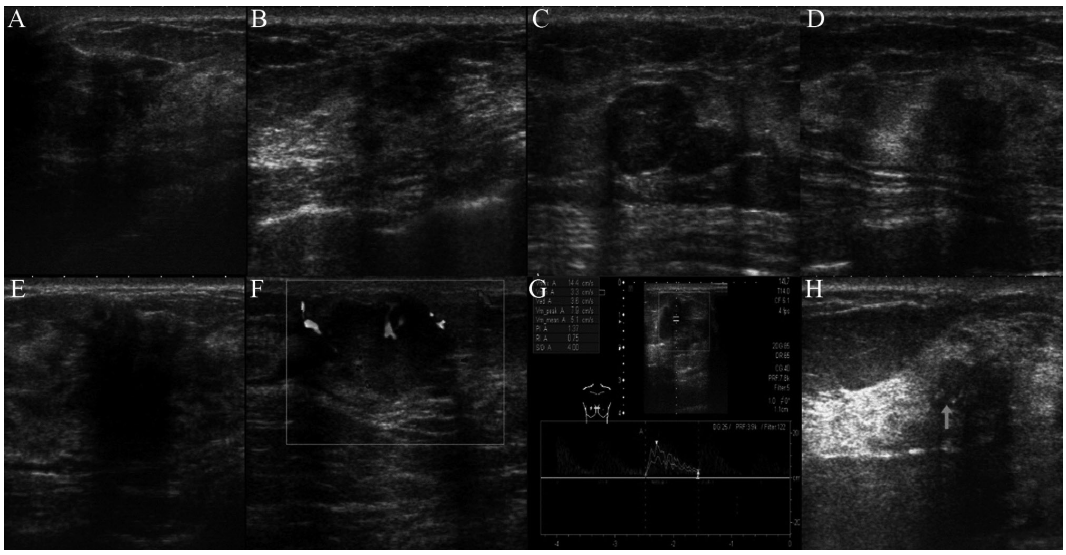


Figure 2. — Malignant findings in malignant breast lesions diagnosed BI-RADS-US category 4C: A-Irregular shape, B-indistinct boundary, C-phyllodes, D-poorly-defined margin, E-acoustic attenuation, F-penetrating or tortuous surrounding vessels, G-RI ≥ 0.7, H-microcalcification.

D-poorly-defined margin, E-acoustic attenuation, F-penetrating or tortuous surrounding vessels, G-RI ≥ 0.7, H-microcalcification.

*Statistical analysis*

Statistical analysis was performed by using SPSS 19.0 software. The differences in the study group and the control group were compared by means of the Chi-square x (Chi-square) test. The results were considered statistically significant whenever $p$ was < 0.05.

## Results

*Ultrasonographic findings in breast lesions diagnosed with BI-RADS-US category 4C*

The ultrasonographic manifestations of malignant ultrasonographic findings in benign and malignant breast lesions diagnosed with BI-RADS-US category 4C are shown in Figures 1 and 2.

*The differences of malignant findings in breast lesions diagnosed with BI-RADS-US category 4C*

Phyllodes and acoustic attenuation had statistical differences in the comparison of breast lesions ($p < 0.05$), irregular shape, indistinct boundary, poorly-defined margin, penetrating or tortuous surrounding vessels, RI ≥ 0.7, and microcalcification had no statistical differences in the comparison of benign and malignant breast lesions ($p > 0.05$, Table 1).

## Discussion

The pathological morphologies are the basis of ultrasonographic manifestations. A total of 159 cases in BI-RADS-US category 4C were analyzed and the differences of ultrasonographic findings in breast lesions were discussed in this paper. Interestingly the present results found

Table 1. — *The differences of malignant findings in breast lesions diagnosed BI-RADS-US category 4C.*

| Ultrasonographic findings Cases (159) | Benign (n=81) | Malignant (n=78) | $\chi^2$ | *p* |
|---|---|---|---|---|
| Irregular shape | 62 | 62 | | |
| Regular shape | 19 | 16 | 0.2006 | >0.05 |
| Indistinct boundary | 40 | 44 | | |
| Distinct boundary | 41 | 34 | 0.7875 | >0.05 |
| Phyllodes | 35 | 17 | | |
| Non-phyllodes | 46 | 61 | 8.2799 | <0.05 |
| Poorly-defined margin | 9 | 18 | | |
| Well-defined margin | 72 | 60 | 4.0357 | >0.05 |
| Acoustic attenuation | 22 | 8 | | |
| Non-acoustic attenuation | 59 | 70 | 7.4174 | <0.05 |
| Penetrating vessels | 59 | 65 | | |
| Non-vessels | 22 | 13 | 2.5489 | >0.05 |
| RI ≥ 0.7 | 38 | 41 | | |
| RI < 0.7 | 43 | 37 | 0.5075 | >0.05 |
| Microcalcification | 45 | 35 | | |
| Non- microcalcification | 36 | 43 | 1.8143 | >0.05 |

that phyllodes and acoustic attenuation had statistical differences in the comparison of benign and malignant breast lesions, but the others had no statistical differences.

The ultrasonographic finding of phyllodes, which is the most important imaging finding, is due to the multi-center growth and uneven blood supply of the tumor. The imaging findings of phyllodes in invasive lobular carcinoma are consistent with their histopathological features. Phyllode is the basic and essential diagnostic tool and can distinguish between benign and malignant tumors according to Choi *et al.* [9]. Tan *et al.*[10] also reported that ultrasonographic findings can be used to help preoperatively determine breast phyllodes tumors. The present authors found in this study that the phyllodes are more important malignant ultrasonographic findings and its accordance with Choi *et al.* and Tan *et al.*. However, Gurleyik *et al.*[11] considered that breast imaging modalities are not helpful to differentiate idiopathic granulomatous lobular mastitis from invasive cancer. In addition, some fibroadenomas have findings of phyllodes, and it is difficult to distinguish [12, 13]. So when the breast lesions have phyllodes inflammation and fibroadenoma should be excluded. Further study is required to confirm manifestations of phyllodes in inflammation and fibroadenoma to provide more detailed information for diagnosis of breast cancer.

Most of the acoustic attenuation is due to the reflection and scattering of the malignant tumors to acoustic wave, and only a small part of the attenuation is caused by absorption of acoustic wave. Attenuation of posterior echo was detected in the cases associated with hyperplasia of collagenized fibroblastic stroma, as reported by Tamaki *et al.* [14]. Posterior acoustic attenuation on ultrasonography are more frequently associated with invasive lobular carcinomas than with invasive ductal carcinomas [15]. Results from high-frequency ultrasonic measurements of human breast tissue specimens indicate that characteristics in the ultrasonic attenuation can be used to differentiate between normal, benign, and malignant breast pathologies [16, 17]. The present authors found in this study that the acoustic attenuation is also more important malignant ultrasonographic findings and its accordance with above research.

As reported, poorly-defined margin is the important malignant ultrasonographic findings diagnosing breast cancer [18] except mucinous breast cancer [19, 20]. Although the present authors found that there were no statistical differences in poorly-defined margin as shown in Table 1, it had a high $\chi^2$ value. The present negative results may be because of the lack of cases and the different pathological types of beast cancer; it therefore requires further study.

It is important that the present research found that the malignant ultrasonographic findings are not unique for breast cancer [21]. However, because the benign lesions also have the same ultrasonographic findings, the breast lesions were usually over-diagnosed. The present authors analyzed 81 cases of benign breast lesions diagnosed BI-RADS-US 4C. As shown in Figure 1, the eight malignant ultrasonographic findings appeared on benign breast lesions and have no difference with Figure 2. Benign possibilities should be taken into account when irregular shape, indistinct boundary, penetrating or tortuous surrounding vessels, RI≥0.7, and microcalcification are found.

The authors found in this study that phyllodes and acoustic attenuation are the important malignant ultrasonographic findings in diagnosing breast cancer. The diagnostic value of poorly-defined margin needs further study.

**Acknowledgements**

Yinyan Li is greatly indebted to all my teachers who have helped me directly and indirectly in my studies. Any progress that I have made is the result of their profound concern and selfless devotion. Among them the following require mentioning: Professor Xuemei Wang.

**References**

[1] Olopade O.I., Grushko T.A., Nanda R., Huo D.: "Advances in breast cancer: pathways to personalized medicine". *Clin. Cancer Res.*, 2008, *14*, 7988.

[2] Burnside E.S., Sickles E.A., Bassett L.W., Rubin D.L., Lee C.H., Ikeda D.M., *et al.*: "The ACR BI-RADS experience: learning from history". *J. Am. Coll. Radiol.*, 2009, *6*, 851.

[3] Ojeda-Fournier H., Nguyen J.Q.: "How to improve your breast cancer program: standardized reporting using the new American College of Radiology Breast Imaging-Reporting and Data System". *Indian J. Radiol. Imaging*, 2009, *19*, 266.

[4] Kelly K.M., Dean J., Lee S.J., Comulada W.S.: "Breast cancer detection: radiologists' performance using mammography with and without automated whole-breast ultrasound". *Eur. Radiol.*, 2010, *20*, 2557.

[5] Moon H.J., Kim M.J., Kwak J.Y., Yoon J.H., Kim S.J., Sohn Y.M., *et al.*: "Malignant lesions initially categorized as probably benign breast lesions: retrospective review of ultrasonographic, clinical and pathologic characteristics". *Ultrasound Med. Biol.*, 2010, *36*, 551.
[6] Moon H.J., Kim M.J., Kwak J.Y., Kim E.K.: "Prob-ably benign breast lesions on ultrasonography: a retrospective review of ultrasonographic features and clinical factors affecting the BI-RADS categorization". *Acta Radiol.*, 2010, *51*, 375.
[7] Zahl P.H., Mæhlen J.: "Overdiagnosis of breast cancer after 14 years of mammography screening". *Tidsskr. Nor. Laegeforen.*, 2012, *132*, 414.
[8] Raza S., Chikarmane S.A., Neilsen S.S., Zorn L.M., Birdwell R.L.: "BI-RADS 3, 4, and 5 lesions: value of US in management—follow-up and outcome". *Radiology*, 2008, *248*, 773.
[9] Choi B.B., Kim S.H., Shu K.S.: "Lobular lesions of the breast: imaging findings of lobular neoplasia and invasivelobular carcinoma". *J. Reprod. Med.*, 2012, *57*, 26.
[10] Tan H., Zhang S., Liu H., Peng W., Li R., Gu Y., *et al.*: "Imaging findings in phyllodes tumors of the breast". *Eur. J. Radiol.*, 2012, *81*, e62.
[11] Gurleyik G., Aktekin A., Aker F., Karagulle H., Saglamc A.: "Medical and surgical treatment of idiopathic granulomatous lobular mastitis: a benign inflammatory disease mimicking invasive carcinoma". *J. Breast Cancer,* 2012, *15*, 119.
[12] Adamietz B.R., Kahmann L., Fasching P.A., Schulz-Wendtland R., Uder M., Beckmann M.W., *et al.*: "Differentiation between phyllodes tumor and fibroadenoma using real-time elastography". *Ultraschall Med.*, 2011, *32*, E75.
[13] Gatta G., Iaselli F., Parlato V., Di Grezia G., Grassi R., Rotondo A.: "Differential diagnosis between fibroadenoma, giant fibroadenoma and phyllodes tumour: sonographic features and core needle biopsy". *Radiol. Med.*, 2011, *116*, 905.
[14] Tamaki K., Sasano H., Ishida T., Ishida K., Miyashita M., Takeda M., *et al.*: The correlation between ultrasonographic findings and pathologic features in breast disorders". *Jpn. J. Clin. Oncol.*, 2010, *40*, 905.
[15] Kim S.H., Cha E.S., Park C.S., Kang B.J., Whang I.Y., Lee A.W., *et al.*: "Imaging features of invasive lobular carcinoma: comparison with invasive ductal carcinoma". *Jpn. J. Radiol.*, 2011, *29*, 475.
[16] Doyle T.E., Factor R.E., Ellefson C.L., Sorensen K.M., Ambrose B.J., Goodrich J.B., *et al.*: "High-frequency ultrasound for intraoperative margin assessments in breast conservation surgery: a feasibility study". *BMC Cancer*, 2011, *11*, 444.
[17] Kanaev C.V., Novikov S.N., Semiglazov V.F., Krivorot'ko P.V., Zhukova L.A., Krzhivitskiĭ P.I.: "Early diagnosis of breast cancer with scintimammography and ultrasound". *Vopr. Onkol.*, 2011, *57*, 622.
[18] Wang X., Xu P., Wang Y., Grant E.G.: "Contrast-enhanced ultrasonographic findings of different histopathologic types of breast cancer". *Acta Radiol.*, 2011, *52*, 248.
[19] Memis A., Ozdemir N., Parildar M., Ustun E.E., Erhan Y.: "Mucinous (colloid) breast cancer: mammographic and US features with histologic correlation". *Eur. J. Radiol.*, 2000, *35*, 39.
[20] Bode M.K., Rissanen T.: "Imaging findings and accuracy of core needle biopsy in mucinous carcinoma of the breast". *Acta Radiol.*, 2011, *52*, 128.
[21] Bode M.K., Rissanen T., Apaja-Sarkkinen M.: "Ultrasonography and core needle biopsy in the differential diagnosis of fibroadenoma and tumor phyllodes". *Acta Radiol.*, 2007, *4*, 708.

Address reprint requests to:
X.M. WANG, PhD
Department of Ultrasound diagnosis,
The First Affiliated Hospital of
China Medical University,
Shenyang 110001 (China)
e-mail: cnjinfeng@126.com