

Leiomyosarcoma of the broad ligament: a case report with CT and MRI images

N. Makihara¹, T. Maeda², Y. Ebina¹, K. Kitajima², F. Kawakami³, S. Hara³, H. Yamada¹

¹Department of Obstetrics and Gynecology, Kobe University Graduate School of Medicine, Kobe

²Department of Radiology, Kobe University Graduate School of Medicine, Kobe

³Department of Diagnostic Pathology, Kobe University Graduate School of Medicine, Kobe (Japan)

Summary

Primary leiomyosarcoma of the broad ligament is a very rare and highly malignant gynecological tumor. The authors report a 61-year-old postmenopausal woman with signs and symptoms of malignant ovarian tumor. Preoperative magnetic resonance imaging (MRI) was interpreted as being suspicious for malignant tumors, such as an ovarian cancer or a leiomyosarcoma of the broad ligament, so laparotomy was performed. Macroscopically, the tumor was revealed with a 18×13.7×9.5 cm degenerated, multiple cystic part and solid whitish part arising from broad ligament which on histopathology proved to be leiomyosarcoma. To the best of the authors' knowledge, primary leiomyosarcoma of the broad ligament has been documented in 21 reports or so, and no imaging findings are available. Here the authors present the MRI findings of primary leiomyosarcoma of the broad ligament.

Key words: Leiomyosarcoma; Broad ligament; Pelvic tumor; MRI.

Introduction

Primary leiomyosarcoma of the broad ligament is a very rare and highly malignant gynecological tumor.

To the best of the authors' knowledge, primary leiomyosarcoma of the broad ligament satisfying the strict criteria provided by Gardner *et al.*, has been documented in 21 cases [1-3]. Imaging findings are not available in any of these reports [4]. Here the authors present the magnetic resonance imaging (MRI) findings of primary leiomyosarcoma of the broad ligament.

Case Report

A 61-year-old, gravid 2 para 2 postmenopausal woman with a sense of abdominal fullness presented to the present hospital under suspicion of an ovarian carcinoma. She had no significant gynecological or past medical history. The lower abdomen was distended with a firm and immobile mass. The serum CA-125, CA19-9, and CEA levels were within the normal limits; however, the serum LDH level was 233 IU/l (reference level, 115~217 IU/l). Ultrasonography documented a 14.5 cm diameter solid mass filling the pelvis. Contrast-enhanced computed tomography (CT) of the abdomen also suggested the presence of a 11.2×15.6 cm mass in the pelvis (Figure 1), which was enhanced heterogeneously. The liver and lungs were normal and there was no para-aortic or iliac lymphadenopathy. MRI of the pelvis was performed. T2-weighted scan demonstrated a mass beside the right uterine wall with cystic and solid components containing hemorrhage or necrosis (Figure 2a). The right ovary and uterus were identified as normal and separate from the mass (Figure 2b), and flow voids were seen within the pedicle of the tumor. Dynamic contrast-enhanced MRI of the pelvis showed that with the exception of the necrotic components, the mass was enhanced in the early phase (Figures 2c 1-2-3). Since the authors could not

rule out a malignant tumor, such as ovarian cancer or leiomyosarcoma of the broad ligament, based on these radiologic findings, the patient was admitted to this institute to undergo surgical resection. After a complete workup, laparotomy was performed, which revealed a large, lobulated, firm mass in the lower abdomen, and pelvis. The mass was adherent to the right broad ligament and the right fallopian tube. So, the mass was resected en bloc with the right uterine appendages.

Macroscopically, the tumor was white, multinodular, solid, measuring 18×13.7×9.5 cm. Cut surface showed solid whitish tissue and multiple small cystic spaces with central degenerated yellowish area. Foci of hemorrhage and necrosis were seen. The right ovary and fallopian tube were found to be normal and completely independent of the mass. Microscopically, the tumor was composed of malignant spindle cells characterized by high mitotic activity and nuclear pleomorphism (Figures 3a, 3b). Subsequent immunohistological examination showed diffuse positivity for alpha-smooth muscle actin (α -SMA) and desmin (Figure 3c). The histological and immunohistochemical profiles of this tumor matched a diagnosis of leiomyosarcoma. Because there was no relationship between the tumor and ovary, fallopian tube, and uterus, the primary site of the tumor was estimated as broad ligament. After providing detailed patient counseling, total abdominal hysterectomy with left salpingo-oophorectomy (TAH-LSO) was recommended. TAH-LSO and histological examination of the internal genitalia did not show any signs of disease dissemination. In the view of the localized leiomyosarcoma of the broad ligament, adjuvant postoperative combination chemotherapy was not given.

The woman developed lung and pelvic lymph node metastasis six months after undergoing the second operation, so combination chemotherapy (gemcitabine; 900 mg/m² on days 1 and 8, and docetaxel; 100 mg/m² on day 8) was administered [5].

Discussion

Primary leiomyosarcoma of the broad ligament of the uterus is a rare neoplasm. Gardner *et al.* proposed the definition of tumors of the broad ligament, requiring that they

Revised manuscript accepted for publication June 24, 2013

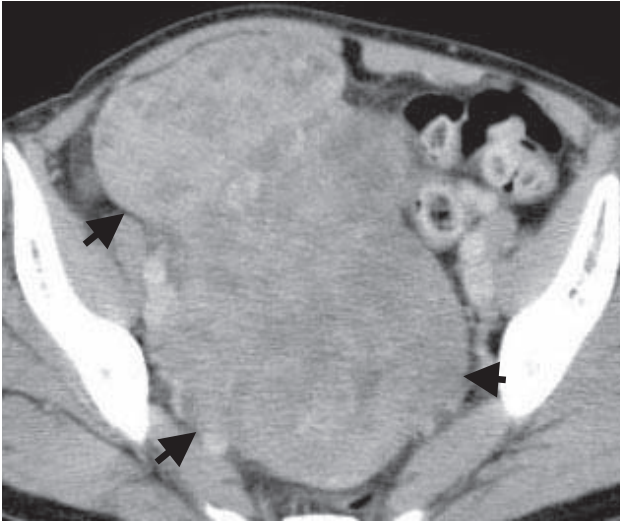

Figure 1. — Contrast-enhanced axial CT of the pelvis. Contrast-enhanced axial computed tomography scan of the pelvis demonstrates the mass (arrows), which is enhanced heterogeneously.

“occur in or on the broad ligament, but are completely separated from and in no way connected with either the uterus and the ovary”[6]. According to this definition, only 21 cases have been reported in the English literature [1-3].

Primary leiomyosarcoma of the broad ligament of the uterus is characterized by the presence of no symptoms, i.e., abdominal pain, abdominal distention, constipation, pollakiuria, urine retention, and anorexia, and is characterized by the absence of specific symptoms [7]. However, many patients with broad ligament cancer display a lack of symptoms and are most often diagnosed with advanced stage at initial presentation and treatment. So, the clinical aspect of broad ligament tumors is similar to that of the ovarian and uterine tumors. Optimal management of leiomyosarcomas of the broad ligament is controversial. In most cases, the same management as in leiomyosarcoma of the uterus is followed [8].

No cases have been diagnosed correctly before surgery, and there have been few descriptions of their appearances

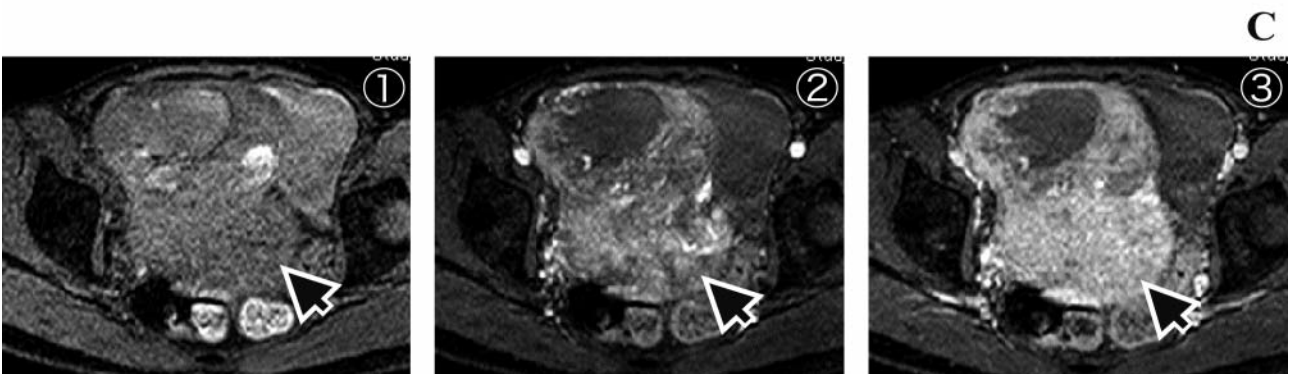
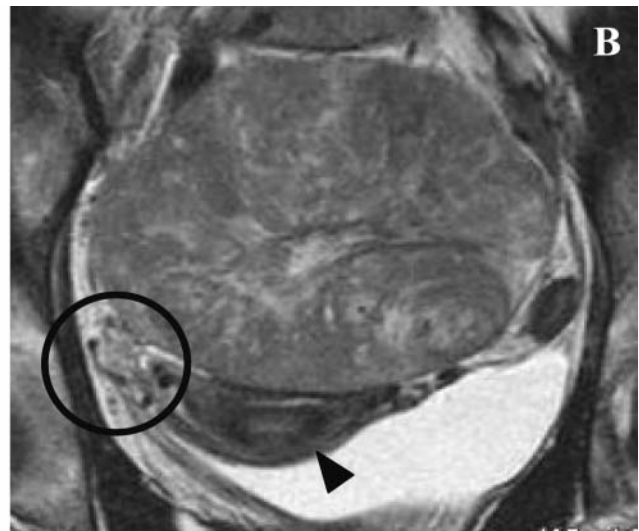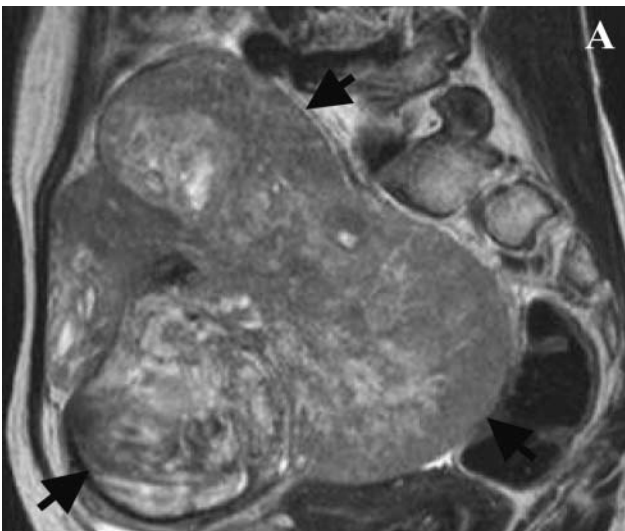


Figure 2. — MRI of the pelvis.

2a: Sagittal T2 weighted MRI demonstrates a mass (arrows) beside the right uterine wall with cystic and solid component.

2b: Note that the right ovary (circle) and uterus (arrowhead) are normal.

2c: Dynamic contrast-enhanced MRI (1: preintra-venous gadolinium, 2: early phase, 3: delayed phase).

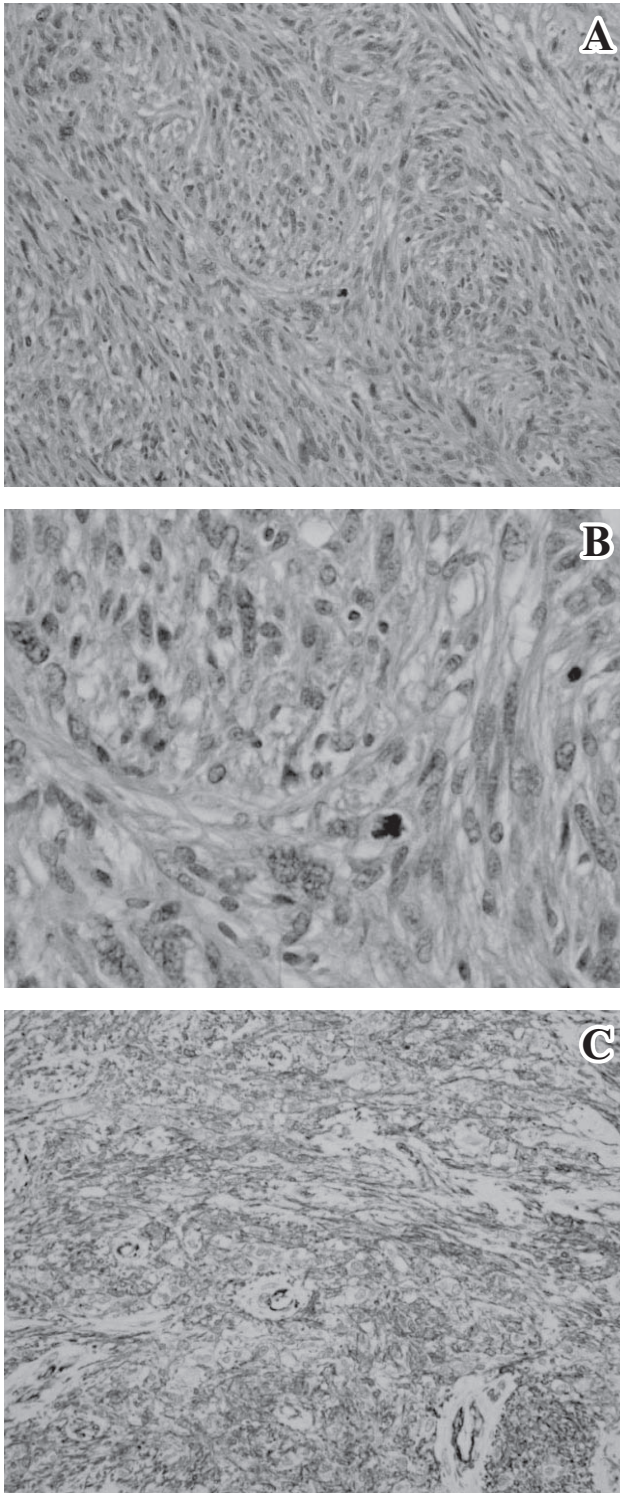


Figure 3. — Histology and immunohistochemistry of leiomyosarcoma.

3a: The tumor consisted of pleomorphic spindle cells showing fasciculation. (HE, S $\times 100$) mitosis and pleomorphism.

3b: Tumor cells showed marked nuclear pleomorphism. Abnormal mitotic figures were prominent (HE, S $\times 400$).

3c: Tumor cells showed diffuse positivity for α -SMA staining of smooth muscle myosin antibodies ($\times 400$).

on imaging studies. Under such circumstances, preoperative characterization of the tumor is judged as fundamental when planning surgery for pelvic tumors. MRI is important through cartographic studies of tumor and it seems to be capable of identifying the anatomic relationship with adjacent viscera and determining resectability [9]. In the presented case, a normal uterus and normal ovary could be identified on MRI. The major differential diagnose of leiomyosarcoma of the broad ligament, include gynecological, urological and gastro-intestinal tumors, and lymphoma and metastatic tumors [10]. When experiencing a case of a pelvic tumor of unknown origin, it must be considered to make differential diagnosis of tumors derived from the broad ligament.

Conclusion

The authors have experienced a case of primary leiomyosarcoma of the broad ligament representing as ovarian carcinoma. Malignant tumor that occurs in the broad ligament is rare, and the incidence of leiomyosarcoma is very low among them. Preoperative diagnosis of leiomyosarcoma of the broad ligament is so difficult that more sophisticated diagnostic imaging tools and accumulation of clinical cases, including treatment and prognosis, are needed.

Acknowledgement

The authors would like to acknowledge Dr. Kazuhiro Kitayama, Yoshiya Miyahara, Ritsuko Yamamoto, and Moe Yamashita for their support and assistance for this paper.

References

- [1] Kolusari A., Ugurluer G., Kosem M., Kurdoglu M., Yildizhan R., Adali E.: "Leiomyosarcoma of the broadligament: a case report and review of the literature". *Eur. J. Gynaecol. Oncol.*, 2009, 30, 332-4.
- [2] Clarke B.A., Rahimi K., Chetty R.: "Leiomyosarcoma of the broad ligament with osteoclast-like giant cells and rhabdoid cells". *Int. J. Gynecol. Pathol.*, 2010, 29, 432.
- [3] Bousfina N., Saadi H., Erraray S.: "Leiomyosarcoma of the broad ligament: a case report and the review of the literature". *Anatol. J. Obstet. Gynecol.*, 2011, 2, 2.
- [4] Menn K.A., Qin L., Fedoriv G.D., Gillette M.E., McCarthy S.: "Uterus-Like Mass: MRI appearance of a very rare entity". *J. Magn. Reson. Imaging*, 2007, 26, 162.
- [5] Hensley M.L., Blessing J.A., Mannel R., Rose P.G.: "Fixed-dose rate gemcitabine plus docetaxel as Wrst-line therapy for metastatic uterine leiomyosarcoma: a Gynecologic Oncology Group phase II trial". *Gynecol. Oncol.*, 2008, 109, 329.
- [6] Gardner G.H., Greene R.R., Peckham R.: "Tumors of the broadligament". *Am. J. Obstet. Gynecol.*, 1957, 73, 536.
- [7] Cheng W.F., Lin H.H., Chen C.K., Chang D.Y., Huang S.C.: "Leiomyosarcoma of the broad ligament: a case report and literature review". *Gynecol. Oncol.*, 1995, 56, 85.

- [8] Berchuck A., Rubin SC., Hoskins WJ., Saigo PE., Pierce VK., Lewis JL Jr.: "Treatment of uterine leiomyosarcoma". *Obstet. Gynecol.*, 1988, 71, 845.
- [9] Ben Amara F., Jouini H., Nasr M., Malek M., Neji K., Rezig H. *et al.*: "Primary leiomyosarcoma of broad ligament". *Tunis Med.*, 2007, 85, 591.
- [10] Sapillane A.J., Thomas J.M.: "Gynaecological presentation of retroperitoneal tumours". *BJOG*, 2000, 107, 170.

Address reprint requests to:
N. MAKIHARA, M.D., Ph.D.
Department of Obstetrics and Gynecology,
Kobe University Graduate School of Medicine
7-5-2, Kusunoki-cho, Chuo-ku,
Kobe, Hyogo, 6500017 (Japan)
e-mail: mm8548@med.kobe-u.ac.jp