

## REVIEW

# Management of nodal disease in advanced-stage ovarian cancer: porta hepatis, celiac, pelvic and paraaortic lymphadenectomy

Cagatay Taskiran<sup>1,\*</sup> , Burak Giray<sup>1</sup> , Dogan Vatansever<sup>1</sup> , Orhan Bilge<sup>2</sup>

<sup>1</sup>Division of Gynecologic Oncology, Department of Obstetrics and Gynecology, Koc University School of Medicine, 34010 Istanbul, Turkey  
<sup>2</sup>Department of General Surgery, Koc University School of Medicine, 34010 Istanbul, Turkey

**\*Correspondence**

cagataytaskiran@yahoo.com  
(Cagatay Taskiran)

**Abstract**

Maximal cytoreduction is considered the most important prognostic factor for ovarian cancer survival. Most ovarian cancer patients are diagnosed at an advanced stage, and more than half of them have upper abdominal involvement. Upper abdominal regions alongside the pelvis should be evaluated systematically as a routine procedure during cytoreductive surgery. Therefore, aggressive procedures are adopted during cytoreductive surgery, including upper abdominal regions, to achieve maximal cytoreduction. It should include the exploration of porta hepatis and celiac lymph nodes. The feasibility of metastatic disease resection at the porta hepatis and celiac lymph nodes has been demonstrated in many studies with acceptable morbidity. Furthermore, ovarian cancer often leads to retroperitoneal lymph nodes metastases in patients with advanced stages of the disease. Data from the literature showed that more than half of the advanced-stage ovarian cancer patients had lymph node involvement. In this manuscript, we reviewed the current literature and aimed to investigate the impact on survival of surgical resection of porta hepatis, celiac regions, and pelvic/paraaortic lymph nodes in patients with advanced-stage ovarian cancer. Resection of metastatic disease at the porta hepatis/cealic lymph nodes to achieve maximal cytoreduction is feasible but with a relatively high rate of morbidity and mortality. Randomized controlled trials indicate that in the absence of suspicious lymph nodes, both during surgery and at imaging, systematic lymphadenectomy seems to provide no survival benefit.

**Keywords**

Celiac lymph node; Isolated lymph node metastasis; Lymphadenectomy; Ovarian cancer; Porta hepatis

## 1. Introduction

Epithelial ovarian cancer (EOC) is a major reason for gynecologic cancer-related death in women worldwide [1]. Nearly three-quarters of new cases are diagnosed at advanced-stage [2]. The standard treatment of ovarian cancer is maximal cytoreductive surgery followed by chemotherapy. The aim of the surgical treatment of ovarian cancer is to achieve maximal cytoreduction, and residual disease after surgery is considered the most significant prognostic factor for survival [3, 4]. The current literature reported that maximal cytoreductive surgery was associated with improved survival in both newly diagnosed and recurrent ovarian cancer patients [3–5].

Since most ovarian cancer patients are diagnosed at an advanced stage, more than 60% of them have upper abdominal involvement [6]. Upper abdominal regions alongside pelvis should be evaluated systematically as a routine procedure during surgery due to the peritoneal spread of ovarian cancer. The excision of upper abdominal metastases increases the rate of complete cytoreduction from 50% to 76% [7]. These pro-

cedures may include liver metastasectomy, cholecystectomy, splenectomy, distal pancreatectomy, gastrectomy, diaphragmatic peritonectomy, celiac lymph node excision, and tumor excision at porta hepatis. The feasibility of upper abdominal disease resection has been demonstrated with acceptable morbidities in advanced-stage ovarian cancer patients [8].

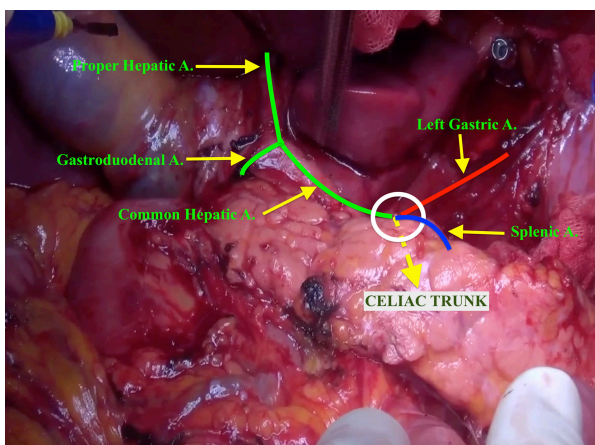
Lymph nodes status is an important prognostic factor in patients with ovarian cancer. Systematic pelvic and paraaortic lymphadenectomy is a major component of the surgical staging procedure in apparent stage I disease. On the contrary, in advanced stages, retrospective studies have indicated an improved survival in patients who underwent systematic lymphadenectomy; randomized controlled studies reported no better outcomes [9–12]. Recently, differently from previous studies, the LION study, which was a well-designed randomized controlled trial, did not report any survival advantage for systematic lymphadenectomy in patients without bulky lymphadenopathy [12]. It is obvious that to achieve maximal cytoreduction, the bulky disease should be resected.

There are limited studies that focused on survival of celiac

and portal surgery. Furthermore, in the absence of suspicious or bulky lymph nodes, the benefit of systematic lymphadenectomy on survival is controversial. The purpose of this study is to investigate the impact on survival of surgical resection of porta hepatis and celiac regions and to summarize the literature on pelvic/paraaortic lymphadenectomy in patients with advanced-stage ovarian cancer.

## 2. Management of Disease at Porta Hepatis and Celiac Lymph Nodes

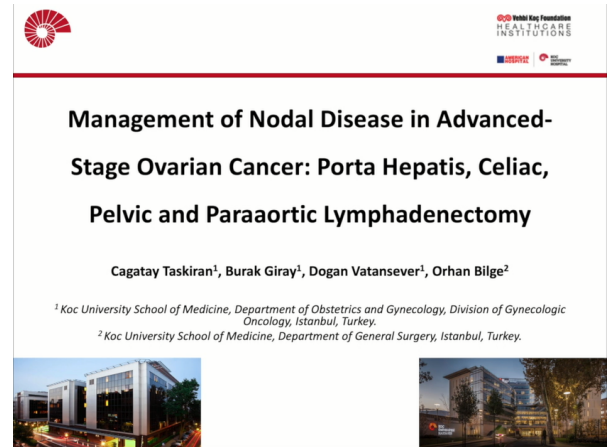
The upper abdominal region should be evaluated systematically in all patients with advanced-stage ovarian cancer to achieve complete cytoreduction. It should include the exploration of the lesser sac, porta hepatis, celiac lymph nodes, and retrohepatic vena cava. The porta hepatis consists of three important structures, including the common bile duct, portal vein, and proper hepatic artery. These anatomical structures are located in the order of the duct, artery, and vein, from anterior to posterior. The disease at the porta hepatis may present with peritoneal and/or lymph node metastases. The celiac artery arises from the anterior surface of the aorta, and divides into three large branches: splenic artery, left gastric artery, and hepatic arteries (Fig. 1). The celiac lymph nodes are associated with the branches of the celiac artery. As a part of upper abdominal surgery, dissection of the porta hepatis and celiac lymph nodes, is particularly important to achieve maximal cytoreduction (Video 1).



**FIGURE 1.** Celiac trunk branches.

The published literature reported that radical resection of upper abdominal disease is feasible, and patients who underwent upper abdominal surgical procedures, including the porta hepatis, had acceptable morbidity and potential for improved overall survival (OS) [8, 13–15] (Table 1, Ref. [14–20]). Song *et al.* [16] retrospectively evaluated 155 advanced-stage ovarian cancer patients, and they reported the necessity of tumor resection from porta hepatis in 11 (7.1%) patients. Portal resection was performed in 2 patients at primary cytoreduction (1.9%) and 9 patients (16.7%) at secondary cytoreduction. In their series, the rate of involvement of the porta hepatis in recurrent ovarian cancer patients was higher than in newly diagnosed ovarian cancer patients.

Martinez *et al.* [17] in 2011 conducted a study including



**VIDEO 1.** Porta hepatis, celiac, pelvic and paraaortic lymphadenectomy. The embedded movie may also be viewed at <https://oss.ejgo.net/files/article/1536952170332471296/video/Video1-encode.mp4>.

28 patients who had disease at porta hepatis or celiac lymph nodes. They achieved complete cytoreduction in all except one woman. Perioperative complication directly related to celiac or portal surgery was identified in only 1 of 28 patients (lateral common bile duct injury) [17]. In their series, grade 3–5 morbidity occurred in 10 of 28 patients (35.7%) (bowel complications in 4 patients, reoperation for abdominal hemorrhage in 2 patients, intraabdominal abscess in 1 patient, pneumonia requiring intubation in 1 patient, congestive heart failure in 1 patient, dead of septic complications in 1 patient). They indicated that resection of suspicious lymph nodes and metastatic disease from porta hepatis is feasible with an acceptable morbidity rate.

Raspagliesi *et al.* [15] in 2013 carried out a systematic investigation on the upper abdomen region. They reported that involvement of the omental bursa was found in 25 (67%), and metastatic peritoneal spread at porta hepatis was found 4 (10.8%) out of 37 patients [15]. They achieved optimal debulking in all patients (34 cases with no visible disease, and 3 cases with residual tumor <5 mm) with grade-1 intraoperative complications in 2 cases (1 liver hemorrhage and 1 left gastric artery injury), grade-2 early postoperative complications in 2 cases (ileus), and grade-3 early postoperative complication in 1 case (gastric herniation in the thorax). The authors also underlined if there is no adhesion occluding the Winslow foramen in patients with upper abdominal disease; omental bursa, the surface of the pancreas, lesser omentum, and caudate lobe are invaded by disease.

In a study conducted on 216 patients with stage IIIC–IV EOC who underwent primary or interval cytoreduction, 31 of 216 patients (14.3%) had tumor at the porta hepatis and/or hepato-celiac lymph nodes [18]. The authors found that the incidence of macroscopic porta hepatis and/or hepato-celiac lymph node disease was similar between the primary cytoreduction group and interval cytoreduction group (16.9% and 11.8%, respectively,  $p = 0.34$ ). Maximal cytoreduction was achieved in 28 of 31 patients (90.3%) with no complication, and they reported that median progression-free survival (PFS) was 19 months, and median OS was 42 months.

**TABLE 1. Main characteristics of the studies investigating the porta hepatis and celiac lymph node resection in advanced-stage ovarian cancer patients.**

Author, year	No. patients	Operation	PH and/or CLN resection	Complete resection of PH/CLN	Reported pathological disease	Morbidity*	Mortality	Pathological/ clinical features as-associated with PH/CLN involvement	Prognostic outcome of the patients
		(n)	n (%)	n	n (%)	n (%)	n (%)		
Martinez <i>et al.</i> , 2011 [17]	28	Primary (20)	28 (100)	27/28	15/26 (57.7) with CLN involvement	10 (35.7) (Grade 3–5)	1 (3.6)	Small bowel, right and/or transverse colon involve paraaortic lymph node metastasis	-
		Recurrent (8)			19/28 (67.9) with PH involvement				
		Interval (17/28)							
Song <i>et al.</i> , 2011 [16]	155	Primary (2)	Primary 2/101 (1.9)	11/11	11 (100)	4 (14.3) (Grade 1–2)	0 (0)	-	5/11 recurrent disease (median 8 months)
		Recurrent (9)	Recurrent 9/54 (16.7)						
Raspagliesi <i>et al.</i> , 2013 [15]	37	-	9 (24.3)	9/9	9 (100)	5 (13.5) (Grade 1–3)	0 (0)	Macroscopic involvement of the diaphragm, no adhesions occluding the Winslow foramen	-
Tozzi <i>et al.</i> , 2016 [18]	216	Primary (18)	31 (14.4)	28/31	30 (96.8)	63 (29.2) (Grade 1–5)	1 (0.5)	-	Median PFS: 19 months
		Interval (13)							Median OS: 42 months
Gallotta <i>et al.</i> , 2017 [19]	566	Primary (78)	85 (15)	73/85	45 (52.9)	58 (10.2) (Grade 1–5)	3 (0.5)	Metastatic paraaortic and mesenteric lymph nodes, peritoneal disease at omental bursa	Median PFS: 16 months
		Interval (7)							Median OS: 43 months

**TABLE 1. Continued.**

Author, year	No. patients	Operation (n)	PH and/or CLN resection n (%)	Complete resection of PH/CLN n	Reported pathological disease n (%)	Morbidity* n (%)	Mortality n (%)	Pathological/ clinical features as-associated with PH/CLN involvement	Prognostic outcome of the patients
Angeles <i>et al.</i> , 2019 [20]	150	Primary (18) Interval (25)	43 (28.7)	43/43	17 (39.5)	13 (30.2) (Grade 3–5)	-	Higher PCI/SCS scores, large bowel resection, left diaphragm stripping, paraaortic lymph node involvement, ascites	Median PFS: 11 months Median OS: 32 months
Donato <i>et al.</i> , 2021 [14]	320	Primary (41) Interval (26)	Hepatobiliary disease: 67 (20.9) PH and/or CLN disease: 12 (3.8)	48/67	-	7 (10.4) (Grade 3–5)	2 (2.9)	-	Median PFS: 19 months Median OS: 45 months (in patients without residual disease)

CLN, celiac lymph node; OS, overall survival; PCI, peritoneal cancer index PFS, disease-free survival; PH, porta hepatis; SCS, Surgical Complexity Score of Aletti.

\*Clavien-Dindo classification.

In 2017, Gallotta *et al.* [19] performed hepato-celiac lymph node resection in 85 (15%) of 566 patients who underwent primary ( $n = 78$ ) or interval ( $n = 7$ ) cytoreductive surgery and reported hepato-celiac lymph node metastasis in 45 (52.9%) of the 85 patients. Additionally, they reported that the hepato-celiac lymph node involvement was correlated with paraaortic lymph node involvement ( $p = 0.033$ ), metastatic mesenteric lymph nodes ( $p = 0.011$ ), and peritoneal disease at the omental bursa ( $p = 0.0008$ ). They achieved complete cytoreduction in 73 of 85 women. After a 36 months follow-up period, recurrence of disease occurred in 35 (41.2%) patients, and relapse of disease was higher in patients with lymph node involvement (65.7%) compared without lymph node involvement (34.3%) ( $p = 0.048$ ). According to the study results, the authors indicated that hepato-celiac lymph node surgery is feasible for patients with advanced ovarian cancer, and metastatic hepato-celiac lymph nodes are associated with worse oncologic outcomes.

In a series of 150 patients who underwent cytoreductive surgery for the frontline treatment of advanced EOC, Angeles *et al.* [20] reported an 11.3% incidence of metastatic disease at celiac lymph nodes and/or porta hepatis. In addition, they found that patients with positive celiac lymph nodes had a significantly higher peritoneal cancer index, and celiac lymph node involvement was associated with colectomy and left diaphragm stripping. The authors also reported that the median PFS in the group of patients with and without celiac lymph node involvement were 11.3 months and 25.8 months, respectively ( $p < 0.001$ ); the median OS in the group of patients with negative celiac lymph node was higher than in the group with positive celiac lymph node ( $p = 0.007$ ).

In Donato's paper, including the data of 320 patients, 67 patients (20.9%) had at least one liver, biliary, porta hepatis or celiac lymph node involvement [14]. Among these patients, 3 (0.9%) had portal vein node metastasis, 3 (0.9%) had involvement of common hepatic artery, and 6 (1.9%) had celiac lymph node metastasis. They achieved complete cytoreduction in 48 (71.6%) patients. The authors reported that the median PFS for advanced-stage ovarian cancer patients with hepatobiliary involvement was shorter than patients without hepatobiliary involvement (17 months and 19 months, respectively,  $p = 0.016$ ).

Upper abdominal surgery to achieve maximal cytoreduction have a relatively high rate of morbidity/mortality. Martinez *et al.* [17] reported the rate of grade 3–5 (Clavien–Dindo classification) complication as 35.7%. In their series, there was one death due to septic complications in the postoperative period. Raspagliesi *et al.* [15] reported one liver hemorrhage and one left gastric artery injury, 2 ileuses, and one gastric herniation in the thorax in their cohort ( $n = 37$ ). In a recent study, hepatobiloma and trans-diaphragmatic herniation related to hepatobiliary surgery were reported in 2 (2.9%) patients by Donato *et al.* [14]. In Gallotta's study, the most frequent complications were associated with hematologic/vascular and pulmonary systems in 566 patients, including 85 patients who underwent hepato-celiac lymph node resection [19]. In addition, Tozzi *et al.* [18] reported the rate of grade 1–5 complications as 29.2%. However, none of the complications was associated with the tumor resection at porta

hepatis and/or celiac lymph nodes. Song *et al.* [16] indicated that postoperative morbidities (14.3%) were as follow: ileus, adjustment disorder, acute renal failure, non-specific chest pain and the morbidities were not related to dissection of porta hepatis.

According to the literature, systematic evaluation of the porta hepatis and celiac lymph nodes should be considered as a part of cytoreductive surgery. Resection of metastatic disease to the porta hepatis and celiac lymph nodes is feasible with acceptable morbidity for patients with advanced ovarian cancer.

### 3. Pelvic and Paraaortic Lymphadenectomy

Systematic pelvic and paraaortic lymphadenectomy is a common procedure in ovarian cancer and a major component of the surgical staging procedure (Video 1). In the literature, the rate of metastatic lymph nodes ranges between 30 and 75% in advanced-stage ovarian cancer [9, 12, 21–24]. Lymphadenectomy should be performed in the presence of suspicious or bulky lymph nodes. However, in the absence of suspicious or bulky lymph nodes, the benefit of systematic lymphadenectomy on survival is controversial.

As a hypothesis, nodal metastasis may be less chemo-sensitive due to diminished blood supply, so lymphadenectomy may benefit to improve survival. The effect of systematic lymphadenectomy in patients with advanced ovarian cancer was denoted by Eoh *et al.* [9] in 2017. They showed that patients who underwent systematic lymphadenectomy had a marginally significantly improved PFS ( $p = 0.059$ ) and significantly improved OS ( $p < 0.001$ ) compared with those who underwent lymph node sampling. In the meta-analysis of 2425 patients with ovarian cancer, Wang *et al.* [25] reported significantly improved OS (Hazard ratios (HR): 0.64, 95% Confidence interval (CI): 0.49–0.84,  $p < 0.01$ ) but not PFS (HR: 0.89, 95% CI: 0.69–1.15,  $p = 0.38$ ) in patients who underwent systematic lymphadenectomy compared to those without systematic lymphadenectomy.

In 2020, 2 randomized controlled studies, including 1074 patients and 7 cohort studies comprising 3161 patients with advanced-stage EOC, were evaluated in a systematic review and meta-analysis [10]. According to the meta-analysis of randomized controlled studies and observational studies, lymphadenectomy was associated with improved OS (HR: 0.80; 95% CI: 0.70–0.90). However, results from randomized controlled studies demonstrate that lymphadenectomy was not associated with improved OS (HR: 1.02; 95% CI: 0.85–1.22). Similarly, in a population-based study, Cheng *et al.* [11] showed that lymphadenectomy did not have a significant survival benefit among 4360 patients with advanced-stage ovarian cancer (median OS: 44 months in no-lymphadenectomy group and 49 months in lymphadenectomy group,  $p = 0.055$ ). In a meta-analysis involving 1607 patients by Lin *et al.* [26], systematic lymphadenectomy in patients with ovarian cancer was not associated with longer OS (HR: 1.00; 95% CI: 0.94, 1.07;  $p = 0.90$ ) or PFS (HR: 0.97; 95% CI: 0.87, 1.08;  $p = 0.62$ ) when optimal cytoreduction was achieved. In addition, they indicated that systematic lymphadenectomy was associated



with a higher incidence of postoperative complications (RR = 1.50; 95% CI: 1.34, 1.68;  $p < 0.00001$ ) [26]. In another meta-analysis that separate randomized controlled studies and observational studies, there was no difference in PFS (HR: 0.91; 95% CI: 0.81–1.04;  $p = 0.16$ ) and OS (HR: 0.94, 95% CI: 0.88–1.00;  $p = 0.07$ ) between systematic lymphadenectomy and unsystematic lymphadenectomy in the analysis of randomized controlled studies. On the contrary, there was improved PFS (HR: 0.93, 95% CI: 0.92–0.95;  $p < 0.00001$ ) and OS (HR: 0.91, 95% CI: 0.89–0.93,  $p < 0.00001$ ) when observational studies were evaluated [24].

In the recently published randomized controlled study of LION by Harter *et al.* [12], 647 patients with no suspicious lymph node (International Federation of Gynecology and Obstetrics (FIGO) stage IIB–IV) were randomized at the end of cytoreductive surgery; 323 patients to the lymphadenectomy group, and 324 patients to the no-lymphadenectomy group. They indicated that systematic lymphadenectomy is associated with higher operation time (340 vs. 280 minutes,  $p < 0.001$ ) and blood loss (650 vs. 500 mL,  $p < 0.001$ ); and higher rate of red blood cells or fresh frozen plasma transfusion ( $p = 0.005$  and  $p = 0.07$ , respectively), and admission to the intensive care unit (77.6% vs. 69.0%,  $p = 0.01$ ). In addition, they found that serious postoperative complications (infection treated with antibiotics ( $p = 0.03$ ), symptomatic lymph cysts ( $p = 0.001$ ), repeat laparotomy ( $p = 0.01$ ), mortality within 60 days after surgery ( $p = 0.049$ ) occurred more frequently in the lymphadenectomy group. Interestingly, 55.7% of patients with radiological and clinical node-negative had microscopic lymph node metastases on pathological analysis. Nevertheless, the authors reported that the median OS was 69.2 months in the no-lymphadenectomy group and 65.5 months in the lymphadenectomy group (HR: 1.06; 95% CI: 0.83 to 1.34;  $p = 0.65$ ); and median PFS was 25.5 months in both groups (HR: 1.11; 95% CI: 0.92 to 1.34;  $p = 0.29$ ). The authors indicated that systematic lymph node dissection was not associated with longer OS or PFS [12].

National Comprehensive Cancer Network (NCCN) Guidelines Ovarian Cancer Version 3.2021 suggest that, if possible, suspicious and/or enlarged nodes identified on preoperative imaging or during surgery should be resected, and resection of clinically negative nodes is not required.

The European Society of Gynaecological Oncology (ESGO) guideline does not specify that lymphadenectomy should be definitely performed in advanced-stage ovarian cancer. According to the ESGO guideline, complete tumor resection is the most significant prognostic factor for patients with advanced stage ovarian cancer and is the main goal of surgery.

Main characteristics of the studies investigating pelvic and paraaortic lymphadenectomy in advanced-stage ovarian cancer patients are presented in Table 2 (Ref. [2, 9, 11, 12, 23, 26–30]).

#### 4. Lymphadenectomy in Interval Cytoreduction

Few studies have focused on the surgical outcomes of ovarian cancer after neoadjuvant chemotherapy. Song *et al.* [27] conducted a study including 330 patients who underwent interval debulking surgery, and they investigated the effect of lymphadenectomy between selective lymphadenectomy of suspicious nodes group ( $n = 145$ ), systematic lymphadenectomy group ( $n = 118$ ), and no-lymphadenectomy group ( $n = 67$ ).

Median PFS was 28, 30.5, and 22 months, respectively ( $p = 0.049$ ), and median OS was 50, 59, and 57 months, respectively ( $p = 0.566$ ). They observed that extent of lymphadenectomy had no significant impact on PFS or OS [27]. In 2020, Bund *et al.* [2] compared two groups: lymphadenectomy and no-lymphadenectomy during interval cytoreduction. Median OS was 26.8 months and 27.6 months in the lymphadenectomy group and no-lymphadenectomy group, respectively. Median PFS was 18.3 months in the lymphadenectomy group and 16.6 months in the no-lymphadenectomy group. The authors indicated that lymphadenectomy had a positive impact on PFS ( $p = 0.005$ ) but not on OS ( $p = 0.7$ ). They also demonstrated that the lymphadenectomy group had higher intraoperative (20.9% vs. 6.5%;  $p = 0.003$ ) and postoperative complications (26.7 vs. 12.8%;  $p = 0.001$ ). A retrospective analysis of 132 patients who underwent interval cytoreductive surgery after 6 neoadjuvant chemotherapy cycles showed that the median PFS was 8.1 (6.2–10.1) and 8.3 (5.1–11.6) months ( $p = 0.878$ ); the median OS was 56.7 (95% CI: 43.4–70.1) and 61.2 (21.4–101.0) months ( $p = 0.934$ ) in the lymphadenectomy and no-lymphadenectomy groups, respectively [23]. The authors found no influence of lymphadenectomy on survival. Seidler *et al.* [31] conducted a review in 2021 including 1094 patients who received 3–6 cycles of neoadjuvant chemotherapy. They observed that lymph node dissection was not associated with improved survival for clinically node-negative patients [31]. Similarly, in a meta-analysis of 6825 patients, AlMahdy *et al.* [32] reported that systematic lymph node dissection was not associated with improved survival in patients who received neoadjuvant chemotherapy (HR: 0.97, 95% CI: 0.73–1.29).

#### 5. Lymphadenectomy in Low Grade Serous Ovarian Cancer

In low grade serous ovarian cancer, the prognostic effect of systematic lymphadenectomy is unclear. In a study conducted on 126 patients with low-grade serous ovarian cancer by Simon *et al.* [33], 86.1% of the patients were stage III/IV, and 74.6% underwent lymphadenectomy. They found that pelvic and paraaortic lymphadenectomy had no significant impact on OS ( $p = 0.78$ ) or PFS ( $p = 0.93$ ) [33]. In a retrospective multicenter study of 191 women with low grade serous ovarian carcinoma, lymph node dissection was performed in 155 (81.2%) patients. After a median follow-up of 44 months, the authors reported that lymph node status did not affect recurrence-free survival or OS in their cohort ( $p = 0.672$  and  $p = 0.628$ , respectively) [34]. In a series of 381 patients with rare histologic subtypes of advanced-stage ovarian cancer, including clear cell, endometrioid, mucinous, and low-grade serous carcinoma, Nasioudis *et al.* [35] indicated that systematic lymphadenectomy was not associated with a survival benefit ( $p = 0.42$ ). Similarly, Kajiyama *et al.* [36] in 2020 reported that systematic lymphadenectomy did not have a significant improvement in the oncologic outcome of advanced-stage clear-cell carcinoma

**TABLE 2. Main characteristics of the studies investigating pelvic and paraaortic lymphadenectomy in advanced-stage ovarian cancer patients.**

Author, year	Type of study	Type of operation (n)	Patient number	Complications	Recurrence rate	PFS (months)	OS (months)
Ferrero <i>et al.</i> , 2014 [28]	Retrospective	Recurrence (73)	-	Renal vein injury (n = 1)	43 (58.9%)	46 (post-recurrence)	64% (5 years)
Eoh <i>et al.</i> , 2017 [9]	Retrospective	Primary (158)	LA (n = 96) No LA (n = 62)	-	54.8% (no LA group) 58.3% (LA group) ( $p = 0.665$ )	No significant difference ( $p = 0.059$ )	Longer in LA group ( $p < 0.001$ )
Song <i>et al.</i> , 2019 [27]	Retrospective	Interval (330)	LA (n = 118) Selective LA (n = 145) No LA (n = 67)	No significant among the three ( $p = 0.72$ )	-	No significant difference ( $p = 0.049$ )	No significant difference ( $p = 0.566$ )
Hollis <i>et al.</i> , 2019 [29]	Retrospective	Recurrence (98)	Isolated lymph node relapse (n = 49) Extranodal relapse (n = 49)	-	-	-	72.9 (ILNR group), 41.1 (ENR group) ( $p = 473$ )
Harter <i>et al.</i> , 2019 [12]	Randomized controlled	Primary (647)	LA (n = 323) No LA (n = 324)	Repeat laparotomy (12.4%, LA group; 6.5%, no-LA group) ( $p = 0.01$ ), Mortality (60 days) (3.1% LA group and 0.9% no-LA group) ( $p = 0.049$ )	-	25.5 months in both groups ( $p = 0.29$ )	65.5 (LA group), 69.2 (no LA group) ( $p = 0.65$ )
Lin <i>et al.</i> , 2020 [26]	Meta-analysis of randomized controlled studies	Primary (1299) Interval (308)	LA (n = 808) No LA (n = 799)	LA group: 42.6%, No LA group: 28.8% ( $p < 0.00001$ )	-	No significant difference ( $p = 0.62$ )	No significant difference ( $p = 0.90$ )

**TABLE 2. Continued.**

Author, year	Type of study	Type of operation (n)	Patient number	Complications	Recurrence rate	PFS (months)	OS (months)
Cheng <i>et al.</i> , 2020 [11]	Retrospective	Primary & interval	LA (n = 2253)	-	-	-	49 (LA group), 44 (no LA group) ( $p = 0.055$ )
			No LA (n = 1854)				
Levy <i>et al.</i> , 2020 [30]	Retrospective	Recurrence (135)	Intraperitoneal recurrence (n = 66)	-			93.07 (RR group), 47.9 (IR group), and 41.7 (CSR group) ( $p < 0.001$ )
			Retroperitoneal recurrence (n = 30)				
			Combined site recurrence (n = 39)				
Bund <i>et al.</i> , 2020 [2]	Retrospective	Interval (255)	LA (n = 155)	LA group: 26.2%, No LA group: 14.7% ( $p = 0.15$ )	LA group: 44.5%, No LA group: 58% ( $p > 0.05$ )	18.3 (LA group), 16.6 (no-LA group) ( $p = 0.48$ )	26.8 (LA group), 27.6 (no-LA group) ( $p = 0.73$ )
			No LA (n = 100)				
Lopes <i>et al.</i> , 2021 [23]	Retrospective	Interval (60)	LA (n = 39)	LA group: 7.5%, No LA group: 9.5% ( $p = 0.800$ )	LA group: 89.7%, No LA group: 90.5% ( $p = 0.408$ )	8.1 (LA group), 8.3 (no-LA group) ( $p = 0.878$ )	56.7 (LA group), 61.2 (no-LA group) ( $p = 0.934$ )
			No LA (n = 21)				

CSR, Combined site recurrence; ENR, Extranodal relapse; ILNR, Isolated lymph node relapse; IR, Intraperitoneal recurrence; LA, Lymphadenectomy; OS, Overall survival; PFS, Disease-free survival; RR, Retroperitoneal recurrence.



in patients with optimal cytoreduction (the 5-year OS rates were 64.9 and 58.8% in patients with and without systematic lymphadenectomy groups, respectively ( $p = 0.453$ )).

## 6. Management of Isolated Lymph Node Recurrence

The isolated lymph node recurrence is rare and ranges between 1 and 6% [28, 29, 37]. In the literature, several studies have reported that isolated lymph node relapses were associated with a relatively good prognosis [28, 29, 38]. Hollis *et al.* [29] in 2019 reported that patients with isolated lymph node relapse demonstrated significantly prolonged post-relapse survival (32 months; range, 23.3–53.3 months) and OS (72.9 months; range, 62.2–96.5 months) rather than extranodal relapse (post-relapse survival: 14.9 months; range, 12.9–23.7 months) (OS: 41.1 months; range, 30–58.8 months). Secondary cytoreductive surgery for isolated nodal recurrence is feasible with acceptable morbidity [28, 29, 38]. In a series of 73 patients, Ferrero *et al.* [28] reported that nodal recurrence was paraaortic in 37 (50.7%) patients, pelvic in 21 (28.8%), pelvic and paraaortic in 9 (12.3%), pelvic and inguinal in 3 (4.1%), and inguinal in 3 women (4.1%). They achieved complete macroscopic resection of lymph node recurrence in all patients except one. The only major complication during surgery was one case of renal vein injury that required nephrectomy, and 5-year survival was 64%. Similarly, after a median follow up of 45.8 months, Levy *et al.* [30] found that OS and post-relapse survival were significantly higher in the retroperitoneal recurrence group than the intraperitoneal/combined site recurrence groups (OS—93.07, 47.9, and 41.7 months, respectively,  $p < 0.001$ , PRS—68.57, 29.67, and 19.7 months, respectively,  $p < 0.001$ ).

## 7. Conclusions

Residual disease after surgery is considered the most important prognostic factor for survival in patients with advanced ovarian cancer. Therefore, maximal cytoreduction with no visible disease should be achieved in both newly diagnosed and recurrent ovarian cancer patients. Systematic evaluation of all abdominal regions, including porta hepatis and celiac lymph nodes, should be performed as a part of cytoreductive surgery due to the possibility of metastatic involvement.

However, systematic pelvic and paraaortic lymphadenectomy in advanced-stage ovarian cancer patients seems to provide no survival benefit. Randomized controlled trials indicate that systematic lymphadenectomy, in the absence of suspicious lymph nodes, should not be performed to avoid possible complications.

## AUTHOR CONTRIBUTIONS

CT—conceptualization, literature search, supervision, manuscript editing, approval of the final draft. BG—literature search, manuscript preparation, manuscript editing. DV—literature search, manuscript preparation, manuscript editing. OB—conceptualization, literature search, supervision, manuscript editing, approval of the final draft.

## ETHICS APPROVAL AND CONSENT TO PARTICIPATE

Not applicable.

## ACKNOWLEDGMENT

Thanks to all the peer reviewers for their opinions and suggestions.

## FUNDING

This research received no external funding.

## CONFLICT OF INTEREST

The authors declare no conflict of interest.

## REFERENCES

- [1] Eoh KJ, Yoon JW, Lee I, Lee J, Kim S, Kim SW, *et al.* The efficacy of systematic lymph node dissection in advanced epithelial ovarian cancer during interval debulking surgery performed after neoadjuvant chemotherapy. *Journal of Surgical Oncology*. 2017; 116: 329–336.
- [2] Bund V, Lecointre L, Velten M, Ouldamer L, Bendifallah S, Koskas M, *et al.* Impact of lymphadenectomy on survival of patients with serous advanced ovarian cancer after neoadjuvant chemotherapy: a French national multicenter study (FRANCOGYN). *Journal of Clinical Medicine*. 2020; 9: 2427.
- [3] Aletti GD, Dowdy SC, Gostout BS, Jones MB, Stanhope CR, Wilson TO, *et al.* Aggressive Surgical Effort and Improved Survival in Advanced-Stage Ovarian Cancer. *Obstetrics & Gynecology*. 2006; 107: 77–85.
- [4] du Bois A, Reuss A, Pujade-Lauraine E, Harter P, Ray-Coquard I, Pfisterer J. Role of surgical outcome as prognostic factor in advanced epithelial ovarian cancer: a combined exploratory analysis of 3 prospectively randomized phase 3 multicenter trials: by the Arbeitsgemeinschaft Gynaekologische Onkologie Studiengruppe Ovarialkarzinom (AGO-OVAR) and the Groupe d'Investigateurs Nationaux Pour les Etudes des Cancers de l'Ovaire (GINECO). *Cancer*. 2009; 115: 1234–1244.
- [5] Harter P, Schouli J, Vergote I, Ferron G, Reuss A, Meier W, *et al.* Randomized Trial of Cytoreductive Surgery for Relapsed Ovarian Cancer. *New England Journal of Medicine*. 2021; 385: 2123–2131.
- [6] Eisenkop SM, Spirtos NM, Friedman RL, Lin WM, Pisani AL, Peticucci S. Relative influences of tumor volume before surgery and the cytoreductive outcome on survival for patients with advanced ovarian cancer: a prospective study. *Gynecologic Oncology*. 2003; 90: 390–396.
- [7] Chi DS, Franklin CC, Levine DA, Akselrod F, Sabbatini P, Jarnagin WR, *et al.* Improved optimal cytoreduction rates for stages IIIC and IV epithelial ovarian, fallopian tube, and primary peritoneal cancer: a change in surgical approach. *Gynecologic Oncology*. 2004; 94: 650–654.
- [8] Son J, Chang S. Cholecystectomy, porta hepatis stripping, and omental bursectomy. *Gland Surgery*. 2021; 10: 1230–1234.
- [9] Eoh KJ, Lee J, Yoon JW, Ji Nam E, Kim S, Kim S, *et al.* Role of systematic lymphadenectomy as part of primary debulking surgery for optimally cytoreduced advanced ovarian cancer: Reappraisal in the era of radical surgery. *Oncotarget*. 2017; 8: 37807–37816.
- [10] Chiyoda T, Sakurai M, Satoh T, *et al.* Lymphadenectomy for primary ovarian cancer: a systematic review and meta-analysis. *Journal of Gynecologic Oncology*. 2020; 31: e67.
- [11] Cheng A, Lang J. Survival analysis of lymph node resection in ovarian cancer: a population-based study. *Frontiers in Oncology*. 2020; 10: 355.
- [12] Harter P, Schouli J, Lorusso D, Reuss A, Vergote I, Marth C, *et al.* A Randomized Trial of Lymphadenectomy in Patients with Advanced Ovarian Neoplasms. *New England Journal of Medicine*. 2019; 380: 822–832.

- [13] Son J, Chang S, Ryu H. Porta hepatis debulking procedures as part of primary cytoreductive surgery for advanced ovarian cancer. *Gynecologic Oncology*. 2017; 146: 672–673.
- [14] Di Donato V, Giannini A, D’Oria O, Schiavi MC, Di Pinto A, Fischetti M, *et al*. Hepatobiliary Disease Resection in Patients with Advanced Epithelial Ovarian Cancer: Prognostic Role and Optimal Cytoreduction. *Annals of Surgical Oncology*. 2021; 28: 222–230.
- [15] Raspagliesi F, Ditto A, Martinelli F, Haeusler E, Lorusso D. Advanced ovarian cancer: Omental bursa, lesser omentum, celiac, portal and triad nodes spread as cause of inaccurate evaluation of residual tumor. *Gynecologic Oncology*. 2013; 129: 92–96.
- [16] Song YJ, Lim MC, Kang S, Seo S, Kim SH, Han S, *et al*. Extended cytoreduction of tumor at the porta hepatis by an interdisciplinary team approach in patients with epithelial ovarian cancer. *Gynecologic Oncology*. 2011; 121: 253–257.
- [17] Martinez A, Pomel C, Mery E, Querleu D, Gladiëff L, Ferron G. Celiac lymph node resection and porta hepatis disease resection in advanced or recurrent epithelial ovarian, fallopian tube, and primary peritoneal cancer. *Gynecologic Oncology*. 2011; 121: 258–263.
- [18] Tozzi R, Traill Z, Garruto Campanile R, Ferrari F, Soleymani Majd H, Nieuwstad J, *et al*. Porta hepatis peritonectomy and hepato–celiac lymphadenectomy in patients with stage IIIC–IV ovarian cancer: Diagnostic pathway, surgical technique and outcomes. *Gynecologic Oncology*. 2016; 143: 35–39.
- [19] Gallotta V, Ferrandina G, Vizzielli G, Conte C, Lucidi A, Costantini B, *et al*. Hepatoceliac Lymph Node Involvement in Advanced Ovarian Cancer Patients: Prognostic Role and Clinical Considerations. *Annals of Surgical Oncology*. 2017; 24: 3413–3421.
- [20] Angeles MA, Ferron G, Cabarrou B, Balague G, Martínez-Gómez C, Gladiëff L, *et al*. Prognostic impact of celiac lymph node involvement in patients after frontline treatment for advanced ovarian cancer. *European Journal of Surgical Oncology*. 2019; 45: 1410–1416.
- [21] Bakır MS, Birge Ö, Karadag C, Doğan S, Tuncer HA, Simsek T. The insolvable problem; survival effect of lymphadenectomy in advanced stage ovarian cancer. *Ginekologia Polska*. 2021; 92: 829–836.
- [22] Zhou J, Zhang W, Zhang Q, He Z, Sun J, Chen Q, *et al*. The effect of lymphadenectomy in advanced ovarian cancer according to residual tumor status: a population-based study. *International Journal of Surgery*. 2018; 52: 11–15.
- [23] Lopes A, Genta ML, da Costa Miranda V, Aranha A, Lopez RVM, Piatto DSAM, *et al*. Role of systematic pelvic and para-aortic lymphadenectomy in delayed debulking surgery after six neoadjuvant chemotherapy cycles for high-grade serous ovarian carcinoma. *The Journal of Obstetrics and Gynaecology Research*. 2021; 47: 2737–2744.
- [24] Xu D, Xue J, Rozan R, Li L. The role systematic lymphadenectomy plays in determining the survival outcome for advanced ovarian cancer patients: a meta-analysis. *Annals of Palliative Medicine*. 2020; 9: 912–920.
- [25] Wang Y, Ren F, Song Z, Wang X, Zhang C, Ouyang L. Prognostic significance of systematic lymphadenectomy in patients with optimally debulked advanced ovarian cancer: a meta-analysis. *Frontiers in Oncology*. 2020; 10: 86.
- [26] Lin Q, Liu W, Xu S, Li J, Tong J. The value of systematic lymphadenectomy during debulking surgery in the treatment of ovarian cancer: a meta-analysis of randomized controlled trials. *Journal of Ovarian Research*. 2020; 13: 56.
- [27] Song N, Gao Y. Therapeutic value of selective lymphadenectomy in interval debulking surgery for stage IIIC and IV epithelial ovarian cancer. *International Journal of Gynecologic Cancer*. 2019; 29: 761–767.
- [28] Ferrero A, Ditto A, Giorda G, Gadducci A, Greggi S, Daniele A, *et al*. Secondary cytoreductive surgery for isolated lymph node recurrence of epithelial ovarian cancer: a multicenter study. *European Journal of Surgical Oncology*. 2014; 40: 891–898.
- [29] Hollis RL, Carmichael J, Meynert AM, Churchman M, Hallas-Potts A, Rye T, *et al*. Clinical and molecular characterization of ovarian carcinoma displaying isolated lymph node relapse. *American Journal of Obstetrics and Gynecology*. 2019; 221: 245.e1–245.e15.
- [30] Levy T, Migdan Z, Aleohin N, Ben-Shem, Peled O, Tal O, *et al*. Retroperitoneal lymph node recurrence of epithelial ovarian cancer: Prognostic factors and treatment outcome. *Gynecologic Oncology*. 2020; 157: 392–397.
- [31] Seidler S, Koual M, Achen G, Bentivegna E, Fournier L, Delanoy N, *et al*. Clinical Impact of Lymphadenectomy after Neoadjuvant Chemotherapy in Advanced Epithelial Ovarian Cancer: A Review of Available Data. *Journal of Clinical Medicine*. 2021; 10: 334.
- [32] AlMahdy AM, Ellassall GM, Abdelbadee AY, Abd-Elkariem AY, Atef F, Ahmed IA, *et al*. Prognostic value of systematic lymphadenectomy in patients with ovarian cancer: A systematic review and meta-analysis. *European Journal of Obstetrics, Gynecology, and Reproductive Biology*. 2021; 267: 179–185.
- [33] Simon V, Ngo C, Pujade-Lauraine E, Ferron G, Pomel C, Leblanc E, *et al*. Should we Abandon Systematic Pelvic and Paraaortic Lymphadenectomy in Low-Grade Serous Ovarian Cancer? *Annals of Surgical Oncology*. 2020; 27: 3882–3890.
- [34] Vatansever D, Taskiran C, Mutlu Meydanli M, Gungorduk K, Akbayir O, Yalcin I, *et al*. Impact of cytoreductive surgery on survival of patients with low-grade serous ovarian carcinoma: a multicentric study of Turkish Society of Gynecologic Oncology (TRSGO-OvCa-001). *Journal of Surgical Oncology*. 2021; 123: 1801–1810.
- [35] Nasioudis D, Latif NA, Haggerty AF, Giuntoli II RL, Kim SH, Ko EM. Outcomes of comprehensive lymphadenectomy for patients with advanced stage ovarian carcinoma and rare histologic sub-types. *International Journal of Gynecologic Cancer*. 2021; 31: 1132–1136.
- [36] Kajiyama H, Suzuki S, Yoshikawa N, Tamauchi S, Shibata K, Kikkawa F. The impact of systematic retroperitoneal lymphadenectomy on long-term oncologic outcome of women with advanced ovarian clear-cell carcinoma. *Journal of Gynecologic Oncology*. 2020; 31: e47.
- [37] Delangle R, Rossard L, Cirier J, Delvallée J, Bendifallah S, Touboul C, *et al*. Isolated lymph node recurrence in epithelial ovarian cancer: Recurrence with better prognosis? *European Journal of Obstetrics & Gynecology and Reproductive Biology*. 2020; 249: 64–69.
- [38] Blanchard P, Plantade A, Pagès C, Afchain P, Louvet C, Tournigand C, *et al*. Isolated lymph node relapse of epithelial ovarian carcinoma: Outcomes and prognostic factors. *Gynecologic Oncology*. 2007; 104: 41–45.

**How to cite this article:** Taskiran C, Giray B, Vatansever D, Bilge O. Management of nodal disease in advanced-stage ovarian cancer: porta hepatis, celiac, pelvic and paraaortic lymphadenectomy. *European Journal of Gynaecological Oncology*. 2022; 43(3): 36–45. doi: 10.22514/ejgo.2022.009.