

Endometrial adenocarcinoma after endometrial ablation. A case report

A. Areia, M. Branco, C. Frutuoso, C.F. de Oliveira

Gynecology Department, Coimbra University Hospital, Coimbra (Portugal)

Summary

The authors present a case of endometrial adenocarcinoma after endometrial ablation, emphasizing the importance of close surveillance of these patients, patient selection and education. Even patients with none of the risk factors for endometrial cancer or contraindications to endometrial ablation should be checked carefully.

Key words:

Introduction

Endometrial ablation is a technique for treating abnormal uterine bleeding not associated with malignancy, as an alternative to hysterectomy. Long-term outcome data after endometrial ablation are limited, and incidence of endometrial adenocarcinoma after ablation is unknown.

Case Report

A 48-year-old nuliparous female attended her gynecologist due to abnormal uterine bleeding and pelvic pain of three years duration. She had a previous history of back melanoma, surgically treated, that had been stationary for five years. There were no risk factors as obesity, hypertension, diabetes, polycystic ovarian syndrome or hyperoestrogenism.

The gynecological exam was uneventful and transvaginal ultrasound revealed a homogeneous myometrium but there was an image of an endometrial polyp. Thus, she was submitted to a hysteroscopy which revealed thick irregular endometrium with a polyp. A biopsy was taken during that procedure which revealed simple endometrial hyperplasia, typically dysfunctional. She was medicated with oral progestins for ten months without regression of either the bleeding or the pain. Afterwards, she was given a four-month therapy with luteinizing hormone releasing hormone (LHRH) analogs but no response was obtained. She was again submitted to hysteroscopy which revealed an atrophic endometrium without polyps.

Given the dysfunctional bleeding, endometrial ablation was performed using a resectoscope and a roller ball; the material was histologically examined showing a quiescent endometrial epithelium.

Routine follow-up was carried out every three months. Secondary amenorrhea was noticed three months after the ablation and transvaginal ultrasound revealed a 9 mm endometrium but an irregular myometrium.

Thirty months later the patient complained of intense pelvic pain non responsive to any therapy. Total abdominal hysterectomy and bilateral salpingo-oophorectomy (TAH+BSO) were performed.

The TAH+BSO specimen revealed intraendometrial endometrioid adenocarcinoma (Figure 1), G1, in the presence of

complex hyperplasia with atypia, and adenomyosis in the inner third of the myometrium (pT1a Nx Mx).

The patient is alive, without evidence of the disease, 21 months after the diagnosis.

Discussion

Endometrial ablation is the destruction of the functional endometrial tissue. This technique has been used since 1981 as an alternative to hysterectomy in the treatment of dysfunctional uterine bleeding non-responsive to medical treatment [1].

As a minor surgical procedure, it has several possible techniques: *1st generation* procedures using laser, resection or roller ball, and *2nd generation* procedures with cryosurgery, microwave, interstitial laser and hydrothermal-ablation [1].

The ablation procedure is considered to be reasonably safe and has a success rate of around 90% [2]. Ablation techniques may be performed on an outpatient basis, with a shorter recovery time than hysterectomy, and with less cost [2].

This safe technique has been used for at least 20 years, with the major drawbacks possibly being perforation of a hollow viscous, fluid volume overload, thermal lesions of the bowel, urinary bladder and ureters, air embolism, postoperative hemorrhage and uterine perforation [1, 2].

Even though the technique can be used in many patients in whom a hysterectomy is either contraindicated or undesired, it has some failures with peak recurrence of the clinical complaint within 12 to 24 months [1]. The known risk factors related to these recurrences are the dimensions of the uterus (more than 10 cm long), associated pathologies (polyps, myomas), dysmenorrhea and previous tubal ligation [1]. Five years after endometrial ablation, it is estimated that almost 20 to 34% of the patients need a hysterectomy [3, 4]. The major risk factors for this subsequent surgery are the existence of organic pathology (myomas, adenomyosis, and endometriosis) or the presence/persistence of pelvic pain after ablation (painful syndrome after endometrial ablation).

Revised manuscript accepted for publication January 18, 2006

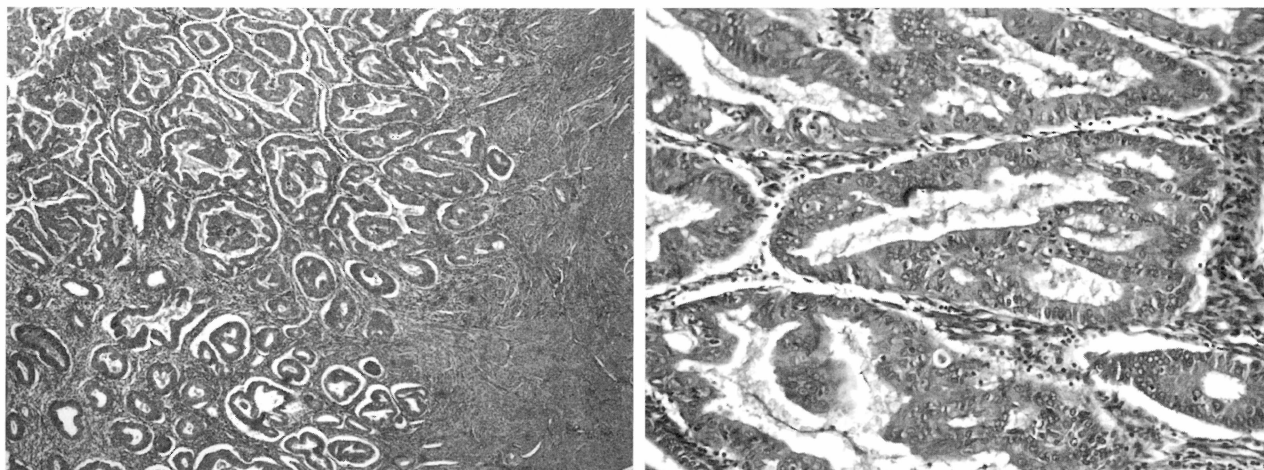


Figure 1. (a/b) – Histopathological aspects of endometrial adenocarcinoma.

Some theories try to explain the painful syndrome after endometrial ablation by the persistence of endometrial tissue, the existence of a hematometra, the existence of endometrial glands beneath scarring tissue or by the possibility of retrograde menstruation [3].

The true incidence of endometrial carcinoma after endometrial ablation is unknown [1]. So far, at least 12 cases have been reported in the world literature, some diagnosed during endometrial ablation and others afterwards [2].

Although endometrial ablation is effective in controlling bleeding, the risk of endometrial carcinoma exists if some endometrial tissue is left behind; it is also possible that a cancer already present may not be diagnosed. Additionally, the symptoms of endometrial carcinoma may not present until malignancy is well advanced [2].

In patients with adenomyosis, it is conceivable that they develop adenocarcinoma in the deep nests of adenomyosis not adequately destroyed by superficial ablation [4].

Some authors tried to extrapolate some risk factors for the occurrence of endometrial carcinoma after ablation; most of the studies pointed out that risk groups included women with diabetes, obesity, hypertension, polycystic ovary syndrome and those with persistence of endometrial hyperplasia [5]. Basically just about the same risk factors for endometrial carcinoma. For these authors, patients with these characteristics should be offered a total hysterectomy as the main treatment for dysfunctional bleeding [5]. Moreover, for endometrial ablation to be chosen, a normal endometrial biopsy must exist (or, at least, without hyperplasia) [5].

Thus, patients undergoing endometrial ablation should be regularly followed, with periodic transvaginal ultrasound and hysteroscopy examination, and with biopsy if bleeding occurs [5].

This case emphasizes the importance of close surveillance of these patients, patient selection and education. Even patients with none of the risk factors for endometrial cancer or contraindications to endometrial ablation should be carefully evaluated. Our case demonstrates that this malignancy can be totally asymptomatic and be diagnosed only incidentally.

Conclusion

The possibility of endometrial cancer developing years after endometrial ablation is real.

Even though our case had no usual risk factors, a thorough selection of patients must be done before this procedure, with careful postoperative surveillance using transvaginal ultrasound and hysteroscopy.

Prolonged follow-up is needed to ascertain the correct long-term efficacy and safety of endometrial ablation.

References

- [1] Mcgurgan P., O'Donovan: "Endometrial ablation". *Curr. Opin. Obstet. Gynecol.*, 2003, 15, 327.
- [2] Margolis M.T., Thoen L.D., Boike G.M., Mercer L.J., Keith L.G.: "Asymptomatic endometrial carcinoma after endometrial ablation". *Int. J. Obstet. Gynecol.*, 1995, 51, 255.
- [3] Unger J., Meeks G.: "Hysterectomy after endometrial ablation". *Am. J. Obstet. Gynecol.*, 1996, 175, 1432.
- [4] Comino R., Torrejon R.: "Hysterectomy after endometrial ablation-resection". *J. Am. Assoc. Gynecol. Laparosc.*, 2004, 11, 495.
- [5] Valle R.F., Baggish M.S.: "Endometrial carcinoma after endometrial ablation: high risk factors predicting its occurrence". *Am. J. Obstet. Gynecol.*, 1998, 179, 3, 569.

Address reprint requests to:
A. AREIA, M.D.
Quinta de Voimarães, lote 15-3º DTO
3000-377 Coimbra (Portugal)