Submitted: 05 August, 2025 Accepted: 08 September, 2025 Published: 15 April, 2026 DOI:10.22514/ejgo.2026.015

ORIGINAL RESEARCH

European Journal of Gynaecological Oncology

Management of vesicovaginal fistulae following gynecologic oncology surgery: a contemporary single-center analysis of surgical outcomes and evidence-based treatment strategies

Akbar Ibrahimov[1,*]

[1] Department of Oncology, Azerbaijan Medical University, AZ1022 Baku, Azerbaijan

***Correspondence**
eibrahimov1@amu.edu.az
(Akbar Ibrahimov)

Abstract

Background: The study aimed to evaluate the clinical characteristics, management strategies, and surgical outcomes of vesicovaginal fistulae following gynecologic oncology procedures, and to provide evidence-based recommendations for optimal patient care based on contemporary literature. **Methods**: Medical records of 10 patients diagnosed with post-surgical vesicovaginal fistulae following gynecologic oncology procedures were retrospectively analyzed. Clinical findings, contributing factors, diagnostic methods, treatment approaches, and postoperative outcomes were evaluated. Conservative management with continuous Foley catheterization was initially attempted, followed by surgical repair using abdominal, vaginal, or laparoscopic techniques when conservative treatment failed. Outcomes were assessed using standardized criteria, including anatomical success, functional outcomes, and complication rates. **Results**: The study cohort included 10 patients with a mean age of 51.2 years (range 42–66 years). Primary surgical procedures included radical hysterectomy for cervical cancer (n = 6), primary cytoreductive surgery for advanced ovarian cancer (n = 3), and total laparoscopic hysterectomy for benign conditions (n = 1). Initial conservative management with continuous Foley catheterization for 6–8 weeks achieved success in only 2 patients. The remaining 8 patients required surgical intervention, with successful repair achieved in all cases using various approaches: abdominal repair (n = 5), vaginal repair using the Latzko procedure (n = 2), and laparoscopic repair (n = 1). The overall surgical success rate was high with minimal complications. The mean time from primary surgery to fistula diagnosis was 16.8 days. The postoperative hospital stay averaged 6.8 days, with a catheterization duration of 14 days. **Conclusions**: This study demonstrates that vesicovaginal fistulae following gynecologic oncology procedures can be successfully managed with excellent outcomes by experienced specialists. Conservative management shows limited success, while surgical repair achieves high success with minimal morbidity. Standardized classification and individualized surgical approach selection are essential. These findings support centralization of complex cases to specialized centers and emphasize evidence-based management for optimal outcomes.

Keywords

Vesicovaginal fistulae; Gynecologic oncology; Surgical repair; Radical hysterectomy; Minimally invasive surgery; Postoperative complications

1. Introduction

Vesicovaginal fistulae (VVF) are a devastating complication in gynecologic surgery, creating abnormal communications between the bladder and vagina. This results in continuous urinary incontinence, which profoundly impacts a patient's physical, psychological, and social well-being [1]. The epidemiology of VVF demonstrates significant geographical and socioeconomic variations. While in resource-limited countries, the majority of VVF cases result from obstetrical causes, in developed nations, iatrogenic injuries during pelvic surgery are the predominant etiology, with gynecological procedures accounting for more than half of all urological injuries [2, 3]. The incidence of VVF following gynecological procedures is a significant concern in contemporary practice. Recent systematic reviews demonstrate that hysterectomy remains the leading cause of VVF in developed countries, with the risk of bladder injury during hysterectomy for malignancy reaching as high as 0.997% [4, 5]. The risk is even higher in oncologic

This is an open access article under the CC BY 4.0 license (https://creativecommons.org/licenses/by/4.0/).
 ©2026 The Author(s). Published by MRE Press.

surgeries, ranging from 0.4% to 3.7%, due to the complexity of the procedures, which often involve extensive dissection and altered anatomical planes [6, 7]. Contemporary analyses of gynecologic oncology procedures show that radical hysterectomy presents particularly high risk, with rates as elevated to 9.4% reported in salvage surgeries after radiation therapy [8]. The pathophysiology of post-surgical VVF involves direct trauma, ischemic necrosis, electrocautery injury, or suture placement through the bladder wall [9]. The presentation can be immediate or delayed, and radiation therapy significantly increases the risk of VVF by impairing tissue healing and creating unfavorable tissue conditions [10]. Recent advances in understanding VVF pathophysiology have led to improved prevention strategies and enhanced surgical techniques [11]. The contemporary management of VVF has evolved significantly with the introduction of minimally invasive techniques and the development of standardized classification systems. Recent systematic reviews and meta-analyses demonstrate success rates of 93–96% for surgical repair when performed by experienced surgeons [2, 12]. The implementation of standardized classification systems, particularly the Goh classification, has improved treatment selection and outcome comparison across studies [13].

This study, therefore, aims to contribute to the existing literature on VVF management in the gynecologic oncology setting by analyzing our institutional experience with contemporary management strategies. We examine the clinical characteristics, treatment approaches, and surgical outcomes of VVF following gynecologic oncology procedures to provide evidence-based recommendations for optimal patient care in the modern era.

2. Materials and methods

2.1 Study design

This retrospective observational study was conducted at the Department of Oncology, Azerbaijan Medical University. This is a tertiary referral center specializing in gynecologic oncology care in the Caucasus region. The study protocol was approved by the Local Ethics Committee of the Oncological Department at Azerbaijan Medical University (Approval No. 2024/02/05–45/24), and all procedures were performed in accordance with the Declaration of Helsinki and institutional guidelines for clinical research [5]. According to the Local Ethics Committee of the Oncological Department at Azerbaijan Medical University, formal consent was not required.

2.2 Patient population and inclusion criteria

We reviewed the medical records of all patients who developed post-surgical VVF following gynecological procedures at our institution between January 2018 and December 2023. Inclusion criteria were: (1) confirmed diagnosis of VVF following gynecological surgery; (2) complete medical records, including operative reports, imaging studies, and follow-up data; (3) minimum follow-up period of 6 months; and (4) surgical procedures performed by a board-certified gynecologic oncologist at our institution. Exclusion criteria included: (1) VVF of non-surgical etiology (obstetric, radiation-induced without surgical intervention); (2) incomplete medical records or inadequate follow-up data; (3) patients with concurrent rectovaginal or ureterovaginal fistulae; and (4) patients who received primary surgical care at other institutions.

2.3 Data collection and variables

Clinical data were extracted from medical records, including patient demographics, details of the primary surgical procedure, characteristics of the fistula, diagnostic methods, treatment approaches, and outcomes. The diagnosis of VVF was established through clinical presentation, physical examination, and confirmatory imaging following contemporary diagnostic protocols [14]. All patients underwent cystoscopic examination to identify the fistulous opening and assess its relationship to the ureteral orifices. Radiological confirmation was obtained through computed tomography (CT) urography with intravenous contrast. CT cystography was performed in select cases by administering contrast material directly into the bladder via Foley catheter to better delineate the fistulous tract, following recent recommendations for optimal imaging strategies [15]. All imaging studies were interpreted by certified radiologists with expertise in abdominal imaging. The VVF were classified according to the Goh classification system, which considers fistula size, location, and complexity, as recommended by recent international guidelines [16, 17]. This standardized approach enables comparison with contemporary literature and guides treatment selection.

Initial management consisted of conservative therapy with continuous bladder drainage using an 18-French Foley catheter for 6–8 weeks, following current evidence-based protocols [18]. Patients were maintained on prophylactic antibiotics (nitrofurantoin) and anticholinergic medications (solifenacin or tolterodine) to minimize bladder spasms. Weekly follow-up visits were conducted to assess for urinary tract infections and evaluate patient tolerance of conservative therapy. Success of conservative management was defined as complete cessation of urinary leakage per vagina within 5–7 days following catheter removal.

Surgical repair was undertaken in cases where conservative management failed. The timing of surgical intervention was individualized, with most repairs performed 8–12 weeks after the initial diagnosis, consistent with contemporary recommendations [19]. Surgical approach selection was based on fistula location and size, surgeon expertise, patient anatomy, and history of prior radiation therapy, incorporating recent advances in surgical technique selection [11, 20]. Three primary surgical approaches were employed: abdominal, vaginal (Latzko procedure), and laparoscopic repair.

In select cases, during abdominal repair technique, omental interposition was employed to provide additional tissue coverage and enhance healing.

Vaginal Repair (Latzko Procedure) was performed for small, uncomplicated fistulae located at the vaginal apex. This approach was preferred for patients with limited abdominal adhesions and favorable anatomy.

The Laparoscopic Repair approach was selected for patients with favorable anatomy and surgeon expertise in advanced

laparoscopic techniques.

Outcome measures included anatomical success (defined as complete closure of the fistulous tract with no evidence of urinary leakage), functional outcomes (return to normal voiding patterns without incontinence), and complication rates.

2.4 Statistical analysis

Descriptive statistics were calculated for all variables. Continuous variables are reported as means with standard deviation or medians with interquartile ranges (IQR). Categorical variables are reported as frequencies. Due to the small sample size, inferential statistical testing was not performed, consistent with recent recommendations for small case series [2]. All analyses were performed using SPSS version 28.0 (IBM Corporation, Armonk, NY, USA). p-values were determined using Fisher's exact test for categorical variables and the Mann-Whitney U test for continuous variables, with $p < 0.05$ considered statistically significant for exploratory analyses. All data were de-identified prior to analysis to protect patient confidentiality.

3. Results

During the five-year study period, 10 patients were diagnosed with post-surgical VVF. The mean age of patients was 51.2 $\pm$ 7.8 years (range 42–66 years). The primary surgical procedures that led to VVF formation were radical hysterectomy for cervical cancer in 6 patients, primary cytoreductive surgery for advanced ovarian cancer in 3 patients, and total laparoscopic hysterectomy for benign conditions in 1 patient. The mean time to VVF recognition was 16.8 $\pm$ 8.2 days (range 8–33 days). The patient demographics and clinical characteristics are summarized in Table 1.

All fistulae were located in the supratrigonal region of the bladder. According to the Goh classification, 8 fistulae were classified as simple (Goh 1) and 2 as complex (Goh 2) due to their size being larger than 25 mm. The fistula size ranged from 5 mm to 35 mm, with a median size of 15 mm (IQR 10–25 mm) (Fig. 1).

Initial conservative management with continuous Foley catheterization was successful in 2 patients, both of whom had small fistulae (<10 mm) (Fig. 2). The remaining 8 patients required surgical repair (Fig. 3). Surgical repair was successful in all 8 patients, with a 100% anatomical success rate. The surgical approaches included abdominal repair in 5 patients, vaginal repair (Latzko procedure) in 2 patients, and laparoscopic repair in 1 patient. Omental interposition was used in 3 of the 5 abdominal repairs, following contemporary recommendations for complex cases [11, 12].

The mean postoperative hospital stay was 6.8 $\pm$ 1.2 days, and the mean catheterization duration was 14.2 $\pm$ 2.1 days. Postoperative complications were minor and included two cases of superficial wound complications and one case of mild purulent vaginal discharge. No major complications were observed. At a mean follow-up of 18.4 $\pm$ 8.7 months, all surgically treated patients remained free of fistula recurrence and reported excellent functional outcomes.

4. Discussion

This study provides a single-center experience in the management of VVF following gynecologic oncology surgery, incorporating contemporary evidence-based approaches. Our findings demonstrate that while conservative management is successful in a small subset of patients, surgical repair by experienced gynecologic oncologists achieves excellent outcomes with minimal morbidity. The surgical success rate in our series is consistent with the 93–96% success rates reported in recent systematic reviews and meta-analyses [2, 12].

The use of a standardized classification system, such as the Goh classification, is crucial for comparing outcomes across studies and has become the standard of care in contemporary practice [16, 17]. In our series, the majority of fistulae were simple (Goh 1), which may have contributed to the high success rate of surgical repair. The two complex fistulae (Goh 2) were successfully repaired with an abdominal approach, one of which included an omental interposition flap, consistent with recent recommendations for complex cases [11].

The importance of interposition flaps in the repair of complex or recurrent VVF is well-established in contemporary literature [11, 12, 20]. Recent studies have demonstrated the efficacy of various interposition materials, including omental flaps, Martius flaps, and novel synthetic materials [12, 20]. While we used omental interposition in three of our abdominal repairs, the decision to use an interposition flap should be individualized based on fistula characteristics and tissue quality. In our series, all repairs, including those without interposition, were successful, which may be attributed to the well-vascularized tissue in the majority of our patients, who had not received prior radiation therapy.

Contemporary advances in minimally invasive techniques have expanded treatment options for VVF repair. Recent studies have demonstrated excellent outcomes with laparoscopic and robotic-assisted approaches [11, 19, 20]. Our experience with one laparoscopic repair was successful, supporting the growing body of evidence for minimally invasive techniques in appropriate cases. The selection of surgical approach should be individualized based on surgeon expertise, fistula characteristics, and patient factors, as outlined in recent clinical practice guidelines [7, 16]. The timing of surgical intervention remains an important consideration in VVF management. Our approach of waiting 8–12 weeks after initial diagnosis is consistent with contemporary recommendations, allowing for tissue healing and optimization of surgical conditions [18, 19]. Recent evidence suggests that this timing optimizes success rates while minimizing complications.

Quality of life considerations are increasingly recognized as important outcomes in VVF management. Recent systematic reviews emphasize the importance of functional outcomes and patient-reported outcome measures [18]. All of our surgically treated patients reported excellent functional outcomes at follow-up, highlighting the importance of successful repair in restoring quality of life.

The limitations of this study include its retrospective design and small sample size, which preclude any definitive conclusions. However, our findings support the current evidence that surgical repair of VVF is highly successful when performed

TABLE 1. Patient demographics and clinical characteristics.

Variable	Value
Demographics (yr)	
Mean age (mean ± SD)	51.2 ± 7.8
Age range	42–66
Age distribution	
40–49	4
50–59	4
60–69	2
Primary Surgical Procedures	
Radical hysterectomy (cervical cancer)	6
- Type C1	4
- Type C2	2
Primary cytoreductive surgery (ovarian cancer)	3
Total laparoscopic hysterectomy (benign)	1
Time to VVF Diagnosis (d)	
Mean time (mean ± SD)	16.8 ± 8.2
Range	8–33
Early presentation (≤14)	5
Delayed presentation (>14)	5
Fistula location	
Supratrigonal	10
Goh classification	
Simple (Goh 1)	8
Complex (Goh 2)	2
Fistula size (mm)	
Median IQR	15 (10–25)
Range	5–35
Clinical Presentation	
Continuous painless urinary leakage	5
Complex symptom constellation*	3
Intermittent positional leakage with UTI symptoms	2

**Complex symptom constellation includes urinary leakage, abdominal distension, fatigue, subfebrile fever, and pelvic tenderness. IQR: interquartile ranges; VVF: vesicovaginal fistulae; SD: standard deviation; UTI: urinary tract infection.*

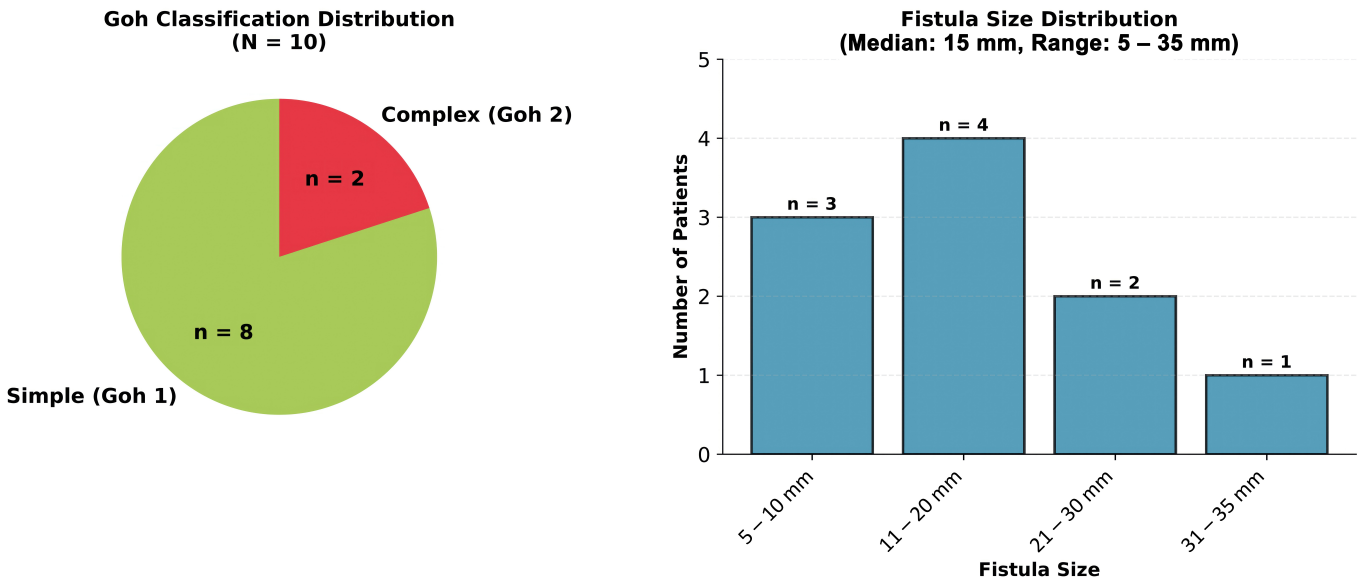

FIGURE 1. Fistula characteristics.

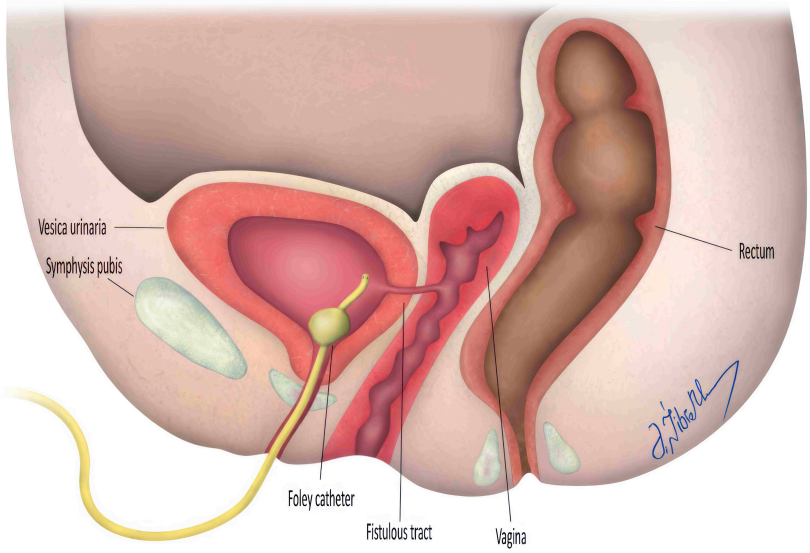

FIGURE 2. Schematic picture of vesicovaginal fistula.

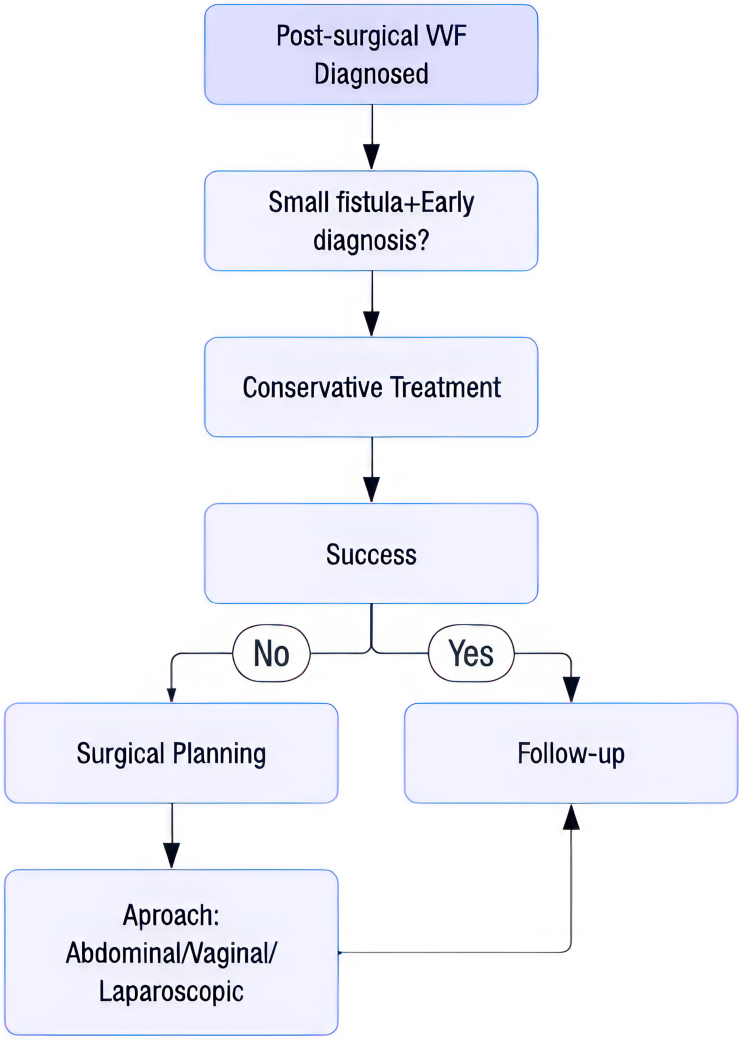

FIGURE 3. Management algorithm for vesicovaginal fistula. Clinical decision-making algorithm for the management of post-surgical vesicovaginal fistula. The flowchart demonstrates the systematic approach to treatment selection based on fistula characteristics and timing of diagnosis, emphasizing the role of conservative management in appropriate cases and the various surgical options available when conservative treatment fails. VVF: vesicovaginal fistulae.

by experienced surgeons using contemporary techniques and evidence-based approaches. Future research should focus on better defining the optimal management strategies for VVF, particularly in the context of prior radiation therapy and complex fistulae, as suggested by recent reviews [2, 12].

5. Conclusions

This institutional experience demonstrates that vesicovaginal fistulae following gynecologic oncology procedures can be successfully managed with excellent outcomes through systematic approaches by experienced specialists.

Conservative management shows limited efficacy (low success), while surgical repair by gynecologic oncologists achieves high success with minimal morbidity. Standardized classification using the Goh system is essential for treatment planning. The versatility of surgical approaches enables individualized treatment selection.

These findings support centralization of complex VVF cases to specialized centers and emphasize the importance of early recognition and prompt surgical intervention. While VVF represents a significant complication, systematic management using contemporary evidence-based protocols achieves excellent outcomes and should guide clinical practice.

AVAILABILITY OF DATA AND MATERIALS

The data supporting the findings of this study are available from the corresponding author upon reasonable request, subject to institutional review board approval and patient privacy protection requirements.

AUTHOR CONTRIBUTIONS

AI—conceptualization; data acquisition; analysis and interpretation; manuscript drafting; final approval.

ETHICS APPROVAL AND CONSENT TO PARTICIPATE

The study protocol was approved by the Local Ethics Committee of the Oncological Department at Azerbaijan Medical University (Approval No. 2024/02/05–45/24), and all procedures were performed in accordance with the Declaration of Helsinki and institutional guidelines for clinical research. According to the Local Ethics Committee of the Oncological Department at Azerbaijan Medical University, formal consent was not required.

ACKNOWLEDGMENT

The author acknowledges the dedicated nursing staff and support personnel of the Department of Oncology at Azerbaijan Medical University for their contributions to patient care and data collection. We also thank the patients who participated in this study for their cooperation and follow-up compliance.

FUNDING

This research received no external funding.

CONFLICT OF INTEREST

The author declares no conflict of interest.

REFERENCES

[1] Kumar S, Kekre NS, Gopalakrishnan G. Vesicovaginal fistula: an update. Indian Journal of Urology. 2007; 23: 187–191.

[2] Thompson JC, Halder GE, Jeppson PC, Alas A, Balgobin S, Dieter AA, *et al*. Repair of vesicovaginal fistulae: a systematic review. Obstetrics & Gynecology. 2024; 143: 229–241.

[3] Capozzi VA, Monfardini L, Scarpelli E, Barresi G, Rotondella I, De Finis A, *et al*. Urologic complication after laparoscopic hysterectomy in gynecology oncology: a single-center analysis and narrative review of the literature. Medicina. 2022; 58: 1869.

[4] Rotem R, Galvin D, Oprescu C, Hirsch A, O'Reilly BA, O'Sullivan OE. Quantifying the impact of bladder complications following gynecological cancer treatment: systematic review and meta-regression. Journal of Gynecologic Oncology. 2025; 36: e76.

[5] Iyer SM, Singh S, Srivastav A. Analysis of various surgical approaches to supratrigonal vesicovaginal fistula repair: a tertiary care centre experience. International Urogynecology Journal. 2025; 36: 1273–1279.

[6] Elliott SP, Fan Y, Jarosek S, Chu H, Downs L, Dusenbery K, *et al*. Propensity-weighted comparison of long-term risk of urinary adverse events in elderly women treated for cervical cancer. International Journal of Radiation Oncology, Biology, Physics. 2015; 92: 586–593.

[7] Arcieri M, Cuman M, Restaino S, Tius V, Cianci S, Ronsini C, *et al*. Exploring urinary tract injuries in gynecological surgery: current insights and future directions. Healthcare. 2025; 13: 1780.

[8] Huang J, Cheng Y, Wang B, Chao H, Xu X, Zeng T. Minimally invasive transvaginal single-port laparoscopic vesicovaginal fistula repair: a case report and the point of this technique. Frontiers in Surgery. 2024; 11: 1331476.

[9] Song X, Jiang C, Lv JW. Transvaginal repair of apical vesicovaginal fistula via vaginal natural orifice transluminal endoscopic surgery (V-NOTES): a modified surgical technique and its outcomes. Scientific Reports. 2024; 14: 31095.

[10] Chandna A, Mavuduru RS, Bora GS, Sharma AP, Parmar KM, Devana SK, *et al*. Robot-assisted repair of complex vesicovaginal fistulae: feasibility and outcomes. Urology. 2020; 144: 92–98.

[11] Kumar L, Kumar S, Agarwal S, Thakur A, Trivedi S. Laparoscopic vesicovaginal fistula repair using kumar's knotless technique: short-term experience from a tertiary care center. Cureus. 2025; 17: e82083.

[12] Del Biondo D, Di Domenico D, Napodano G, Grillo M, Crocetto F, Barone B. Transabdominal and transvaginal repair of vesico-vaginal fistula with bovine pericardium (Tutopatch®). A double case report. Urology Case Reports. 2025; 62: 103117.

[13] Niu S, Li Y, Tu S, Niu S, Qian J, Yang F, *et al*. Minimally invasive complete urinary tract drainage in the treatment of vesicovaginal fistula: a case report. Experimental and Therapeutic Medicine. 2022; 24: 645.

[14] Kumar N, Sureka SK, Singh UP, Kapoor R, Rustagi S, Yadav P, *et al*. Vesicovaginal fistula repair by transvaginal route: comparison of resource utilisation and outcome with literature reported population matched cohort of patients operated by minimally invasive route. The Journal of Obstetrics and Gynecology of India. 2022; 72: 414–419.

[15] El-Azab AS, Abolella HA, Farouk M. Update on vesicovaginal fistula: a systematic review. Arab Journal of Urology. 2019; 17: 61–68.

[16] Rajaian S, Pragatheeswarane M, Panda A. Vesicovaginal fistula: review and recent trends. Indian Journal of Urology. 2019; 35: 250–258.

[17] Smith AV, Cabrera R, Kondo W, Zomer MT, Ferreira H. Vesico-vaginal fistula: nature and evidence-based minimally invasive surgical treatment. Surgical Technology International. 2019; 35: 189–198.

[18] Zeleke LB, Welsh A, Abeje G, Khejahei M. Proportions and determinants of successful surgical repair of obstetric fistula in low- and middle-income countries: a systematic review and meta-analysis. PLOS ONE. 2024; 19: e0303020.

[19] Che X, Ruan M, Yang Y, Xi Z, Huang Y, Wang W, *et al*. Comparison of sterile normal saline and 1% povidone-iodine for vaginal preparation in vesicovaginal fistula: a randomised trial. Journal of Obstetrics and Gynaecology. 2025; 45: 2439356.

[20] Wei N, Pfeuti C, Linder BJ. Contemporary genitourinary fistula management: treatment, trends, and innovations. Current Opinion in Obstetrics and Gynecology. 2025; 37: 432–437.

How to cite this article: Akbar Ibrahimov. Management of vesicovaginal fistulae following gynecologic oncology surgery: a contemporary single-center analysis of surgical outcomes and evidence-based treatment strategies. European Journal of Gynaecological Oncology. 2026; 47(2): 28-34. doi: 10.22514/ejgo.2026.015.